

Pemphigus vulgaris of the larynx

Mohammed Ibrahim Eladl

ENT Resident, Shoubra General Hospital, Kitchener

Correspondence to Mohammed Ibrahim Eladl, ENT Resident, Shoubra General Hospital, Faculty of Medicine, Ain Shams University, Kitchener
e-mail: dr_moh_eladl@hotmail.com

Received 3 November 2011

Accepted 6 November 2011

The Egyptian Journal of Otolaryngology 2012, 28:74

Egypt J Otolaryngol 28:74
© 2012 The Egyptian Oto - Rhino - Laryngological Society
1012-5574

A male nonsmoker patient, 54 years old, not known to be diabetic or hypertensive, who was receiving treatment for pemphigus vulgaris in the last couple of years presented with hoarseness of voice and progressive odynophagia 3 months ago; there was no fever, and clinical and direct laryngoscopic examination revealed a large superficial epiglottic ulcer (Fig. 1).

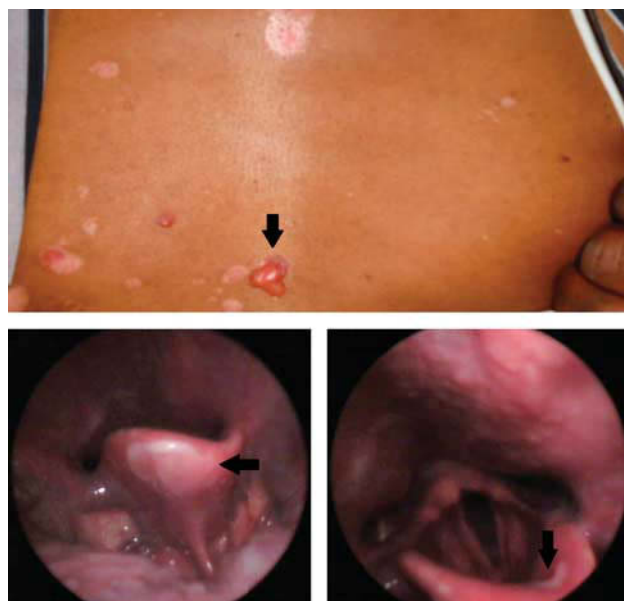
What is your diagnosis?

Acknowledgements

Conflicts of interest

There are no conflicts of interest.

Figure 1



Clinical image showing pemphigus vulgaris blisters at the frontal aspect of the chest and another one for direct laryngoscopic image showing epiglottic pemphigus vulgaris ulcer.
