

Comparison between local steroids and local steroids plus itraconazole effect in prevention of recurrence of allergic fungal sinusitis in hypertensive and/or diabetic patients

Ramez Reda^a, Wael Wageh^b, Mohammed Fawaz^a, Wassim Mikhael^b

^aDepartment of Otolaryngology, Faculty of Medicine, Beni-Suef University, Beni-Suef,
^bDepartment of Otolaryngology, Faculty of Medicine, Fayoum University, Fayoum, Egypt

Correspondence to Ramez Reda, MD,
Department of Otolaryngology, Faculty of Medicine, Beni-Suef University, Beni-Suef,
Egypt. Tel: 00201225012157, 00202/22315648;
e-mail: drramez2003@yahoo.com

Received 12 August 2018

Accepted 20 September 2018

The Egyptian Journal of Otolaryngology
2019, 35:25–29

Background

Allergic fungal rhinosinusitis (AFRS) is the most common type of fungal diseases in nose and paranasal sinuses. It is due to hypersensitivity to fungal antigens. The standard treatment for control of AFRS is endoscopic sinus surgery followed by systemic and/or topical steroids. In spite of steroids known to have promising results for the management of AFRS, their prolonged use is not always advised. So, some authors have tried to decrease the recurrence rate of AFRS by using antifungal treatment. In this study, we compared the efficacy of local steroids (Fluticasone nasal spray) versus local steroids plus itraconazole postoperatively in the prevention of recurrence of allergic fungal sinusitis in patients known to be hypertensive or diabetic.

Patients and Methods

A total of 60 patients with AFRS and nasal polyposis were included in the study. Patients were divided randomly into two groups: group A used local steroid and group B used local steroid and itraconazole. Clinical parameters were compared at the end of 6 months.

Results

Patients of group B were better clinically and also by endoscopic examination.

Conclusion

Itraconazole is better to be added in the postoperative treatment of AFRS patients especially for patients who have contraindications for systemic steroids intake.

Keywords:

allergic fungal rhinosinusitis, antifungal treatment, itraconazole

Egypt J Otolaryngol 35:25–29

© 2019 The Egyptian Journal of Otolaryngology
1012-5574

Introduction

Allergic fungal rhinosinusitis (AFRS) is the most common type of fungal diseases in nose and paranasal sinuses. At the same time, it has a high recurrence rate despite numerous strategies to prevent it [1].

AFRS is a form of polypoid chronic rhinosinusitis that is believed to be due to hypersensitivity to fungal antigens. It is characterized by type 1 hypersensitivity to fungal allergens and elevated total serum IgE [2].

The standard treatment for control of AFRS is endoscopic sinus surgery followed by systemic and/or topical steroids [3]. Although most of patients are usually improved by this treatment, recurrence was noticed in many patients even in the early postoperative period [3].

Steroids are known to be the main line of treatment for AFRS. However, their prolonged use especially systemic steroid is associated with many adverse effects. In addition, there are some patients who do not respond to this treatment [1].

So, some authors have tried to decrease the recurrence rate of AFRS by using antifungal therapy, which acts by inhibiting the fungal growth in the postoperative period with different results [1–4].

In this study, the efficacy of postoperative local steroid spray alone (Fluticasone) is compared with local steroid plus itraconazole in the prevention of recurrence of allergic fungal sinusitis in patients known to be hypertensive and/or diabetic.

Patients and methods

This prospective study was conducted in the departments of otorhinolaryngology in Beni-Suef and Fayoum universities in the period from October 2014 to October 2017. The study was approved by the ethics committee of Beni-Suef and Fayoum

This is an open access journal, and articles are distributed under the terms of the Creative Commons Attribution-NonCommercial-ShareAlike 4.0 License, which allows others to remix, tweak, and build upon the work non-commercially, as long as appropriate credit is given and the new creations are licensed under the identical terms.

universities. A written informed consent was taken from all the patients.

Sixty patients with AFRS with sinonasal polyposis were included in the study. Their ages ranged between 33 and 61 years, with a mean of 43 ± 7.3 years. Patients were known to be hypertensive and/or diabetics. Recurrent cases were excluded from the study.

Preoperative assessment included history taking, clinical examination, office-based nasal endoscopy, and routine laboratory investigations; moreover, noncontrast computed tomography (CT) on nose and paranasal sinuses was performed for all patients.

Patients were divided randomly into two groups: group A included 30 patients, and they received local intranasal steroids spray (Fluticasone) in the form of two puffs in each nostril once daily for 6 months after surgery, whereas group B included 30 patients, and they received oral itraconazole (100 mg twice daily) for 2 months plus local steroid nasal spray (Fluticasone) for 6 months after surgery. Clinical parameters were compared at the end of the sixth postoperative month.

Patients were given a course of antibiotics in the form amoxicillin-clavulanic acid 1 g twice daily and systemic antihistaminic in the form of cetirizine for 1 week before endoscopic sinus surgery to improve the condition of paranasal sinuses as a preoperative preparation.

Endoscopic sinus surgery was done for all patients. Intraoperatively, nasal swabs were taken. Cytological assessment of charcot-layden crystals, fungal hyphae, allergic mucin, eosinophils, basophil, and mast cells was done. Specimens (allergic mucin, debris, and polypi) were sent for histopathological examination.

Postoperatively, all patients received systemic antibiotic and antihistaminic for 1 week after surgery (same as preoperatively). Patients were followed up at the end of the first, second, third, and sixth postoperative month. At each visit, subjective and objective assessments were done. Subjective assessment for each symptom such as nasal obstruction, nasal discharge, headache, facial pain, nasal polypi, sneezing, itching, and hyposmia was done. Objective assessment included endoscopic examination in each visit to assess any recurrent polypi, allergic mucin, nasal discharge, mucosal edema, debris, or sinus obstruction. Moreover, CT on nose and paranasal sinuses was done at the end of the sixth postoperative month to detect any recurrence of disease. Liver enzymes were assessed in group B patients 2 months postoperatively.

Table 1 Patients' preoperative symptoms

Symptoms	Group A	Group B
Nasal obstruction	30	30
Nasal discharge	18	17
Headache or facial pain	4	6
Sneezing	19	17
Itching	15	17
Hyposmia	8	7
Snoring or mouth breathing	11	12
Associated complications (Orbital or intracranial)	0	0

Results

A total of 60 patients were enrolled in our study. In group A, 17 patients were males and 13 patients were females. Similarly in group B, 16 patients were males and 14 patients were females. Overall, 45 (75%) patients of our study population were in the age group of 33–50 years and 15 (25%) were in the age group of 51–61 years.

A total of 40 patients were suffering from disease for 1–2 years and 20 patients had a longer duration of symptoms up to 5 years. Nasal obstruction was found in all patients, nasal discharge was found in 35 patients, and headache was found in 10 patients. Patients' preoperative symptoms are summarized in Table 1.

There was no statistically significant difference between both groups regarding preoperative symptoms.

The characteristic heterogeneous opacity in CT scans was present in all patients. By CT scan, the affected sinuses were assessed. Overall, 60% of the patients had bilateral and 40% had unilateral affection. Ethmoid sinuses (anterior and posterior ethmoids) were affected in all cases (100%). Maxillary sinuses were affected in 39 (65%) patients, sphenoid sinuses in 20 (33.33%) patients, and frontal sinuses in 14 (23.33%) patients.

In nasal smear, eosinophil and allergic mucin were present in all patients. Fungal hyphae and charcot-layden crystals were found in six patients: two patients in group A and four patients in group B. All samples sent for histopathological assessment had nasal polyps with inflammation.

In group A, postoperatively all patients were clinically asymptomatic at the end of the first and the third month regarding nasal obstruction, nasal discharge, headache, facial pain, and nasal polypi. At the sixth month, five patients started to complain of nasal obstruction. In group B, all patients were clinically

asymptomatic at the end of the sixth month postoperatively.

In group A, there was no recurrence of nasal polyps at the end of the first and the third postoperative month. At the end of sixth month, five patients started to show recurrence of nasal polyps at the region of the ethmoids. In these patients, systemic steroids were given for 3 weeks under medical supervision and polyps were resolved.

In group B, two patients had mild elevation of liver enzymes at the end of second month, which was improved spontaneously after stoppage of itraconazole. All patients were symptomatically free during the whole follow-up period (6 months). This was documented by CT scan on nose and paranasal sinuses at the end of sixth postoperative month (Figs. 1 and 2).

Improvement of allergic symptoms such as sneezing and itching was noted in all patients, with no statistically significant difference between both groups.

Discussion

AFRS is a chronic disease with a very high recurrence rate [5]. Recurrence occurs despite meticulous surgical removal of polyps, allergic mucin, and diseased mucosa. The exact reason for this recurrence is vague. It may be owing to re-exposure to fungi, persistent microscopic fungi not removed during endoscopic sinus surgery (ESS), or unrecognized fungal infection [6]. There is also patient-to-patient variation in response to steroids. Some patients are well controlled with

minimal steroids, whereas others are unresponsive to high doses and/or repeated courses of prednisone and topical steroids [7].

Treatment of AFRS is conflicting. Different treatment protocols have been adopted in the past decade to overcome recurrence of this disease. It is known that steroids whether systemic and/or topical increase the cure rates of AFRS by decreasing the recurrence with reduction of mucosal stage of the disease [8].

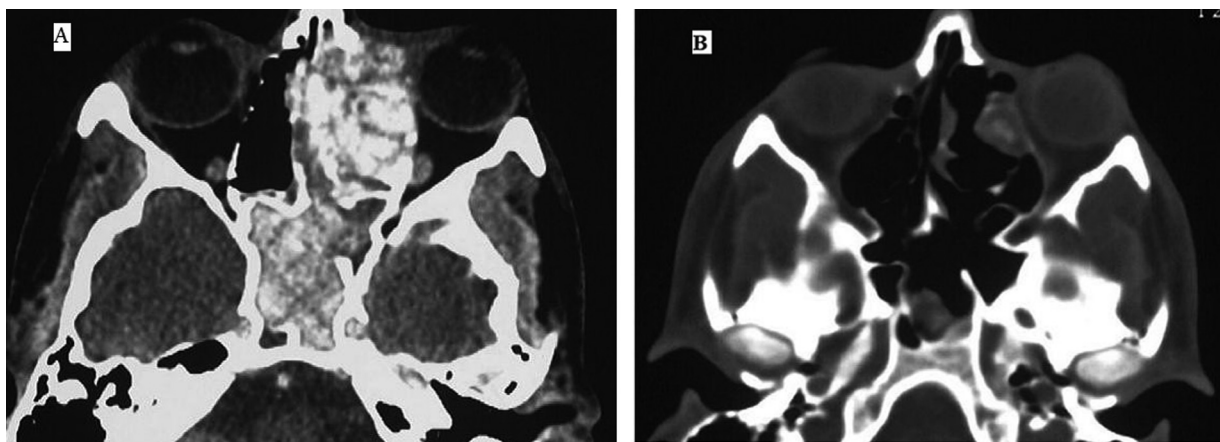
In spite of the hopeful postoperative results, a considerable proportion of the patients usually present with recurrence of disease even in the early postoperative period. This recurrence ranges from 10% to about 100% depending on the length of follow-up period [9,10].

Although prolonged use of high-dose systemic steroids is needed for the treatment of AFRS, this is not always possible in all patients because of its inevitable systemic toxicity.

Keeping in mind the etiological factor of AFRS, antifungal treatment has been tried in many patients with AFRS for better control of the disease and for less recurrence rate [1–4]. The role of antifungal treatment in the management of AFRS is still controversial, but some studies found good results with systemic use of itraconazole [10].

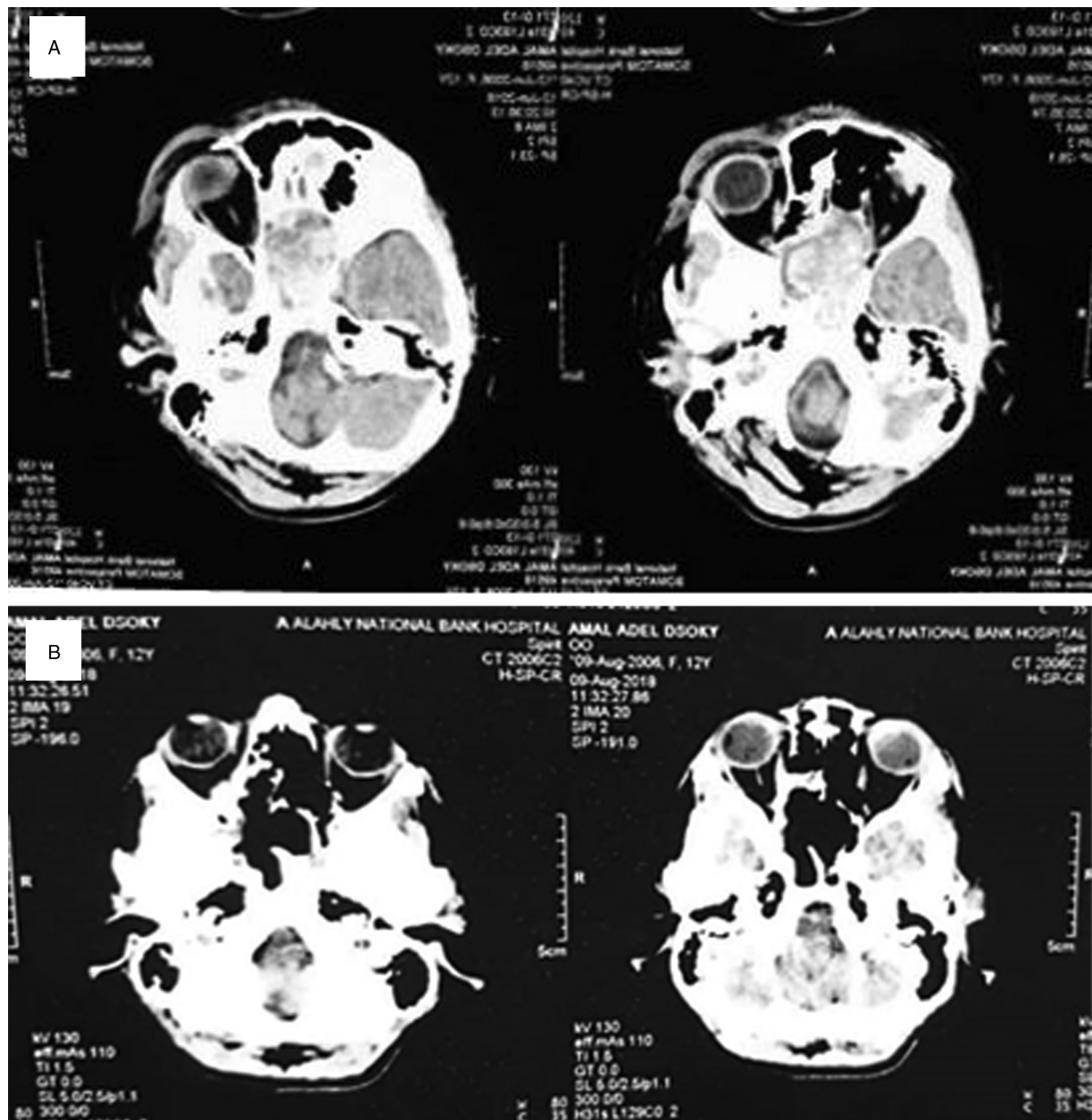
In the current study, 60 patients having AFRS with sinonasal polyposis were included. All these patients were known to be either hypertensive and/or diabetics. Recurrent cases were excluded from the study.

Figure 1



Computed tomographic scan on nose and PNS showing a case of allergic fungal rhinosinusitis affecting ethmoid and sphenoid sinuses treated by oral itraconazole for 2 months in addition to local steroid nasal spray (Fluticasone) for 6 months after surgery (a) preoperatively and (b) postoperatively. PNS, paranasal sinuses.

Figure 2



Computed tomographic scan on nose and PNS showing a case of allergic fungal rhinosinusitis affecting the sphenoid sinus mainly treated by oral itraconazole for 2 months in addition to local steroid nasal spray (Fluticasone) for 6 months after surgery (a) preoperatively and (b) postoperatively. PNS, paranasal sinuses.

Endoscopic sinus surgery was done for all patients. Intraoperatively, nasal swabs were taken. Cytological assessment was done for all patients. Specimens (allergic mucin, debris, and polypi) were sent for histopathological examination. We did not do culture and sensitivity for our patients, as many authors found that it is not conclusive, as fungi can grow as saprophytes in the affected sinus [10].

These patients were divided randomly into two groups (group A and group B). Each group included 30 patients. Patients of group A received local

intranasal steroids spray (Fluticasone) in the form of two puffs in each nostril once daily for 6 months after surgery and patients of group B received oral itraconazole (100 mg twice daily) for 2 months plus local steroid nasal spray (Fluticasone) for 6 months after surgery. Systemic steroids were not used in both groups as the patients were either hypertensive and/or diabetic.

It was found that patients treated with local steroids and itraconazole had significant improvement in the symptoms and endoscopic examination at the end of

6 months than patients treated by local steroids alone.

In group A, there was no recurrence of nasal polyps during the follow-up period. There was mild allergic mucin during the follow-up period, which was removed by suction under endoscopic vision. However, at the end of the sixth month, five patients started to show recurrence of nasal polyps at the region of the ethmoids. In these patients, systemic steroids were given for 3 weeks. In group B, there was no recurrent polypi documented by endoscopic examination nor CT scan till the sixth postoperative month.

Chan and colleagues, also found that itraconazole was effective in a good percentage of patients of AFRS who had surgery and were refractory to prednisone, intranasal steroids, and amphotericin B nasal sprays. Of 32 patients, 12 patients were improved by using itraconazole [11]. Itraconazole acts by inhibiting enzyme lanosterol 14- α -demethylase, which decreases the synthesis of ergosterol, which is a vital component of the fungal cell membrane. This reduces the fungal load in the postoperative period [4].

In this study, we have used itraconazole in small doses (100 mg twice daily) just for 2 month only. This avoids its major adverse effects especially the hepatic toxicity. So, elevation of liver enzymes was reported just in two patients of itraconazole group who were improved spontaneously after stoppage of itraconazole. Otherwise, no other complications occurred.

Other authors also recommended not to use antifungal treatment for prolonged period of time because of the derangement of liver enzymes, which may occur after its large therapeutic doses [12].

On the contrary, Rains and Mineck reported using up to 400 mg of itraconazole a day and then tapering down to 200 mg a day over 3 months without any major adverse effects. They reported only elevated liver enzymes in 4% of patients [13].

From this study, it is found that itraconazole is better to be added in the postoperative treatment of patients with AFRS, especially for patients who have contraindications for systemic steroids intake.

Acknowledgements

This work was done in the Departments of Otolaryngology in Beni-Suef and Fayoum universities, Egypt.

Financial support and sponsorship
Nil.

Conflicts of interest

There are no conflicts of interest.

References

- 1 Nikakhlagh S, Khodadadi A, Kanani M, Karampour L, Saki N. The effect of the oral itraconazole on the management of allergic fungal sinusitis. *Biomed Pharmacol J* 2015; 8:85–89.
- 2 Ryan M, Clark C. Allergic fungal rhinosinusitis and the unified airway: the role of antifungal therapy in AFRS. *Curr Allergy Asthma Rep* 2015; 15:75.
- 3 Khalil Y, Tharwat A, Abdou A, Essa E, Elsayy AH, Elnaidany NF. The role of antifungal therapy in the prevention of recurrent allergic fungal rhinosinusitis after functional endoscopic sinus surgery: a randomized controlled study. *Ear Nose Throat J* 2011; 90:E1–7.
- 4 Rojita M, Samal S, Pradhan P, Venkatachalam V. Comparison of steroid and itraconazole for prevention of recurrence in allergic fungal rhinosinusitis: a randomized controlled trial. *J Clin Diagn Res* 2017; 11: MC01–MC03.
- 5 Kuhn F, Javer A. Allergic fungal sinusitis: a four year follow up. *Am J Rhinol* 2000; 14:149–156.
- 6 Bent J, Kuhn F. Antifungal activity against allergic fungal sinusitis organisms. *Laryngoscope* 1996; 106:1331–1334.
- 7 Ferguson B. Categorization of eosinophilic chronic rhinosinusitis. *Curr Opin Otolaryngol Head Neck Surg* 2004; 12:237–242.
- 8 Kuhn F, Javer A. Allergic fungal rhinosinusitis: our experience. *Arch Otolaryngol Head Neck Surg* 1998; 124:1179–1180.
- 9 Marple B, Marby R. Allergic fungal sinusitis: learning from our failure. *Am J Rhinol* 2000; 14:223–226.
- 10 Gupta A, Shah N, Kamezwaran M, Rai D, Janakiram TN, Chopra H, *et al.* Allergic fungal rhinosinusitis. *Clin Rhinol An Int J* 2012; 5:72–86.
- 11 Chan K, Genoway K, Javer A. Effectiveness of itraconazole in the management of refractory allergic fungal rhinosinusitis. *J Otolaryngol Head Neck Surg* 2008; 37:870–874.
- 12 Shubert M, Goetz D. Evaluation and treatment of allergic fungal sinusitis. *J Allergy Clin Immunol* 1998; 102:395–402.
- 13 Rains B, Mineck C. Treatment of allergic fungal sinusitis with high dose itraconazole. *Am J Rhinol* 2003; 17:1–8.