

Hurdles in managing tracheoesophageal fistula: case report

Azliana Aziz^a, Norhafiza M. Lazim^a, Hazama Mohamad^a, Irfan Mohamad^a, Mohd R. Abdul Samad^b

^aDepartment of Otorhinolaryngology, Head and Neck Surgery, ^bDepartment of Surgery, School of Medical Sciences, Universiti Sains Malaysia, Health Campus, Kelantan, Malaysia

Correspondence to Dr Azliana Aziz, MB Bch BAO, MMed ORL-HNS, Department of Otorhinolaryngology- Head & Neck Surgery, School of Medical Sciences, Universiti Sains Malaysia, Health Campus, 16150 Kota Bharu, Kelantan, Malaysia.
e-mail: az_aziz@usm.my

Received 29 March 2018

Accepted 24 April 2019

The Egyptian Journal of Otolaryngology
2019, 35:334–337

Congenital tracheoesophageal fistula (TOF) is a rare anomaly. With the development of endoscopic techniques, the diagnosis of TOF has made marked progress. It requires surgical repair in infancy by either open or thoracoscopic approach. Diagnosing and locating the location of fistula may be difficult particularly in smaller fistula. We report three cases of TOF, to highlight the role of bronchoscopy and endoscopy and also the challenges in managing the aforementioned cases, which may present with airway embarrassment.

Keywords:

bronchoscopy, esophageal atresia, guide wire, tracheoesophageal fistula

Egypt J Otolaryngol 35:334–337

© 2019 The Egyptian Journal of Otolaryngology
1012-5574

Introduction

Tracheoesophageal fistula (TOF) is a rare congenital anomaly occurring in approximately one in 3000 live births [1] and represents ~4% of congenital abnormalities of the esophagus. Esophageal atresia (EA) with distal TOF (type C), which is a proximal esophageal pouch and distal TOF, is the most common and represents ~85% of EA anomalies [2]. Other variations include EA with a proximal TOF (5%), TOF without EA (4%), and EA with fistulas to both pouches or H-type fistula (1%).

Typical symptoms are excessive salivation and regurgitation of feeds, respiratory distress and inability to pass an orogastric tube. For H-type fistula, a patient usually chokes with feeds or has cyanotic spells [3]. They may present with recurrent pneumonia. In isolated TOF, they may also present with pneumonitis and gastric distension.

Case 1

A 1-day-old 35-week premature baby girl with birth weight of 1.79 kg was transferred from a district hospital for suspected EA with tracheal esophageal fistula. The patient was born vigorous, with APGAR score 9 at 1 min and 10 at 5 min. However, at 2 h of life, the baby was noted to be tachypneic, with intermittent nasal flaring and subcostal recession. Baby was intubated at 7 h of life because of persistent grunting, tachypnea, and persistent oral secretion. Postintubation chest radiograph noted the inserted Ryle's tube coiled (Fig. 1).

Further examination on admission revealed the child was pink, comfortable on low ventilator setting with

100% oxygen saturation, with no dysmorphic appearance. However, there was drooling of saliva. Other cardiovascular, respiratory, and gastrointestinal examinations were normal. Bedside echocardiogram finding was also normal.

Rigid bronchoscopy was done the next day. Inflamed area at the posterior wall of the trachea was seen above the carina with no obvious dimpling or secretion seen. However, there was pooling of whitish milky secretion in both main bronchus. Owing to high suspicion of TOF, the pediatric surgeon proceeded with right thoracotomy. Type C TOF was noted during the surgery. Ligation of TOF and end-to-end anastomosis of the esophagus were done.

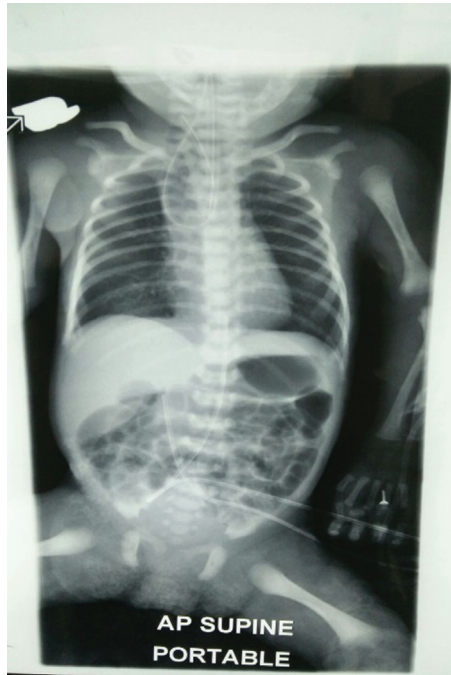After 1 week following the operation, a contrast study was done, and the result showed no leaking from the operative side. However, the baby's respiratory condition worsened. Repeat contrast study was done in several position. There were fistulous communication between the esophagus and trachea at 4–7 mm distance from the carina. However, on day 22 of life, the baby succumbed to respiratory failure secondary to bile pneumonitis from the leaking fistula repair.

Case 2

At 20 h of life, a full-term baby boy with birth weight of 2.7 kg was admitted to neonatal intensive care for

This is an open access journal, and articles are distributed under the terms of the Creative Commons Attribution-NonCommercial-ShareAlike 4.0 License, which allows others to remix, tweak, and build upon the work non-commercially, as long as appropriate credit is given and the new creations are licensed under the identical terms.

Figure 1



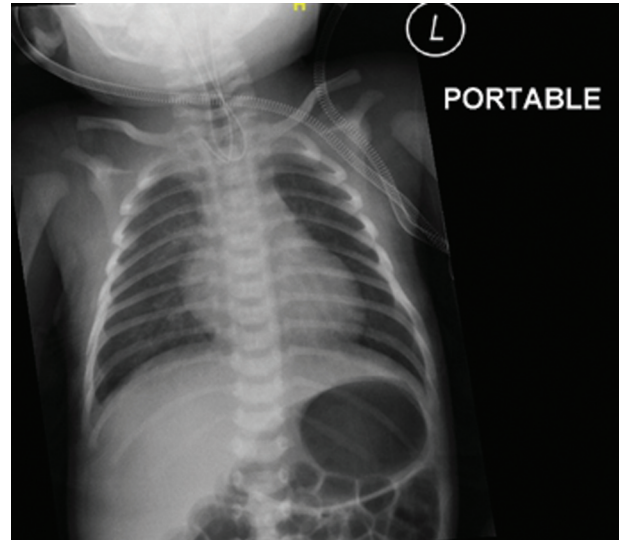
A chest and abdominal radiograph of the child with coiled Ryle's tube seen.

tachypnea and grunting. During admission, there was persistent drooling of saliva with a gurgling sound. On examination, the baby was pink but tachypneic, on nasal prong oxygen 0.5 l/min, with mild subcostal recession. No other abnormalities were detected except for hypospadias. However, during Ryle's tube insertion, the tube coiled up into the nose. Chest radiographs revealed coiled tube at upper part of the esophagus with relatively increased gas bubbles seen in stomach and bowels. In addition, bedside echocardiogram and ultrasound of the urinary system perform showed normal structures (Fig. 2).

After a review by the pediatric surgeon, the case was referred for bronchoscopy by an otolaryngologist to confirm the clinical diagnosis of TOF. Direct laryngoscopy, bronchoscopy, and telescopic examinations were performed, which showed fistula seen with presence of bubbles above the trachea. The procedure proceeded with thoracotomy and TOF repair. The baby had type C of TOF with the distance between the proximal and distal esophagus of 6 cm. He was doing well postoperatively (Fig. 3).

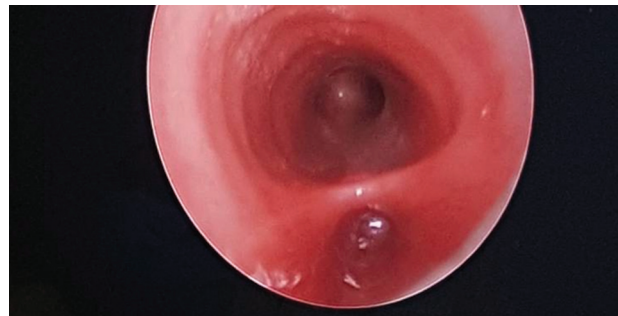Subsequently, the baby was able to tolerate extubation and weaning of oxygen. The baby was also able to tolerate feeding orally. The baby was discharged home well after 25 days following the operation and was able to tolerate full feeding.

Figure 2



Chest radiograph revealed coiled Ryle's tube.

Figure 3



Intraoperative finding (fistula seen).

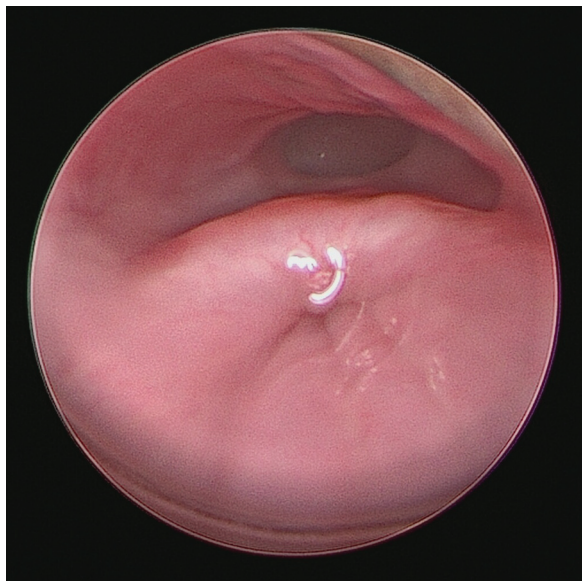Case 3

A 7-month-old boy, born at term with birth weight of 3 kg and underlying history of TOF with EA was diagnosed at day 1 of life because of difficulty to pass Ryle's tube and copious secretion from the nasal and oral cavity despite regular suction. Antenatally, his mother had history of polyhydramnios at 28 weeks of gestation. Otherwise antenatal ultrasound scan result was normal.

On day 2 of life, the baby had right thoracotomy and esophageal anastomosis, and TOF ligation was surgery done. He had no postoperative complications. Barium swallow done 1 week after operation showed features of narrowing of the anastomotic site of esophagus with no evidence of leak at the esophageal anastomotic site.

At 4 months after operation, his mother complained of regurgitation with bout of cough and vomiting especially after feeding. The baby also had

Figure 4



Endoscopic image during telescopic examination. Fistula seen at 2.5 cm from the carina.

intermittent fever with productive cough along with poor weight gain. Subsequent barium swallow at 6 months after operation show persistent TOF after repair and persistent middle esophagus narrowing.

The baby was then scheduled for direct laryngoscopy, bronchoscopy, coagulation of fistula, and insertion of the guide wire. Intraoperatively, the fistula was noted at 2.5 cm from the carina at the posterior wall of the trachea. Procedure proceeded with thoracotomy and TOF ligation. At 1 week after operation, flexible bronchoscopy was carried out while the baby was still intubated and revealed no fistula. Repeat barium swallow after 2 weeks of operation revealed no evidence of persistent TOF. After uneventful 4 months following operation, the baby was doing well and under follow-up when required (Fig. 4).

Discussion

It is estimated that the incidence of EA with or without TOF is ~1 : 2500 to 1 : 3500 live newborn [4]. Most infants with OA with TOF have proximal atresia with distal TOF. These patients are easily diagnosed after birth, compared with congenital TOF without EA, commonly referred to as H-type or N-type TOF.

TOF and EA can be detected prenatally during the routine fetal anomaly ultrasound scan, which is usually performed at 20 weeks of gestation. Features that raise suspicion of TOF or EA include a small or absent gastric bubble especially in association with polyhydramnios. After birth, the most common

presentation is variable and nonspecific, which include recurrent chest infection aspiration and choking during feeding with cyanosis and abdominal distension. H-type TOF is characterized by clinical trial of paroxysms of coughing and cyanosis precipitated by feeding, recurrent chest infection secondary to aspiration during feeding, and abdominal distension. The diagnosis is difficult and often delayed, although symptoms usually present from birth as they vary in severity and may seem intermittent. High index of suspicion is important for early diagnosis.

Plain film demonstrates a nasogastric tube coiled in the upper esophageal pouch. The presence of air in the stomach and distal bowel confirms the presence of a distal fistula. Chest radiographs may show pneumonitis and gastric distension. Diagnosis can be made with a prone, pullback esophagram [3].

Children with congenital TOF require a comprehensive, multidisciplinary management for medical and surgical care to avoid long-term morbidity and mortality. Diagnosis of TOF requires a high index of suspicion and early involvement of not only pediatrician, but also otolaryngologist, pediatric surgeon, and anesthetist as highlighted in all of the aforementioned TOF cases. Diagnosis of TOF is definitely challenging owing to multiple variable and nonspecific clinical presentations, as the symptoms overlap with other differential diagnosis. Approximately 50% of the cases had not been seen by an appropriate subspecialist. The children require multidisciplinary evaluation and effective collaboration for holistic management between the attending team [5] including during the surgical procedure as highlighted in case 3.

The main treatment for TOF is an interventional treatment via surgery that can be performed with bronchoscopy and endoscopy as the primary therapeutic option. Bronchoscopy and endoscopy have become the main method to diagnose TOF, as they are able to identify the fistulas in most cases. Recognition of the tracheal or bronchial opening in small fistulas can be challenging [6].

However, a study by Sharma and Srinivas [7] has highlighted the potential advantage of preoperative bronchoscopy and endoscopy examination, including complete documentation of the airway anatomy with early detection of airway abnormalities, offering decompression of the stomach, and providing the bronchoscopic lavage for culture and sensitivity.

Use of intraoperative bronchoscopic guide wire through the fistula is yet to be explored. The technique has the advantage to identify exact position and pathway of the fistula, apart from being palpable during operation and aid in operation [8]. The combination of diathermy and fibrin glue can be done through endoscopic treatment and have also been reported with variable success [9,10]. Other endoscopic management may include sclerosation, electrocautery, and laser coagulation [9]. In addition, children after TOF repair may have co-existing multiple medical and surgical problems, including chronic respiratory and digestive symptoms owing to the abnormal development of the trachea and esophagus in utero [5]. They may experience feeding difficulties that not only affect the family members but also incur repeated health care utilization. Therefore, treatment approach should be tailored to each specific patient. Even with successful repair of TOF, patient may succumb to complications.

Conclusion

Congenital TOF is a rare anomaly that requires surgical repair in infancy. Diagnosing and locating it at surgery are both difficult. A multidisciplinary management is pivotal in avoiding any potential airway embarrassment. Correctly treating this subset of patient has an outstanding prognosis.

Financial support and sponsorship

Nil.

Conflicts of interest

There are no conflicts of interest.

References

- 1 Shaw-Smith C. Oesophageal atresia, tracheo-oesophageal fistula, and the VACTERL association: review of genetics and epidemiology. *J Med Genet* 2006; 43:545–554.
- 2 Rothenberg S. Esophageal atresia and tracheoesophageal fistula malformations. In: Holcomb GW III, Murphy JP, Ostlie DJ, editors. *Ashcraft's pediatric surgery*. London, UK: Elsevier Inc; 2014. pp. 365–384.
- 3 Slater BJ, Rothenberg SS. Tracheoesophageal fistula. *Semin Pediatr Surg* 2016; 25:178–178.
- 4 Spitz L, Kiely EM, Morecroft JA, Drake DP. Oesophageal atresia: at-risk groups for the 1990s. *J Pediatr Surg* 1994; 29:723–725.
- 5 DeBoer EM, Prager JD, Ruiz AG, Jensen EL, Deterding RR, Friedlander JA. Multidisciplinary care of children with repaired esophageal atresia and tracheoesophageal fistula. *Pediatr Pulmonol* 2016; 51:576–581.
- 6 Bradshaw CJ, Thakkar H, Knutzen L, Marsh R, Pacilli M, Impey L, Lakhoo K. Accuracy of prenatal detection of tracheoesophageal fistula and oesophageal atresia. *J Pediatr Surg* 2016; 51:1268–1272.
- 7 Sharma N, Srinivas M. Laryngotracheobronchoscopy prior to esophageal atresia and tracheoesophageal fistula repair – its use and importance. *J Pediatr Surg* 2014; 49:367–369.
- 8 Antabak A, Luetic T, Caleta D, Romic I. H-type tracheoesophageal fistula in a newborn: determining the exact position of fistula by intra-operative guidewire placement. *J Neonatal Surg* 2014; 3:36.
- 9 Richter GT, Ryckman F, Brown RL, Rutter MJ. Endoscopic management of recurrent tracheoesophageal fistula. *J Pediatr Surg* 2008; 43:238–245.
- 10 Yankovic F, Castillo C, Saenz R, Navarrete C. Endoscopic argon plasma coagulation in recurrent tracheoesophageal fistula. Clinical series and review of the literature. *Gastroenterol Hepatol* 2009;32:600–604.