Congenital nasal stenosis: a report of two cases

Samy El-Wany[a], Diaa M. El-Hennawi[b], Mohamed R. Ahmed[b], Ashraf S. Abou-Halawa[b], Yasser T. Madian[b], Ibrahim H. Ibrahim[b]

[a]Otorhinolaryngology Department, Faculty of Medicine, Alexandria University, Alexandria, [b]Otorhinolaryngology Department, Faculty of Medicine, Suez Canal University, Ismailia, Egypt

Correspondence to Mohamed R. Ahmed, MD, Otolaryngology Department, Faculty of Medicine, Suez Canal University, Ismailia, Egypt. Tel: +20 128 504 3825; fax: +20 663 415 603; e-mail: m_rifaat@hotmail.com

Received 8 December 2018
Accepted 14 February 2019

The Egyptian Journal of Otolaryngology
2019, 35:234–238

The human neonate is an obligate nasal breather for a variable period of time after birth. Congenital nasal airway anomalies are potentially dangerous if they are not immediately recognized at birth and if appropriate intervention is not instituted. Here, we report two clinical cases of congenital nasal stenosis seen in the Suez Canal University Hospital in Ismailia in 2016. Approval from our institutional ethics committee and consent from parents of the patients to publish the cases and their photos were obtained. Level of Evidence: 3b.

Keywords:
congenital-C Nose, neonates, stenosis

Egypt J Otolaryngol 35:234–238

1012-5574

Introduction

The human neonate is an obligate nasal breather for a variable period of time after birth [1]. Congenital nasal airway anomalies are potentially dangerous if they are not immediately recognized and if appropriate intervention is not instituted [2]. Asphyxia and cyanosis in the first few minutes after birth may lead to brain insult [3]. A simple oral airway will bypass the nasal airway and keep the neonate orally breathing. If successful in bypassing the airway obstruction, this also excludes the more serious lower airway anomalies, for example, laryngeal and tracheal anomalies, pulmonary hypoplasia and diaphragmatic hernia [4]. With this life-saving oral airway in place, definitive surgical intervention can be planned. In this work, we report two congenital nasal airway problems.

Case #1

A 2-year-old girl from a poor uneducated family came with nasal obstruction since birth. A catheter failed to pass through the nose during her visits to other ENT clinics. Nasal airway is somehow satisfactory except during the common cold episodes when the child had complete nasal stuffiness, nasal discharge, snoring, and apneic spells during sleep. The mother was sometimes obliged to stay awake beside the child to ensure normal oral breathing. When seen in the clinic, the child was asleep and snoring. Apneic pauses of several seconds were noticed and relieved through awakening. Nasal examination revealed mucopurulent discharge. The nose was cleared with suction, and an ear speculum was inserted into the right and left nostrils. Bony narrowing just beyond the nostril was noticed bilaterally. Oral examination revealed a single big central incisor. Mother reported that with any falling on the face, the child got the lower lip injured by the mere size of this tooth. The hard palate was narrowed, and the tongue and oropharynx were within normal.

X-ray nasopharynx lateral view showed normal adenoid shadow. Computed tomography (CT) revealed narrowing of the pyriform nasal aperture. Choanae were patent bilaterally.

Surgical correction was planned. Under general anesthesia, a sublabial approach was used to drill the bony narrowing at the pyriform aperture using a diamond bit. Drilling was performed only at the right and left corners, keeping away from the nasal floor and preserving the vestibular mucosa intact. Postoperatively, the child had marked improvement of her nasal breathing with disappearance of sleep apnea. She was referred to the dentist who decided to remove the abnormally big central incisor.

Case #2

A neonate was born to a 29-year-old primigravida following 40 weeks of gestation. The mother's history did not include exposure to viral infection, sex hormones, teratogens or ionizing radiation during pregnancy. Following normal vaginal delivery, the neonate was resuscitated for delayed onset of crying and respiration. Apgar score was unknown. Ambiguous genitalia were diagnosed when nonfused

'scrotal' folds and curved phallus between them were noticed. Moreover, it was noticed that there was left-sided coloboma irides in the form of an inferior triangular defect but no ear deformities. No finger, toes or other limb defects were noticed. She was sent to the neonatal ICU on oral airway.

In the neonatal ICU, failure to pass a catheter through the nose into the nasopharynx suggested possible bilateral choanal atresia. CT axial cuts confirmed the atretic plate at the choana bilaterally. The neonate received feeding through an Nasogastric tube (NG) tube through the mouth. Echocardiography and abdominal ultrasound were free. Karyotyping and pelvic ultrasound confirmed female sex, and a girl's name was given.

The neonate was then referred to our department on the 12th day. Under General anesthesia (GA) with ET intubation, nasal endoscopy was performed with a 1.9 mm 0° otoendoscope. Using otologic instruments, an 8 F metal suction was used to perforate the atretic plate bilaterally. Bone fragments were noticed to be very thin and were easily removed using otologic crocodile forceps. Using a pediatric backbiter, the posterior end of the nasal septum was removed. There was minimal bleeding. No attempt was made to create mucosal flaps. A 2–0 silk suture was passed into one nasal cavity to the nasopharynx and then retrieved from the opposite side around the posterior end of the septum. Two #3 Polyvinyl chloride (PVC) tracheal tube were used as a stent. Two months after surgery, the patient had widely patent choanae (Figs 1–3).

Discussion

During the third and fourth weeks of intrauterine life, the nose starts to form nasal placodes, which are thickenings of the surface ectoderm on the lateral surface of the head of the embryo. They gradually sink into depressions and migrate medially to become the nostrils. Thereafter, the tissue surrounding them creates the medial and lateral nasal prominences. The medial nasal processes form the anterior nasal septum, whereas the nasofrontal process forms the posterior nasal septum and the ethmoid, nasal, and premaxillary bones. Finally, the oronasal membrane is resorbed to form the primitive choanae [1].

Congenital nasal anomalies are considered errors in embryogenesis or are a result of intrauterine events affecting embryonic and fetal growth. They may be associated with other craniofacial anomalies [2].

Congenital nasal pyriform aperture stenosis is a rare cause of nasal airway obstruction due to bony overgrowth of the nasal process of the maxilla and its clinical picture is similar to choanal atresia [3,4]. Manifestations in such conditions are apneic crisis, episodic cyanosis, and inability to nurse the newborn [5]. Its etiology is unknown, but it arises in the fourth month of fetal development due to an overgrowth of the nasal process of the maxilla, and may present as an isolated condition or in association with other congenital disorders such as holoprosencephaly, cleft palate, and early presence of maxillary central incisors [6]. Inability to pass a fine catheter through the very

Figure 1

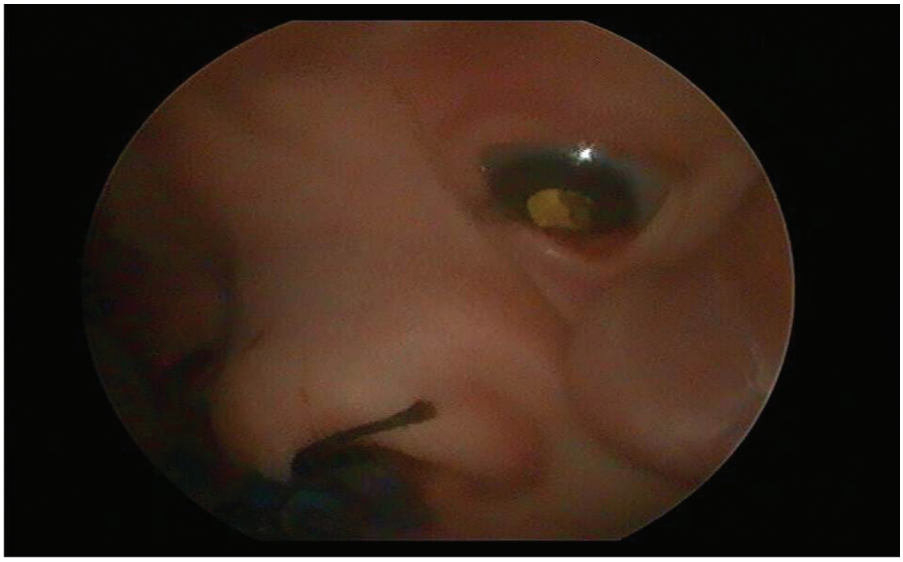

Showing iris defect.

Figure 2

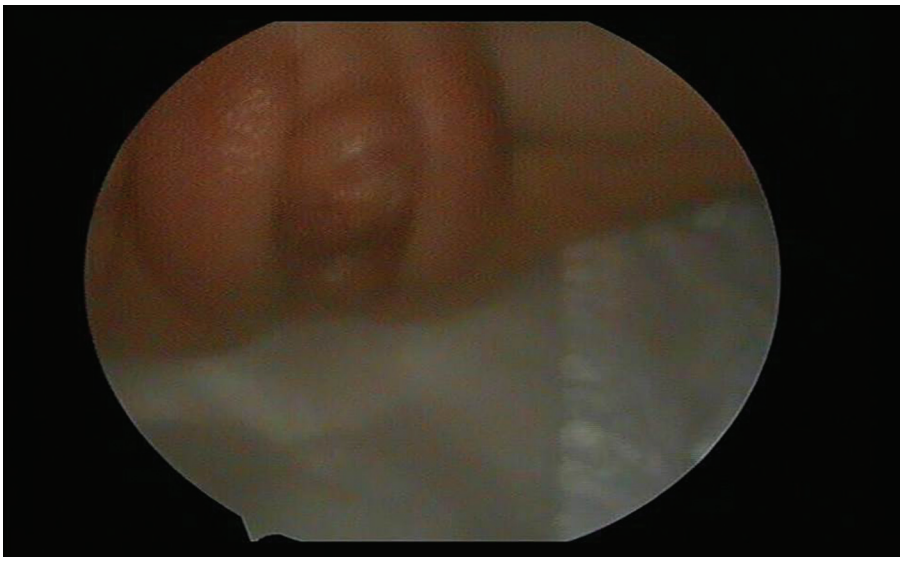

Showing genitalia defect.

Figure 3

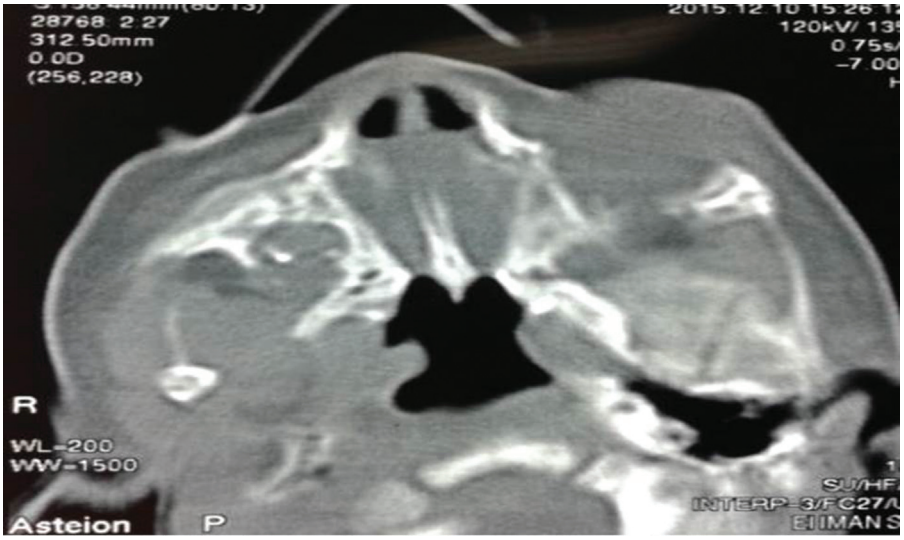

Computed tomography showed bilateral atresia.

nostril should raise suspicion. Investigations depend mainly on CT. A radiographically measured pyriform opening of less than 8–10 mm in a full-term infant is considered diagnostic [7]. Immediate management is to establish a secure airway with endotracheal intubation. Treatment using a nonsurgical approach using silastic stents in the nasal cavity and/or local decongestants is preferable [8]. However, in moderate or severe cases, surgery through a sublabial approach is essential. This provides good bilateral exposure of the pyriform aperture with minimal visible scarring [9]. Using burrs, the stenotic area can be widened with intact mucoperiosteum. A passage for a 3.5-mm endotracheal tube stent is made to ensure satisfactory enlargement. Drilling of the nasal floor must be avoided to prevent damage to the tooth buds [6].

Congenital midnasal stenosis is a midline developmental defect. A missense mutation in the SHH gene at 7q36 has been incriminated [10]. The most significant findings are a single central incisor tooth located precisely in the midline of the maxillary alveolus, and congenital pyriform aperture stenosis with midnasal stenosis [11]. In addition, it could be associated with holoprosencephaly and CHARGE syndrome (colobomata, heart defects, atrasia choanae, retarded growth, genital hypoplasia, and ear abnormalities)

[12] or VACTERL association (vertebral anomalies, anal atresia, cardiac malformations, tracheoesophageal fistula, renal anomalies, and limb anomalies) [13]. Treatment usually is individualized depending on the degree of obstruction: dilatation with or without stenting and surgery [14].

Choanae stenosis is considered to be the most common congenital abnormality of the nasal cavity. Between 4 and 6 weeks of gestation, the primitive choana matures and transforms into the definitive choana when involution takes place for the buccopharyngeal membrane [15]. Different theories have been postulated for choanal atresia, either as an abnormal persistence of buccopharyngeal membrane or nasobuccal membrane, or as mesoderm/neural crest cells present in the wrong location causing adhesions in the choana [16].

Unilateral choanal atresia is more common than bilateral choanal atresia (65–75% of patients with unilateral), and female neonates are more likely to have it (2 : 1 ratio to male neonates), with a high correlation with syndromic illnesses such as CHARGE syndrome, Treacher Collins syndrome, and Crouzon's disease (75% of cases) [17]. Signs and symptoms of bilateral choanal atresia present with cyanosis in a newborn and with respiratory distress that gets worse with feedings.

The ideal procedure for choanal atresia restores the normal nasal passage, prevents damage to growing structures important in facial development, is technically safe, requires a short operative time, and provides short hospitalization and convalescence. Transnasal endoscopic and transpalatal approaches are used in conjunction with application of mitomycin C and stenting to give the patient the best outcome possible [18,19].

Elective transnasal endoscopic repair is the most preferred and minimally invasive procedure [20]. Postoperative stenting is a controversial topic. For many authors, it is a postsurgical adjunct to reduce the chance of restenosis, whereas data from recent studies suggest that there is no difference in restenosis rates regardless of stenting. Close postoperative follow-up, revision endoscopy to remove nasal crusting 1 week after the primary repair, and frequent nasal saline irrigation were key to successful management of choanal atresia without stenting [19]. Carter *et al.* [21] in their recent study had the same conclusion about restenosis rate while showing decreased granulation tissue formation and fewer subsequent surgical debridements with topical mitomycin C treatment.

Conclusion

Congenital nasal obstruction is a surgical emergency, and it should be immediately recognized at birth. Urgent establishment of the airway saves the life of the patient. Removal of bone narrowing in the airway is essential to prevent restonsis.

Financial support and sponsorship

Nil.

Conflicts of interest

There are no conflicts of interest.

References

1 Harley EH. Pediatric congenital nasal masses. Ear Nose Throat J 1991; 70:28–32.
2 Jones KL, Higginbottom MC. Dysmorphology: an approach to diagnosing children with structural defects of the head and neck. Head Neck Surg 1978; 1:35–46.
3 Brown OE, Myer CM, Manning SC. Congenital nasal pyriform aperture stenosis. Laryngoscope 1989; 99:86–91.
4 Sesenna E, Leporati M, Brevi B, Oretti G, Ferri A. Congenital nasal pyriform aperture stenosis: diagnosis and management. Ital J Pediatr 2012; 38:28.
5 Burstein FD, Cohen SR. Piriform aperture stenosis: a rare cause of neonatal airway obstruction. Ann Plast Surg 1995; 34:56–58.
6 Losken A, Burstein FD, Williams JK. Congenital nasal pyriform aperture stenosis: diagnosis and treatment. Plast Reconstr Surg 2002; 109:1506–1511; [discussion 1512].
7 Tagliarini JV, Nakajima V, Castilho EC. Congenital nasal pyriform aperture stenosis. Braz J Otorhinolaryngol 2005; 71:246–249.
8 Lee JJ, Bent JP, Ward RF. Congenital nasal pyriform aperture stenosis: non-surgical management and long-term analysis. Int J Pediatr Otorhinolaryngol 2001; 60:167–171.
9 Sultan B, Lefton-Greif MA, Brown DJ, Ishman SL. Congenital nasal pyriform aperture stenosis: feeding evaluation and management. Int J Pediatr Otorhinolaryngol 2009; 73:1080–1084.
10 Garavelli L, Zanacca C, Caselli G, Banchini G, Dubourg C, David V, *et al.* Solitary median maxillary central incisor syndrome: clinical case with a novel mutation of sonic hedgehog. Am J Med Genet A 2004; 127A:93–95.
11 Becktor KB, Sverrild L, Pallisgaard C, Burhøj J, Kjaer I. Eruption of the central incisor, the intermaxillary suture, and maxillary growth in patients with a single median maxillary central incisor. Acta Odontol Scand 2001; 59:361–366.
12 Harrison M, Calvert ML, Longhurst P. Solitary maxillary central incisor as a new finding in CHARGE association: a report of two cases. Int J Paediatr Dent 1997; 7:185–189.
13 Nordgarden H, Jensen JL, Storhaug K. Reported prevalence of congenitally missing teeth in two Norwegian counties. Community Dent Health 2002; 19:258–261.
14 Kjaer I, Becktor KB, Lisson J, Gormsen C, Russell BG. Face, palate, and craniofacial morphology in patients with a solitary median maxillary central incisor. Eur J Orthod 2001; 23:63–73.
15 Gujrathi CS, Daniel SJ, James AL, Forte V. Management of bilateral choanal atresia in the neonate: an institutional review. Int J Pediatr Otorhinolaryngol 2004; 68:399–407.
16 Hengerer AS, Brickman TM, Jeyakumar A. Choanal atresia: embryologic analysis and evolution of treatment, a 30-year experience. Laryngoscope 2008; 118:862–866.
17 Blake KD, Prasad C. CHARGE syndrome. Orphanet J Rare Dis 2006; 1: 34.
18 Llorente JL, López F, Morato M, Suárez V, Coca A, Suárez C. Endoscopic treatment of choanal atresia. Acta Otorrinolaringol Esp. 2013; 64:389–395.
19 Kwong KM. Current updates on choanal atresia. Front Pediatr 2015; 3:52.

20 Niloofar F, Parvathy K, Varma BR, Mamachan XA. Management of congenital choanal atresia: a pedodontist's role. J Indian Soc Pedod Prev Dent 2015; 33:259–261.

21 Carter JM, Lawlor C, Guarisco JL. The efficacy of mitomycin and stenting in choanal atresia repair: a 20 year experience. Int J Pediatr Otorhinolaryngol 2014; 78:307–311.