

# Acute parotitis in a newborn: a case report and review of the literature

Liliana Costa, Laurentino M. Leal, Fernando Vales, Margarida Santos

Department of Otorhinolaryngology, Centro Hospitalar de São João, EPE, Alameda Professor Hernâni Monteiro, Porto, Portugal

Correspondence to Liliana Costa, MD, Department of Otorhinolaryngology, São João Hospital Center, EPE, Alameda Professor Hernâni Monteiro, 4200-319 Porto, Portugal. Tel: +351225512124; fax +351225504526; e-mail: lilianacmcosta@gmail.com

Received 26 October 2015

Accepted 21 January 2016

The Egyptian Journal of Otolaryngology  
2016, 32:236–239

Acute parotitis is a rare disease in the neonatal period. Risks implicated in its pathogenesis are prematurity and dehydration. *Staphylococcus aureus* is the most common bacterial agent causing this condition. The diagnosis of acute neonatal parotitis is clinical. Treatment consists of intravenous antibiotics, and surgery is reserved for severe complications. The prognosis is favorable with rare recurrence. The authors describe a case of an 8-day-old, full-term boy diagnosed with acute parotitis.

## Keywords:

acute parotitis, newborn, *Staphylococcus aureus*

Egypt J Otolaryngol 32:236–239

© 2016 The Egyptian Journal of Otolaryngology  
1012-5574

## Introduction

Parotid masses in the pediatric population are uncommon and can represent various pathological diagnoses [1]. Acute parotitis is a rare disease in the neonatal period [2–6]. It is characterized by parotid swelling and purulent discharge from Stensen's duct [7]. Risk factors implicated in its pathogenesis are prematurity and dehydration [3]. *Staphylococcus aureus* is the most common bacterial agent causing acute parotitis [2–5]. The diagnosis is clinical [2–6]. Treatment consists of intravenous antibiotics, and surgery is reserved for complications, such as organized abscesses and infections not responding to medical management [7]. The prognosis is favorable with rare recurrence [2,5].

The authors describe a case of neonatal suppurative parotitis in a full-term, 8-day-old boy. This is the first documented case in Portugal. We also review the literature and discuss the diagnosis and treatment of this pathological condition.

## Case presentation

An 8-day-old, full-term boy (40 weeks of gestation, with an eutocic delivery, and birth weight of 3150 g) was brought to the Pediatrics Emergency Department because of fever (maximum 39°C of rectal temperature) and appearance of a swelling in the left parotid region with local inflammatory signs. Facial or head trauma, mother's mastitis, or other maternal skin infection were excluded after the initial assessment. The newborn had prenatal diagnosis of right hydronephrosis, but renopelvic ultrasonography at day 3 was normal. He also had neonatal jaundice requiring phototherapy for 24 h. There were no other perinatal complications, and no relevant maternal or familial history. He was

breastfed. On physical examination, he was found to be in a good general condition, active and reactive, flushed and hydrated. A swelling in the left parotid region with inflammatory signs (tender, redness, and heat) and apparently painful on palpation was verified (Fig. 1). It was impossible to carry out an otoscopy on the left side because of edema of external auditory canal. Oral cavity examination showed purulent drainage from the left Stensen's duct with compression of the left parotid gland. A swab of the pus was collected for microbiological analysis (Fig. 2). There were no other significant alterations on physical examination. Laboratory tests revealed a hemoglobin level of 17.1 g/dl, white blood cell count of 17 730/μl (39.8% neutrophils and 36.3% lymphocytes), platelet count of 142 000/μl, and a slightly raised C-reactive protein (11.4 mg/l). Analytical parameters of liver and kidney function, as well as ionogram, were normal. Ultrasound examination of the left parotid and preauricular region showed a swollen left parotid gland, with increased vascularity and densifications of the overlying tissue planes, but no collections were observed. Taking into account the clinical presentation and ultrasound findings, the boy was diagnosed with left acute suppurative parotitis. The newborn was hospitalized and an intravenous empirical antibiotic therapy with vancomycin (50 mg/kg/day) plus cefotaxime (160 mg/kg/day) was initiated. Moreover, analgesia with paracetamol and intravenous fluid therapy were implemented. After 1

This is an open access article distributed under the terms of the Creative Commons Attribution-NonCommercial-ShareAlike 3.0 License, which allows others to remix, tweak, and build upon the work noncommercially, as long as the author is credited and the new creations are licensed under the identical terms.

day of parenteral therapy the fever subsided and on the fourth day of treatment the parotid swelling significantly diminished. Blood cultures were negative. The Stensen's duct exsudate culture was positive for *S. aureus* sensitive to the instituted antibiotics. Control ultrasound (at fourth day) showed a slight asymmetry of the parotid glands (increased on the left), but no collections were observed. Other analytical studies revealed negativity for HIV, and normal complement fractions but hypogammaglobulinemia A. The child was discharged from the hospital after 9 days of treatment with complete recovery. On the follow-up visit, he was asymptomatic, with normal physical examination. A cervical magnetic resonance image was carried out 2 months later (Fig. 3), which showed almost symmetrical parotid glands (a slight prominence on the left side), with normal morphology, and no suspicious focal lesions, collections, or ductal enlargements. Written informed consent was obtained from the patient for publication of this case report and accompanying images.

## Discussion

Acute bacterial parotitis is rare in the neonatal period [2–6]. It has a prevalence of 3.8–14/10 000 among neonatal admissions [7,8]. Neonatal parotitis has been reported to be more prevalent among males, with a rate of almost 3:1 [4,5,8,9]. Only few case reports and case series are reported in the literature. In 2004, Spiegel *et al.* [8] reviewed all papers published in the English literature since 1970, reporting 32 cases. Decembrino *et al.* [7] reported more 16 cases of neonatal suppurative parotitis described since 2004. In our review, we found two more cases published since then [9,10]. This is the first documented case in Portugal.

The parotid gland is more frequently infected than are the other salivary glands because of its exclusive serous secretions without the bacteriostatic properties of the mucoid component [7]. Although acute parotitis may affect normal healthy neonates, it seems to be more common in premature infants with low birth weight [2–6]. This is presumptively related to an higher risk for dehydration, which may reduce salivary secretion causing salivary stasis, which promotes bacterial ascent along the salivary duct [7]. Bacterial seeding of the parotid gland can also occur hematogenously [4]. Other risk factors implicated in parotitis are nasogastric intubation, sepsis, structural glandular

abnormalities, cephalic or facial trauma, and immunodeficiency/immunosuppression [3,4].

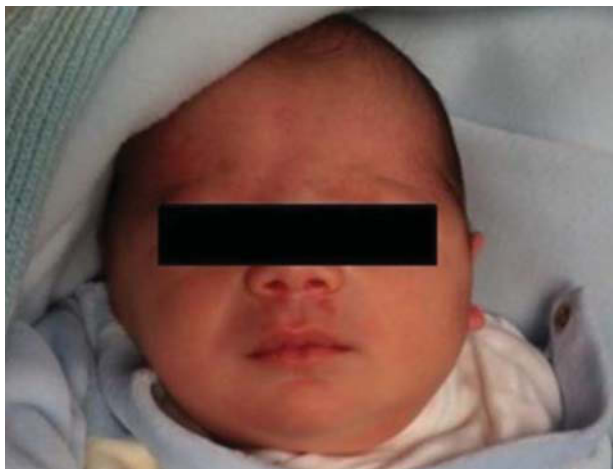Host defense of the upper aerodigestive tract depends on the cellular and humoral immunity mechanisms, which are active throughout the body, and on specialized functions to mucosal surfaces [such as mucociliary clearance and immunoglobulin (Ig) A antibody secretion] [11]. Otolaryngologic presentations are common in immunodeficient hosts [11,12]. In our case, hypogammaglobulinemia A was diagnosed. Selective IgA deficiency is asymptomatic in up to 90% of patients. It may course with head and neck infections, including rhinosinusitis, otitis media, mastoiditis, adenotonsillitis, and parotitis [11]. In the follow-up analytical studies, the IgA level of our patient was within normal values, meaning that it was just a transient antibody deficiency, which may be found in neonates.

*S. aureus* is the most common bacterial agent causing acute parotitis [2–5]. Other less frequent agents are other gram-positive cocci (*Streptococcus pyogenes*, *Streptococcus agalactiae*, *Streptococcus viridans*), gram-negative bacilli (*Escherichia coli*, *Klebsiella pneumoniae*, *Pseudomonas aeruginosa*), and, rarely, anaerobic agents (*Peptostreptococcus* spp., *Bacteroides melaninogenicus*, *Fusobacterium nucleatum*, *Prevotella* spp.) [4,5,7,9].

The diagnosis is clinical [2–6]. Purulent discharge from Stensen's duct is pathognomonic of acute suppurative parotitis [9]. Other symptoms and signs are parotid gland swelling, tenderness, erythema, and heatness [7,9]. Fever is present in about a third of the cases [9]. The analytical study may show leukocytosis with neutrophilia and elevated C-reactive protein [3,4]. Culture of the exsudate from the parotid duct will both confirm the diagnosis and help guide the treatment [4]. It can be obtained by sampling pus coming from Stensen's duct (less invasive, but less specific), or by direct needle aspiration of the parotid (more specific and avoids contaminations by the normal oral bacterial flora) [7].

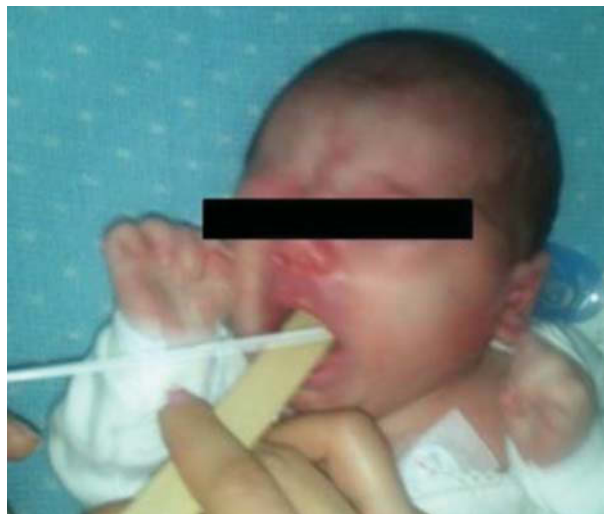Parotid ultrasound may reveal a diffusely enlarged gland with a coarse echo pattern and eventually abscess [3–5]. Ultrasonography is cheap and noninvasive. It is very useful for diagnosis, differential diagnosis, and to exclude predisposing factors like anatomical abnormalities of Stensen's duct, mechanical salivary duct obstruction secondary to a sialolith, and infection related to a parotid gland neoplasm [7].

Figure 1



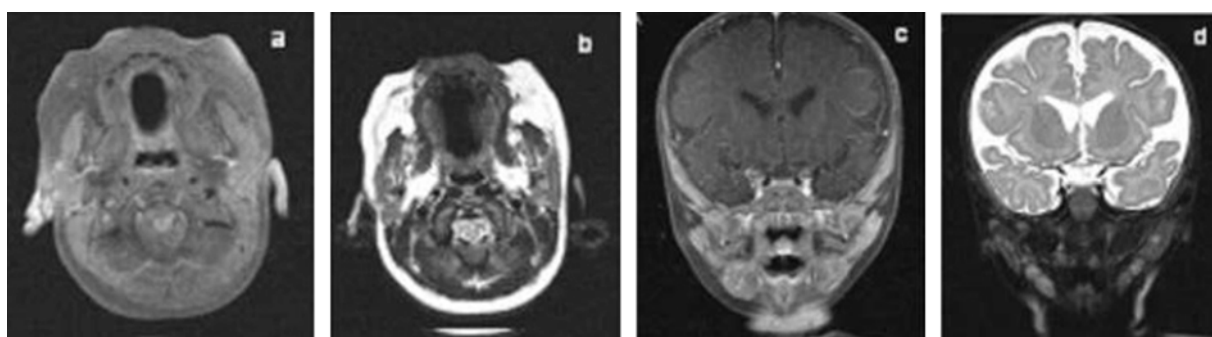
Swelling in the left parotid region with inflammatory signs.

Figure 2



Collecting pus from the left parotid duct for microbiology.

Figure 3



Cervical MRI: slight prominence on the left parotid gland with no structural alterations. (a) T1 axial cut; (b) T2 axial cut; (c) T1 coronal cut; (d) T2 coronal cut.

The differential diagnosis includes facial trauma, facial skin infection/cellulitis, cervical or preauricular lymphadenopathy, osteomyelitis, subcutaneous fat necrosis, and abscess formation, buccinators muscles infection, and tumors [5–7].

The treatment consists of intravenous antibiotic therapy, which must be maintained for 7–10 days [4,5]. The initial empirical treatment must include an antistaphylococcal antibiotic [5,7]. The increase of methicillin-resistant staphylococci may require the use of vancomycin; in the presence of an anaerobic, the treatment may include a combination of metronidazole and a macrolide or a penicillin plus  $\beta$ -lactamase inhibitor (clavulanate) [5].

Due to the prompt antibiotic treatment, complications are rare. They include facial paralysis, salivary fistula, mediastinitis, and inflammation extension to the

ipsilateral external ear [5]. In most cases, antibiotic therapy leads to clinical improvement within the first 24–48 h, with reduction in the parotid swelling [7]. Correct hydration and analgesia must also be carried out. Surgical treatment is rarely necessary [2–6].

The prognosis is favorable in most cases. If clinical improvement does not occur in the first few days, image repeating should be done to exclude abscess formation. The presence of intraparotid abscess requires incision and drainage [7]. Recurrence of acute suppurative parotitis is rare [2–6].

### Conclusion

Acute suppurative parotitis is rare in the neonatal period. Its diagnosis is clinical: parotid swelling and purulent exudate from Stensen's duct. The treatment consists of intravenous antibiotics; surgery is rarely needed.

---

## Acknowledgements

Authors' contributions: L.C. and L.M.L. drafted the manuscript; L.C., L.M.L., and F.V. contributed to the diagnosis and treatment; M.S. reviewed the manuscript. All the authors read and approved the final version of the manuscript.

## Conflicts of interest

The authors declare no conflict of interests.

---

## REFERENCES

- 1 Orvidas LJ, Kasperbauer JL, Lewis JE, Olsen KD, Lesnick TG. Pediatric parotid masses. *Arch Otolaryngol Head Neck Surg* 2000; 126177–184.
- 2 Smolkin T, Makhoul IR, Sujov P. Staphylococcal parotitis in a neonate. *Isr Med Assoc J* 2002; 4657.
- 3 Makhoul J, Lorrot M, Teissier N, Delacroix G, Doit C, Bingen *Eet al.* Acute bacterial parotitis in infants under 3 months of age: a retrospective study in a pediatric tertiary care center. *Arch Pediatr* 2011; 181284–1289.
- 4 Özdemir H, Karbuş A, Ciftçi E, Fitöz S, Ince E, Dogru U. Acute neonatal suppurative parotitis: a case report and review of the literature. *Int J Infect Dis* 2011; 15e500–e502.
- 5 Ayala Curiel J, Galán del Río P, Poza del Val C, Aguirre Conde A, Coteró Lavín A. Neonatal acute suppurative parotitis. *An Pediatr (Barc)* 2004; 60274–277.
- 6 Nso Roca AP, Baquero-Artigao F, García-Miguel MJ, del Castillo Martín F. Acute neonatal parotitis due to *Streptococcus agalactiae*. *An Pediatr (Barc)* 2007; 6765–67.
- 7 Decembrino L, Ruffinazzi G, Russo F, Manzoni P, Stronati M. Monolateral suppurative parotitis in a neonate and review of literature. *Int J Pediatr Otorhinolaryngol* 2012; 76930–933.
- 8 Spiegel R, Miron D, Sakran W, Horovitz Y. Acute neonatal suppurative parotitis: case reports and review. *Pediatr Infect Dis J* 2004; 2376–78.
- 9 Gilbey P, Bretler S, Even-Tov E, Luder A. Accidental out-of-hospital delivery complicated by acute neonatal parotitis: case report and a review of the literature. *Int J Pediatr Otorhinolaryngol Extra* 2011; 6385–387.
- 10 Sekhon P, Williams D, Singh Sara JD, McCulloch NA. Acute bacterial suppurative parotitis of the neonate: a case report and review. *Int J Pediatr Otorhinolaryngol Extra* 2012; 7132–133.
- 11 De Vincentis GC, Sitzia E, Bottero S, Giuzio L, Simonetti A, Rossi P. Otolaryngologic manifestations of pediatric immunodeficiency. *Int J Pediatr Otorhinolaryngol* 2009; 73S42–S48.
- 12 Wasserman RL, Manning SC. Diagnosis and treatment of primary immunodeficiency disease: the role of the otolaryngologist. *Am J Otolaryngol* 2011; 32329–337.