Intermediate-grade mucoepidermoid carcinoma arising from Warthin's tumour of parotid gland

Arsheed H. Hakeem[a], Imtiyaz H. Hakeem[c], Fozia J. Wani[b]

[a]Departments of Surgical Oncology (Head and Neck), [b]Gynaecology and Obstetrics, Apollo Cancer Institute, Hyderabad, India, [c]Poplar Bluff Regional Medical Center, Poplar Bluff, Missouri, USA

Correspondence to Arsheed H. Hakeem, MBBS, MS, Department of Surgical Oncology (Head and Neck), Apollo Cancer Institute, Jubilee Hills, Hyderabad - 500 096, India
Tel: 91-40-23607777; fax: 91-40-23545588; e-mail: drahhakim@gmail.com

Received 26 November 2014
Accepted 7 December 2014

The Egyptian Journal of Otolaryngology
2016, 32:113–115

Warthin's tumour (WT), also known as the adenolymphoma, is the second common benign neoplasm that mostly occurs in the parotid gland. Malignant transformation of the epithelial or lymphoid component of the WT has been rarely reported. We describe a case of a 73-year-old woman who underwent total radical parotidectomy with modified neck dissection on the left side. The case was diagnosed as intermediate-grade mucoepidermoid carcinoma developed in the setting of WT based on histomorphologic findings. Clinical presentation, pathogenesis, differential diagnosis and management of the rare malignancy have been discussed briefly.

Keywords:
intermediate-grade mucoepidermoid carcinoma, parotid gland, Warthin's tumour

Egypt J Otolaryngol 32:113–115

1012-5574

Introduction

Warthin's tumour (WT) is a benign salivary gland neoplasm occurring principally in the parotid gland of men in the sixth and seventh decades of life [1–5]. WT or adenolymphoma is the second most frequent benign tumour of the parotid gland representing 6–10% of all tumours of the salivary glands [6]. Malignant transformation of the WT is rare and its reported incidence is 0.3% [1–5]. Only few cases of squamous, [2–5] adenocarcinoma [6–9] and mucoepidermoid carcinoma [10–13] arising in the setting of WT have been reported in the English language literature. We report a case of intermediate-grade mucoepidermoid carcinoma arising in WT of the parotid gland in a 73-year-old woman. We describe the clinical presentation, differential diagnosis and management of this rare malignancy.

Case report

A 73-year-old woman presented to us with swelling in the left parotid region of 2 years duration. There was a short, 1-month history of progressive increase in size of the swelling and facial nerve deficit. On examination, the swelling was firm in consistency extending from zygomatic arch to the inferior border of the mandible. It was associated with multiple neck nodes in the levels II and III of the neck on the left side. MRI of the left parotid gland and neck showed ill-defined 4.7 × 4.2 × 4.0 cm lesion involving superficial and deep lobe of the parotid. There was another 4.1 × 3.5 × 2.5 cm diffusely enhancing lesion in the submandibular region on the left side. Fine-needle aspiration cytology was suggestive of mucoepidermoid carcinoma. She underwent total radical parotidectomy with modified neck dissection on the left side. Histopathologic study showed haphazardly placed mucin-filled cysts and solid tumour nests composed of mucinous, epidermoid, intermediate and clear cells in variable combinations (Fig. 1). Mild-to-moderate nuclear atypia and mitotic figures were seen. Perineural infiltration was observed (Fig. 2). Background showed dense, diffuse and nodular lymphoid cell population with germinal centres (Fig. 3). Cleft-like spaces were seen, which were lined by oxiphilic cells consistent with residual WT. The adjacent non-neoplastic salivary gland was unremarkable. Four neck nodes were found to have metastatic mucoepidermoid carcinoma. Therefore, diagnosis of intermediate mucoepidermoid carcinoma arising in the setting of the WT was made. Postoperative recovery was uneventful and the patient was referred for radiotherapy. Three years postsurgery, she died of cardiac ailment.

Discussion

WT is the second common benign tumour of the salivary glands. Malignant transformation of epithelial or lymphoid component of WT is extremely rare. Malignant transformation to squamous carcinoma, adenocarcinoma and various grades of epidermoid carcinoma has been reported in the literature [2–13]. Mucoepidermoid carcinomas have been rarely described with varying grades of differentiation [10–13]. A change in the phenotype of cells through to squamous metaplasia and goblet cell metaplasia is a well-known feature of WT and

Figure 1

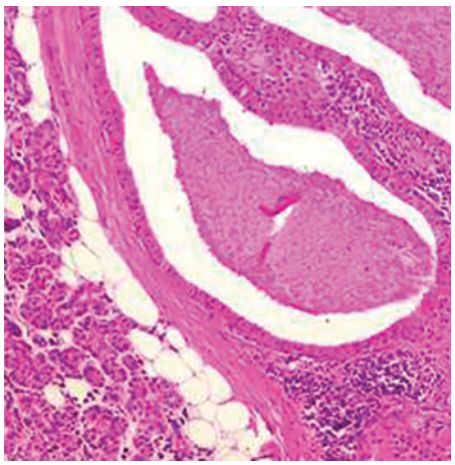

Photomicrograph showing cystic Warthin's tumour with adjacent normal salivary gland (H and E, ×100).

Figure 2

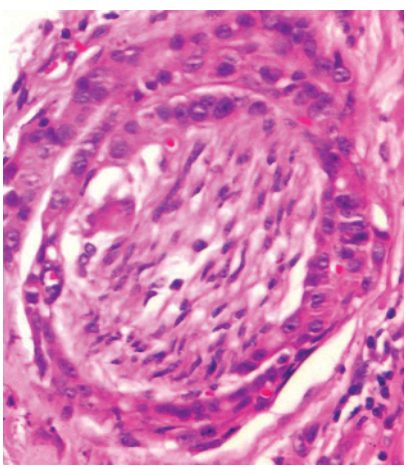

Photomicrograph showing perineural infiltration (H and E, ×400).

Figure 3

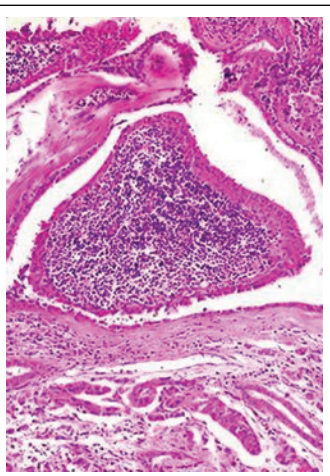

Photomicrograph showing background with dense, diffuse and nodular lymphoid cell population with germinal centres (H and E, ×100).

may thus explain the occurrence of epidermoid and mucoepidermoid carcinoma [11].

Epithelial neoplasia in the background of the WT should be distinguished from a coexistent separate neoplasm, which is most commonly seen. It may arise synchronously or metachronously from the same or opposite side of the neck, most common being pleomorphic adenoma. It needs to be differentiated from metastatic deposit in lymphoid stroma from primary carcinoma in the head and neck region. In our case, there was no such primary tumour of the head and neck region. Histomorphologically, the tumour resembled WT with areas of mucoepidermoid carcinoma along with areas showing transition zone from columnar oncocytic epithelium to hyperplastic–dysplastic mucinous and squamous epithelium.

Malignant transformation of WT is to be considered only when bulk of the carcinoma is inside the WT and the oncocytic epithelium shows a transition zone from hyperplastic–dysplastic state of malignancy [14]. On the basis of the gross and microscopic anatomy, a diagnosis of intermediate-grade mucoepidermoid carcinoma in the setting of the WT was made. Similar to other salivary gland tumours, surgery is the initial treatment followed by adjuvant radiotherapy, if indicated. In our case, facial nerve could not be preserved and metastatic nodes were seen on histopathology; therefore, adjuvant radiotherapy was also given.

In conclusion, intermediate-grade mucoepidermoid carcinoma in WT is a very rare possibility, but one should keep this in differential diagnosis. It needs to be differentiated from the metastatic deposit in a lymph node from other primary head and neck cancer.

Conflicts of interest
There are no conflicts of interest.

References

1 Huvos AG, Paulino AFG. In: Stenberg SS, ed. Salivary glands. *Diagnostic surgical pathology.* 3rd ed. Philadelphia, PA: Lippincott Williams & Wilkins; 1999. 861–862.

2 Gunduz M, Yamanaka N, Hotomi M, *et al.* Squamous cell carcinoma arising in a Warthin's tumor. Auris Nasus Larynx 1999; 26:355–360.

3 Skalova A, Michal M, Nathansky Z. Epidermoid carcinoma arising in Warthin's tumour: a case study. J Oral Pathol Med 1994; 23:330–333.

4 Morrison GAJ, Shaw HJ. Squamous carcinoma arising within a Warthin's tumor of the parotid gland. J Laryngol Otol 1988; 102:1189–1191.

5 Damjanov I, Sneff EM, Delerme AN. Squamous cell carcinoma arising in Warthin's tumor of the parotid gland. A light, electron microscopic, and immunohistochemical study. Oral Surg Oral Med Oral Pathol 1982; 55:286–290.

6 Bengoechea O, Sanchez F, Larrinaga B, Martinez-Penuela JM. Oncocytic adenocarcinoma arising in Warthin's tumor. Pathol Res Pract 1989; 185:907–911.

7 Therkildsen MH, Christensen N, Andersen LJ, Larsen S, Katholm M. Malignant Warthin's tumour: a case study. Histopathology 1992; 21:167–171.

8 Bell D, Luna MA. Warthin adenocarcinoma: analysis of 2 cases of a distinct salivary neoplasm. Ann Diagn Pathol 2009; 13:201–207.

9 Deodhar KK, Shah M, Chaturvedi P. High-grade adenocarcinoma (ductal type) arising in unilateral Warthin tumour of the parotid gland. Indian J Pathol Micrbiol 2011; 54:574–577.

10 Nagao T, Sugano I, Ishida Y, Tajima Y, Furuya N, Kondo Y, *et al.* Mucoepidermoid carcinoma arising in Warthin's tumour of the parotid gland: report of two cases with histopathological, ultrastructural and immunohistochemical studies. Histopathology 1998; 33:379–386.

11 Yamada S, Matsuo T, Fujita S, Suyama K, Yamaguchi A, Mizuno A. Mucoepidermoid carcinoma arising in Warthin's tumor of parotid gland. Pathology Int 2002; 52:653–656.

12 Mardi K, Sharma J. Mucoepidermoid carcinoma arising in Warthin's tumor: a case report. Indian J Pathol Microbial 2007; 50:331–333.

13 Mohapatra M, Satyanarayana S. Low grade mucoepidermoid carcinoma in a setting of Warthin's tumor. Indian J Pathol Microbiol 2012; 55:392–394.

14 Ferrero S, Cattaneo L, Peri A, Braidotti P, Cioffi U, Scaramallini G, *et al.* Poorly differentiated carcinoma arising from adenolymphoma of the parotid gland. BMC Surg 2003; 3:1.