

Conchopexy of middle turbinate versus bolgarization in endoscopic sinus surgery

Mohamed A. Hegazy, Ahmed Shawky, Mahmoud S. El Fouly, Abdelnaser El Kabani

Ear, Nose, and Throat Department, Faculty of Medicine, Cairo University, Cairo, Egypt

Correspondence to Mahmoud S. EL Fouly, MD, 114 Tahrir Street, Dokki, 12311 Cairo, Egypt
Tel: +201009009004;
e-mail: melfouly@gmail.com

Received 18 December 2014

Accepted 03 April 2015

The Egyptian Journal of Otolaryngology
2015, 31:219–223

Objectives

The aim of this study is to assess the role of simple conchopexy suture in maintaining a widely patent middle meatus during the phase of postoperative healing (and its effect on olfaction); this enables delivery of topical medication and sinus aeration compared with functional endoscopic sinus surgery (ESS) with and without bolgarization of the middle turbinate (MT).

Patients and methods

This study included 39 patients. Patients were divided into three equal groups randomly; each group included 13 patients. Group A underwent ESS with suture medialization of the MT (method), group B underwent ESS with bolgarization of the MT, and group C underwent normal ESS. Items of comparison between the three groups included both subjective and objective parameters such as symptoms (nasal obstruction, facial pain, and smell) and endoscopy findings. All the patients underwent preoperative and 2-month postoperative assessment with a questionnaire, smell test, and endoscopic examination.

Results

In terms of nasal obstruction in all three groups, there was a statistically significant improvement ($P = 0.001$, 0.001 , and 0.002 , respectively). Improvement in facial pain was statistically highly significant in group A ($P = 0.0007$), whereas it improved significantly in groups B and C ($P = 0.001$ and 0.002 , respectively). Improvement in smell was statistically insignificant in all three groups ($P = 0.4$). The postoperative endoscopy findings improved compared with the preoperative findings in all three groups.

Conclusion

MT conchopexy and bolgarization of the MT have no detectable adverse effects on olfaction. No lateral synechia was detected, and there was a highly significant improvement in facial pain scores were observed in patients who underwent conchopexy; patients who underwent middle turbinate bolgarization also showed improvement in both aspects, but in a lower percent. Both conchopexy and bolgarization of the MT after conventional ESS may help improve postoperative ostiomeatal complex patency, mucosal healing, and minimize adhesions, with no adverse effect on olfaction.

Keywords:

adhesions, bolgarization, conchopexy, middle turbinate suturing

Egypt J Otolaryngol 31:219–223

© 2015 The Egyptian Oto - Rhino - Laryngological Society
1012-5574

Introduction

The middle turbinate (MT) lateralization is a common complication of endoscopic sinus surgery (ESS) that occurs when opposing areas of denuded mucosa form a scar between them. This scar pulls the MT laterally to the lateral nasal wall and may cause obstruction of the middle meatus and the maxillary, ethmoid, or frontal sinuses, which can result in failure of the initial procedure and often necessitates revision surgery [1,2].

The MT medialization is reliable and should be considered an alternative to turbinate resection [3]. It was also noted that MT medialization exerted no detectable adverse effect on olfaction, and turbinate medialization techniques have gained popularity in an attempt to prevent turbinate lateralization [4].

Current techniques for medialization of the MT include techniques that use pacers and packing, controlled scarring of the MT and adjacent septum (bolgarization), and suturing of the MT to the septum. Recently, a new technique allows insertion of a tiny resorbable implant that anchors the MT to the septum. The MediENT MT implant presents a simple and effective solution.

The aim of the present study is to compare between different methods of medialization of the MT and their impact on postoperative signs and symptoms.

This is an open access article distributed under the terms of the Creative Commons Attribution-NonCommercial-ShareAlike 3.0 License, which allows others to remix, tweak, and build upon the work non-commercially, as long as the author is credited and the new creations are licensed under the identical terms.

Patients and methods

Patients

Thirt-nine patients with chronic rhinosinusitis (CRS) that was refractory to ordinary medical treatment were enrolled in this study. Inclusion criteria were all patients with CRS who had failed medical treatment. Exclusion criteria were previous surgical treatment for CRS and findings suggestive of allergic fungal sinusitis.

Informed consent was obtained from all patients after approval of the study by the ethical committee. All procedures were performed at the ENT Department, Kasr Al Aini Hospital, Cairo University, during the period from December 2010 till May 2012.

Study design

The study was designed as a prospective randomized-controlled study. Patients were divided into three equal groups of 13 patients each.

Surgical technique

All surgeries were performed with the patient under general anesthesia. At the beginning of the surgery, the mucosa and nasal cavities were decongested using nasal packs with 1 : 100 000 saline adrenaline. A standard ESS technique was used.

Group A: 4-0 vicryl suture on a straight needle is passed through the MT from lateral to medial traversing the nasal septum to the contralateral side, then continued through the MT and brought out through the nose. It is then passed again in the opposite direction through the same structures and tied, thus securing the MTs tightly against the septum.

Group B: The mucosa of the medial surface of the MT, just posterior to the turbinate caudal end, and the opposing septal mucosa are abraded with a sickle knife. This results in a denuded area measuring $\sim 3 \times 3$ mm on both surfaces. The MT is pushed medially and nasal packing is placed lateral to the MT to maintain its position for 24–48 h. This technique results in controlled synechia formation between the MT and the nasal septum.

Group C: Conventional ESS.

Assessment parameters

Two main parameters were used to evaluate the efficacy of the treatment: symptoms and endoscopic scoring.

Preoperative and postoperative subjective outcomes of symptoms (nasal obstruction, facial pain, and olfaction) were assessed using the visual analogue scale.

Preoperative and postoperative objective assessments were performed by endoscopy before and 2 months after the operation in terms of inflammatory edema of the ostiomeatal complex (OMC), muco-pus in the middle meatus, and the presence of scarring and adhesions, which was quantified on 0–2-point basis (0 = not present, 1 = present, and 2 = marked).

Statistical analysis

Statistical presentation and analysis of the present study were carried out using SPSS v.16 (IBM, Armonk, New York, USA). Descriptive statistics were determined for all variables, including mean, SD, and range. The independent-sample Student *t*-test was used for the statistical analysis of all of our parametric variables. A *P* value of 0.05 or less was considered significant and a *P* value of 0.001 or less was considered highly significant.

Results

Demographic data

Among the study population, there were 17 males (43.59%) and 22 females (56.41%). Patients ranged in age between 14 and 56 years, with a mean age of 31.8 ± 11.6 years. There was no statistical difference in ages between all groups.

Nasal obstruction

Preoperative nasal obstruction visual analogue scale of patients in group A ranged from 5 to 10, with a mean of 7.38 ± 1.76 , and the postoperative score ranged from 0 to 4, with a mean of 0.85 ± 0.99 ; the improvement was found to be statistically significant ($P = 0.001$). The preoperative values of patients in group B ranged from 5 to 8, with a mean of 6.38 ± 1.19 , whereas postoperative values ranged from 0 to 3, with a mean of 0.77 ± 1.01 ; the improvement was found to be statistically significant ($P = 0.001$). The preoperative results of patients of group C ranged from 5 to 10, with a mean of 6.46 ± 1.66 , whereas the postoperative results ranged from 0 to 4, with a mean of 1.85 ± 1.63 , with statistical significance ($P = 0.002$).

Facial pain

The preoperative mean scores of patients in groups A, B, and C were 5.69 ± 2.25 , 5.92 ± 1.44 , and 6.15 ± 2.19 , respectively; the postoperative mean scores showed improvement, which was statistically highly significant

($P = 0.0007$) in group A, statistically significant ($P = 0.001$) in group B, and statistically significant ($P = 0.002$) in group C.

Olfaction

In all three groups, there was an improvement in smell sensation, which was statistically insignificant ($P = 0.04$).

Endoscopic findings

The preoperative endoscopic score of the patients in group A ranged from 2 to 6, with a mean of 4 ± 1.53 , whereas the postoperative endoscopic score ranged from 0 to 2, with a mean of 0.77 ± 0.83 , with statistical significance ($P = 0.002$) (Figs. 1 and 2).

The preoperative endoscopic score of the patients in group B ranged from 2 to 6, with a mean of 3.46 ± 1.45 ,

whereas the postoperative endoscopic score ranged from 0 to 3, with a mean of 1.15 ± 1.28 , with statistical significance ($P = 0.002$) (Figs. 3 and 4).

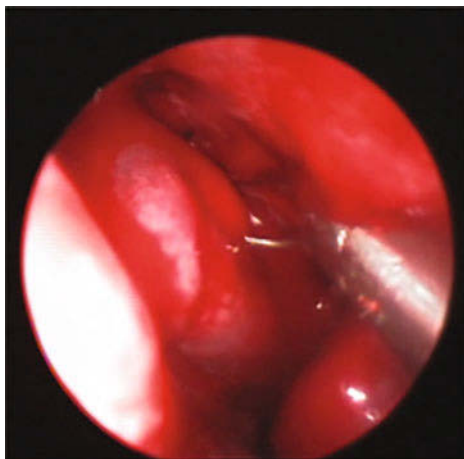
In group C, the preoperative endoscopic score ranged from 2 to 6, with a mean of 3.85 ± 1.42 , whereas the postoperative endoscopic score ranged from 0 to 4, with a mean of 1.62 ± 1.76 , with statistical significance ($P = 0.003$) (Fig. 5 and Table 1).

Discussion

Lateralization of the MT with scarring and obstruction of the middle meatus after endoscopic ethmoidectomy accounts for a high percentage of postoperative complications [5].

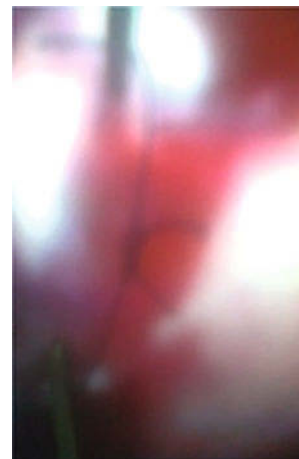
Turbinate medialization techniques have gained popularity in an attempt to prevent turbinate

Figure 1



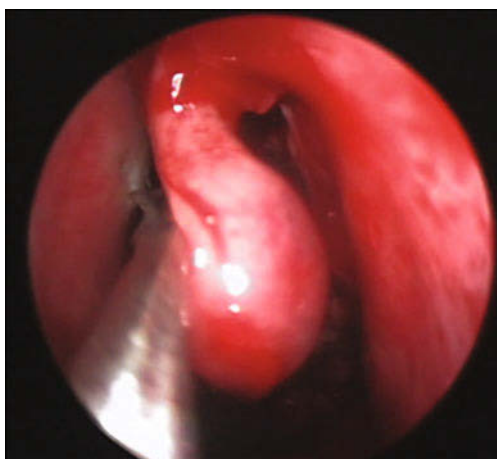
Straight needle in middle turbinate (MT) suturing in group A.

Figure 2



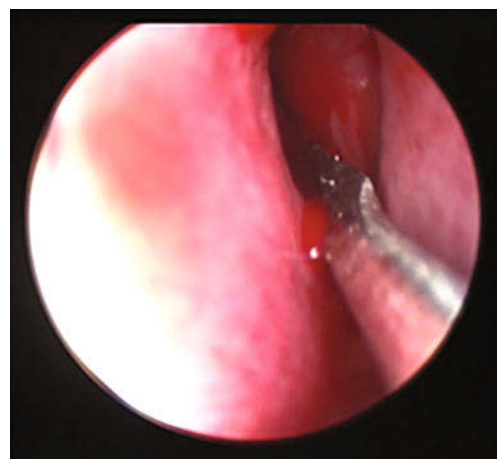
Stabilization middle turbinate (MT) by 4-0 vicryl suture in group A.

Figure 3



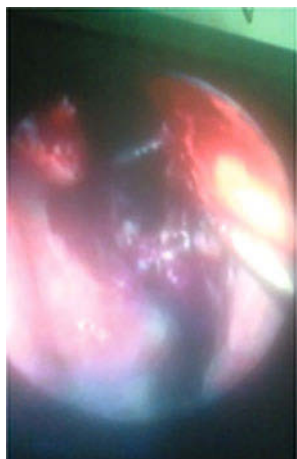Bolgarization of the septum.

Figure 4



Bolgarization of middle turbinate (MT) with a sickle knife.

Figure 5



Adhesions in the middle meatus in group C.

Table 1 Comparative analysis of the postoperative symptoms score, endoscope score, CT score, and smell test score using an independent-sample t-test

Symptoms	Group A	Group B	Group C
Nasal obstruction (VAS)	0.85 ± 0.99	0.77 ± 1.01	1.85 ± 1.63
Facial pain (VAS)	0.46 ± 0.66	1 ± 1.22	1.15 ± 1.14
Smell (VAS)	1.07 ± 0.95	1.15 ± 1.28	0.84 ± 0.90
Overall symptom	1.85 ± 1.57	1.62 ± 1.50	2.08 ± 1.93
Endoscope score	0.77 ± 0.83	1.15 ± 1.28	1.62 ± 1.76
Smell test score	30 ± 7.07	26.15 ± 5.45	28.46 ± 8.51

VAS, visual analogue scale; CT, computed tomography.

lateralization and MT medialization has no detectable adverse effect on olfaction [4].

Stabilization of MT with a turbinate trans-septal suture was performed in patients by 4-0 vicryl suture on a straight needle. Only one patient was noted to have lateralization of the MT on one side that necessitated further surgery despite excellent results; it was found that the initial success rate after ESS with suture stabilization of MT was 98% in to achieve a patent the middle meatus without synechia or maxillary sinus ostium obstruction postoperatively [5].

Another attempt at stabilization of MT with a turbinate trans-septal suture was made in 30 patients by 3-0 vicryl suture on a curved needle. It was found that OMCs were patent in 93.7% of patients. MT of two cases were lateralized because of parted suture. Four patients complained of hyposmia after surgery, which disappeared in the postoperative period [6].

The current study is complementary to a previous work. In this study, we compared different techniques of MT medicalization and their effect on symptoms and postoperative endoscopy findings. We studied three groups: group A underwent ESS with suturing

medicalization of the MT, group B underwent ESS with bolgarization of MT, and finally, group C underwent conventional ESS. In our study, all three groups showed statistically significant improvements in nasal obstruction; also, there was no worsening of sense of smell. The patients in group A showed a highly statistically significant improvement in facial pain ($P = 0.0007$), whereas the patients in both groups B and C showed a statistically significant improvement ($P = 0.001$ and 0.002 , respectively).

The postoperative endoscopic findings in group A indicated complete resolution of mucosal edema and disappearance of mucopus in 100% of cases; none of our patients had scarring or adhesions. The patients in group B showed complete resolution of mucosal edema and disappearance of mucopus in 83% of cases; two patients had postoperative lateral synechia and adhesions (15%). Finally, the postoperative endoscopic findings of patients of group C showed complete resolution of mucosal edema (100%) and disappearance of mucopus in 60% of cases; five patients had postoperative lateral synechia and adhesions (38%). The results of our study are comparable with those obtained by Thorton and Kim's in terms of postoperative endoscopic findings. Also, our study showed that postoperative lateralization of the MT was prevented using conchopexy; this is in agreement with the work of Chen *et al.* [7], who concluded that turbinate suture medicalization of the MT after ESS is very effective against postoperative lateralization.

Dutton and Hinton [8], in their work in 2011, studied the effect of conchopexy on olfaction on a large number of patients and they reported that application of an MT suture does not exert any effect on olfactory functions.

Conclusion

MT conchopexy, bolgarization of the MT, and conventional ESS have no detectable adverse effects on olfaction. No lateral synechia and a highly significant improvement in facial pain scores were observed in patients who underwent conchopexy; patients who underwent MT bolgarization also showed improvements in both aspects, but in a lower percent.

Although further studies should be carried out with a broader population of patients and with longer periods of close endoscopic and symptomatic follow-up, both conchopexy and bolgarization of the MT after conventional ESS may help improve postoperative OMC patency, mucosal healing, and minimize adhesions while having no adverse effect on olfaction.

Financial support and sponsorship

Nil.

Conflicts of interest

There are no conflicts of interest.

References

- 1 Hewitt KM, Orlandi RR. Suture medialization of the middle turbinates during endoscopic sinus surgery. *Ear Nose Throat J* 2008; 87:E11.
- 2 Friedman M. *Middle turbinate medialization with bovine serum albumin tissue adhesive (BioGlue Department of Otolaryngology – Head and Neck Surgery*. California: University of California–Irvine Medical Center, Orange; 2007. 4. 307–309.
- 3 Friedman M, Landsberg R, Tanyeri H. Middle turbinate medialization and preservation in endoscopic sinus surgery. *Otolaryngol Head Neck Surg* 2000; 123 (Pt 1):76–80.
- 4 Friedman M, Tanyeri H, Landsberg R, Caldarelli D. Effects of middle turbinate medialization on olfaction. *Laryngoscope* 1999; 109:1442–1445.
- 5 Thornton RS. Middle turbinate stabilization technique in endoscopic sinus surgery. *Arch Otolaryngol Head Neck Surg* 1996; 122:869–872.
- 6 Kim ST, Chung YS, Choi JH, Jeon HG, Ko SH, Cha HE, Han GC. Middle turbinate stabilization after endoscopic sinus surgery: The suture technique. *Korean J Otolaryngol Head Neck Surg* 2003; 46:309–312.
- 7 Chen W, Wang Y, Bi Y, Chen W. Turbinate-septal suture for middle turbinate medialization: a prospective randomized trial. *Laryngoscope* 2015; 125:33–35.
- 8 Dutton JM, Hinton MJ. Middle turbinate suture conchopexy during endoscopic sinus surgery does not impair olfaction. *Am J Rhinol Allergy*. 2011; 25:125–127.