

Approach to diagnosis of vocal fold immobility: a literature review

Omayma E. Afsah

Unit of Phoniatrics, Department of ORL, Faculty of Medicine, Mansoura University, Mansoura, Egypt

Correspondence to Omayma Elsayed Afsah, MD, PhD, Unit of Phoniatrics, Department of ORL, Faculty of Medicine, Mansoura University, Mansoura, Egypt
Tel: +20 100 292 9720; Fax: 0020502263717; e-mail: omafsah@yahoo.com

Received 12 April 2014

Accepted 20 November 2014

The Egyptian Journal of Otolaryngology
2015, 31:78–91

Vocal fold immobility (VFI) is a sign of disease and not a final diagnosis. VFI can have a profound impact on a patient's quality of life. The most important objective in evaluating a patient with VFI is to exclude the existence of a treatable and potentially life-threatening primary disease as the cause of VFI. Thorough evaluation of these cases is mandatory for proper decision-making and planning of therapy. This paper addresses the established diagnostic workup for VFI and critically evaluates the contribution of different modalities to VFI diagnosis. To achieve this goal, a comprehensive review of the available literature regarding the diagnostic approaches to VFI was conducted. Eligible studies were identified by searching PubMed, Google Scholar, Springer, and ScienceDirect databases for relevant articles by combining the MESH heading term 'vocal fold immobility' with the words 'diagnosis, evaluation, paralysis, electromyography, imaging'.

Keywords:

assessment; diagnosis; fold; immobility; paralysis; vocal

Egypt J Otolaryngol 31:78–91

© 2015 The Egyptian Oto - Rhino - Laryngological Society
1012-5574

Introduction

Normal laryngeal physiology depends upon highly coordinated motor function, and disruption of this elegantly balanced system by vocal fold (VF) motion impairment may affect any of the vital laryngeal functions, including respiration, swallowing, phonation, and cough production [1]. VF mobility can be affected by disorders of the cricoarytenoid joint, the parts of the brain and nerves that supply the larynx, or the muscles of the larynx [2].

Vocal fold immobility (VFI) is the term that describes restricted movement of VFs secondary to mechanical fixation or neurological involvement. Mobility of the VFs may be decreased or absent, and it may be unilateral or bilateral. From the standpoint of etiology, choice of treatment, and prognosis, it is important to differentiate between hypomobility and immobility, as well as between unilateral and bilateral involvement [3].

VFI is a sign of disease and not a final diagnosis, and its exact cause should be actively investigated in all patients because its etiology determines its prognosis and management [4]. Studies [5–7] have suggested that nonlaryngeal neoplasms may be the most common cause of unilateral VFI.

Over 1500 studies on vocal fold paralysis (VFP) exist in the medical literature, although only a small percentage report on the diagnostic evaluation to investigate the underlying cause [8]. It is clinically important to diagnose the primary disease in cases of VFI because many of its potential causes, such as

symptom-free malignant tumors, can be fatal or may cause serious morbidity if detected late [9].

The diagnostic approach for evaluation of the patient with VFI differs among clinicians, and there is a lack of consensus regarding the most appropriate initial workup of these patients. MacGregor *et al.* [10] surveyed ENT surgeons in the UK and found great difference in the diagnostic evaluation of patients with unilateral VFI.

Ideally, the evaluation should not only detect or exclude the underlying etiology but should consider cost as well [11]. Terris *et al.* [12] surveyed otolaryngologists and found a significant difference in the cost of evaluation between those with less than 5 years of experience and those with more than 25 years of experience (\$2300 vs. \$300, respectively).

The purpose of the present paper was to critically address the diagnostic procedures of VFI and evaluate the contribution of different modalities to VFI diagnosis to provide a rational basis for the implementation of appropriate therapeutic intervention.

Anatomy of the vagus nerve

The vagus nerve leaves the medulla of the brainstem as several rootlets. These converge into a single root that leaves the skull through the jugular foramen. The vagus nerve presents two enlargements: a superior (jugular) ganglion caudal to the jugular foramen and an inferior (nodose) ganglion at the level of the hyoid bone. In the

neck, the vagus nerve has several branches that control the voice and speech mechanism. These branches are the pharyngeal nerve, superior laryngeal nerve (SLN), and recurrent laryngeal nerve (RLN) [5,6].

The right RLN leaves the vagus nerve at the anterior surface of the right subclavian artery and runs inferiorly, looping around the subclavian artery, and ascending medially in the tracheoesophageal groove. The left recurrent nerve branches more caudally from the vagus nerve on the anterior surface of the aortic arch. It passes inferiorly around the arch through the aortopulmonary window to ascend in the tracheoesophageal groove [7]. The left RLN has a longer intrathoracic course than the right nerve, coming into contact with the mediastinal surface of the left lung, continuing along the mediastinal lymph nodes, and finally looping around the aortic arch [13]. As each recurrent nerve ascends, it is closely related to the corresponding inferior thyroid artery [7].

Vocal fold paralysis

Etiology of vocal fold paralysis

VFP is usually classified by either the site of the lesions (supranuclear, bulbar, peripheral nerve, myoneural junctions, or laryngeal muscles) or the nature of the disorder (inflammatory, neoplastic, traumatic, postsurgical, systemic, or idiopathic) [14]. Lesions of the cortex or supranuclear corticobulbar pathways uncommonly affect the larynx. Lesions from the medulla to the muscle are more common and generally produce a flaccid paralysis [14].

VFP may be unilateral or bilateral, congenital or acquired [6,15]. On the basis of the level of the lesion, the etiology of VFP can be classified into the following.

Supranuclear lesions

Bilateral upper motor neuron lesions result in pseudobulbar palsy.

Nuclear lesions

The causes of nuclear lesions are vascular disease, neoplastic disease, motor neuron disease, polio, and syringobulbia. Lesions of the nucleus ambiguus result in ipsilateral palatal, pharyngeal, and laryngeal paralysis that is usually associated with affection of other cranial nerve nuclei, roots, and long tracts. The most common cause is occlusion of the posterior inferior cerebellar arteries resulting in a lateral medullary infarct (Wallenberg syndrome). When only the more cephalad portion of the nucleus ambiguus is

injured, laryngeal function is spared (palatopharyngeal paralysis of Avellis) [16].

High (proximal) vagal lesions

These refer to lesions from the nodose ganglion up (damage to the vagus nerve before it innervates the soft palate). Cranial nerves IX, XI, and XII travel with the vagus in its uppermost segment; therefore, lesions affecting the vagus superiorly usually (95%) affect one or all of these cranial nerves as well [17]. High vagal lesions include the following:

- (1) Posterior cranial fossa and jugular foramen lesions.

Examples include posterior fossa tumors (e.g. acoustic neuromas and meningiomas), tubercular meningitis, fracture of the skull base, nasopharyngeal carcinoma, and glomus tumors [18]. These lesions give rise to a number of syndromes including jugular foramen syndrome of Vernet (IX, X, and XI nerves affected), Schmidt's syndrome (X and XI nerves affected), Hughlings Jackson syndrome (X, XI, and XII nerves affected), and Collet–Sicard syndrome (IX, X, XI, and XII nerves affected) [16].

- (2) Suprahyoid neck lesions.

Cranial nerves IX, X, XI, and XII are all included in the contents of the suprahyoid carotid space (carotid sheath and adjacent structures). A wide range of abnormalities, including benign and malignant tumors, inflammatory processes, and vascular lesions, can result in vagal nerve involvement with subsequent VFP. Examples of these lesions include paragangliomas/glomus vagale, vagal schwannomas, and metastatic lymph nodes [19].

Low (distal) vagal lesions

These refer to lesions in the infrahyoid neck and mediastinum. Damage is below the level of the pharyngeal branch of the vagus and therefore the soft palate is spared. The vagus nerve in the carotid space can be affected by vagal schwannoma or neurofibroma. The close proximity of the RLN to the esophagus, trachea, and thyroid in the tracheoesophageal groove makes it vulnerable to injury secondary to pathologies involving these structures (such as esophageal and thyroid malignancies). The left RLN is longer than the right RLN and has a longer intrathoracic course, which makes it more vulnerable to injury secondary to mediastinal abnormalities (such as lung carcinoma, aortic aneurysm, and mediastinal lymphadenopathy) [19,20].

Myoneural junction diseases

Myasthenia gravis causes bilateral weakness of the intrinsic laryngeal muscles. Sometimes, muscles supplied by the vagus nerve are the first to be affected by this disease. Most often, myasthenia gravis produces the full complement of flaccid dysarthria [21].

Disease of muscle

Muscular dystrophies or myopathies can cause flaccid dysphonia [21].

Pathophysiology of vocal fold paralysis

Patterns of injury

The RLN contains 500–1000 motor axons, and all are myelinated [22]. The nerve trunk is a collection of fascicles. The epineurium covers the entire nerve, whereas the perineurium surrounds individual fascicles, and the endoneurium surrounds the nerve fibers [23].

Nerve injuries are categorized according to morphological alterations, nerve functionality, and the ability for spontaneous recovery. There are two commonly used classification schemes for peripheral nerve injury: the Seddon [24] and the Sunderland [25] (Table 1). The Sunderland classification is more complex, but more useful.

Seddon [24] divided injuries into neurapraxia, axonotmesis, and neurotmesis. Neurapraxia results simply in a conduction block along the nerve fiber. The macroscopic mechanism is generally compression or excessive stretching. Axons are nonfunctional because of segmental demyelination, without axon disruption or Wallerian degeneration. In axonotmesis, the nerve fiber and its myelin sheath are cut, without interruption in the neural envelopes. It is generally caused by violent compression or stretching. Nerve conduction is interrupted and the nerve fiber undergoes retrograde

degeneration (Wallerian degeneration) beginning within 24 h of injury. Neurotmesis is the interruption of nerve fibers, myelin, and nerve envelopes due to nerve section or severe crush (e.g. at least the endoneurium and the perineurium, in crush injury). Wallerian degeneration occurs [27].

Sunderland [25] divided axonotmesis into grades 2–4 depending on the extent of nerve affected by axonal injury. Given that axonotmesis represents a broad spectrum of injury, the functional outcome can vary but is generally with little synkinesis [28].

Recurrent laryngeal nerve regrowth

For neurapraxic lesions, spontaneous full recovery follows remyelination by Schwann cells. This occurs after several days to several weeks [27]. For axonotmesis with intact endoneurium, recovery ensues because regenerating axons enter their native endoneurial tubes leading back to original target muscles. In more severe injuries, reinnervation may be inappropriate, inadequate, or nonexistent. Axons may grow in a misdirected manner. Adductor fibers may innervate abductor muscles and vice versa. The simultaneous contraction in antagonist muscles that results is called 'synkinesis'. An inadequate number of regenerating axons successfully reach their endoneurial conduits. Voluntary contraction is never attained, but reinnervation is sufficient to prevent denervation atrophy. Regrowth of the envelopes may occur in a chaotic manner, resulting in a neuroma. Muscle degeneration is thought to be complete after 2–3 years [29].

Unless a result of severe trauma like transection, each case differs in terms of degree of neural impairment, and features a mix of injury types among its nerve fibers with variable degrees and patterns of reinnervation [30].

Thus, VFP is probably best considered as a continuum of neurogenic dysfunction encompassing partial denervation, complete denervation, and variable degrees and patterns of reinnervation. This has two important clinical implications. First, it accounts for variability in the position of the paralyzed VF. As stated by Kotby *et al.* [31], the immobile VF may adopt several positions not only dependent on the type of the nerve muscle affection but also dependent on the degree of that affection, and on the anatomical peculiarities of the muscles and joints. Second, it accounts for the general trend for the voice to improve over time in unilateral vocal fold paralysis (UVFP). Reinnervation likely acts to restore or preserve muscle bulk and tone, leading to a voice close to normal, although the VF itself remains immobile [32,33].

Table 1 The Seddon and Sunderland classification of nerve injury [26]

Seddon	Process	Sunderland
Neurapraxia	Segmental demyelination	First degree
Axonotmesis	Axon severed but endoneurium intact (optimal circumstances for regeneration)	Second degree
Axonotmesis	Axon discontinuity, endoneurial tube discontinuity, perineurium and fascicular arrangement preserved	Third degree
Axonotmesis	Loss of continuity of axons, endoneurial tubes, perineurium and fasciculi, epineurium intact (neuroma in continuity)	Fourth degree
Neurotmesis	Loss of continuity of entire nerve trunk	Fifth degree

Assessment of vocal fold paralysis

Among the patients who present with VFP as the initial sign, the frequency of detection of a malignant tumor as the primary lesion is relatively high. Hence, it is clinically important to diagnose the primary disease in cases of VFP [34].

On the basis of the protocol for assessment of voice disorders [35], diagnosis of VFP proceeds through the following steps: elementary diagnostic procedures, clinical diagnostic aids, and additional instrumental measures.

Elementary diagnostic procedures

Key features of the history

A thorough history of complaints has to be obtained, including voice, swallowing, and breathing symptomatology. The voice can vary from simple vocal fatigue in mild or well-compensated cases to almost complete aphonia in severe cases.

Swallowing difficulties are often encountered, specifically aspiration of liquids in the acute phase of VFP, but complete compensation is said to develop later [36]. Some dysphagia for solids may also be present, especially in brainstem or high vagal injuries, due to the concomitant denervation of the pharyngeal constrictors. Risk of aspiration is heightened in these instances as well, because of the loss of ipsilateral laryngeal sensation from SLN involvement [37].

Kashima [38] reported that over half of the patients with UVFP suffer from at least mild dyspnea. In bilateral abductor paralysis, the most serious symptom is respiratory obstruction, which is evidenced by stridor, dyspnea, retraction, and nasal flaring [15].

A complete medical history should be taken, including a thorough history of neurologic or rheumatologic disease, previous surgeries, prolonged intubations, trauma, pulmonary symptoms suggestive of tuberculosis or malignancy, and exposure to neurotoxic agents like solid tumor chemotherapy (e.g. vincristine, vinplatin, and cisplatin) [39].

Auditory perceptual assessment

The abducted VF in UVFP results in a voice quality that is characterized by breathiness, diplophonia, decreased loudness, reduced phonation duration, and a restricted pitch range [40]. The voice is breathy and weak because of incomplete glottic closure and subsequent air escape. The voice may also have a watery or 'gurgly' quality if secretions are retained in the pyriform sinus, as is typical in high vagal injuries. Diplophonia may occur when the immobile VF is at a different tension from that of

the contralateral side, resulting in each VF vibrating at a different frequency. Supraglottic hyperfunctional compensation is common, leading to irregular, low pitched voice. In contrast, other patients, often women, may develop an unnaturally high-pitched voice that is breathy in quality, referred to as a 'paralytic falsetto'. It is a common finding in patients with RLN paralysis caused by compensatory contraction of the ipsilateral cricothyroid muscle, which remains innervated. The presence of this phenomenon suggests an intact SLN [41].

The phoniatrician should also listen for disturbances in articulation, prosody, and resonance, which would raise suspicion for a proximal neurologic injury or underlying neurologic disorder [42].

Physical examination

General, neurological, chest, and heart examinations should be conducted. A thorough and systematic neurologic examination of the head and neck should be performed for all patients with UVFP [8]. The neck should be carefully examined for thyroid enlargement, masses, lymphadenopathy, and surgical scars. Examination of cranial nerves should be done with special attention to the spinal accessory and hypoglossal nerves, which share the jugular foramen with the vagus. Involvement of these adjacent cranial nerves warrants a thorough radiographic evaluation of the base of the skull. Vocal tract examination to determine the patient's gag reflex, palatal elevation, and uvular deviation to evaluate the vagus nerve function are carried out. Palatal paralysis (the uvula deviates to the intact side) in combination with ipsilateral VFP may indicate a 'high' vagal lesion. Examination of tongue mobility is also important for possible associated hypoglossal nerve lesions [37]. Indirect mirror laryngoscopy should be performed for identifying gross VF mobility and pooled secretions.

Clinical diagnostic aids

- 1 Documentation of auditory perceptual assessment by high-fidelity video recording.
- 2 Documentation of visual assessment using rigid laryngoscopy or flexible transnasal laryngoscopy.

Laryngeal examination is best accomplished with transnasal flexible laryngoscopy, because this enables observation of pharyngeal and laryngeal motor function. Although rigid laryngoscopy enables excellent visualization of the endolarynx, the pharynx and soft palate are not examined in as much detail with this technique and tongue traction required may alter the laryngeal posture and lead to inaccurate assessment

of laryngeal function. The examiner should look for asymmetric movement, VF bowing, horizontal and vertical position of the VFs, glottic gap on phonation, presence of prolapsed arytenoids, and supraglottic hyperfunction.

The most consistent glottic findings in UVFP are a shortened and bowed VF [32]. The position of the paralyzed VF carries no significance with respect to the site of injury or prognosis. The examiner should take care not to be misled by small amounts of VF motion that may be caused by the interarytenoid muscle still partially innervated from the contralateral nerve or by an intact cricothyroid muscle [37]. In such cases, there may appear to be slight adduction on phonatory effort, but the VF will not abduct from its position of rest.

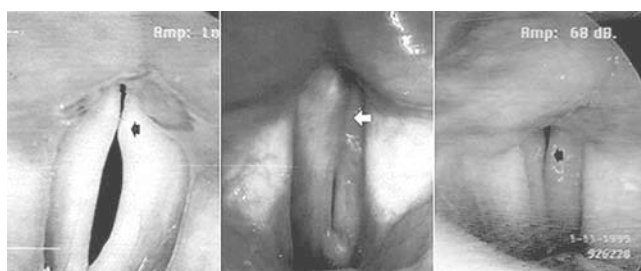The vertical level of the paralyzed VF may be either lower or higher than the normal VF or it may show the same horizontal level as does the normal VF during phonation (Fig. 1) [43]. This finding should be considered when planning phonosurgery to correct dysphonia due to UVFP.

In UVFP, the glottal gap may be of two principal configurations: spindle-shaped (involving principally the membranous portion of the VF) or V-shaped (marked by greater distance between the vocal processes of the arytenoids cartilage).

The presence of a prolapsed arytenoid suggests profound denervation with loss of muscular support for the cartilage. The reasons for this malposition include:

- (1) Residual activity of intrinsic laryngeal muscles unaffected by the paralysis,
- (2) Passive action of ligaments within the larynx,
- (3) Reinnervation of the affected laryngeal muscles in the form of synkinesis, and

Figure 1



The contact nature between paralyzed and normal vocal folds (VFs) during phonation. Equal contact level (left) and higher normal VF overlapped on lower paralyzed VF (middle) and lower normal VF (right). Arrows show paralyzed VF [43].

- (4) Restriction of joint movement possibly by intrajoint inflammation and fibrosis [44].

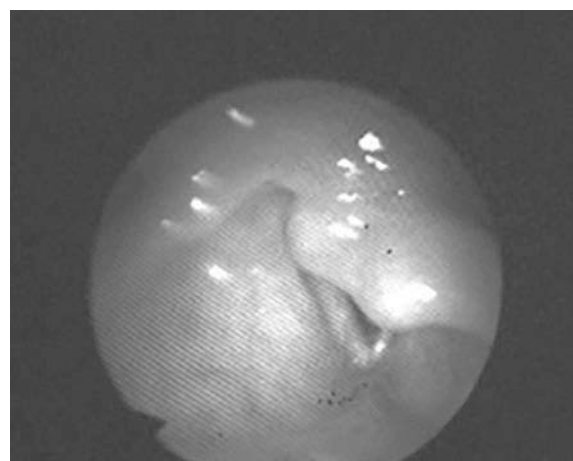
This overhanging, anteriorly displaced arytenoid cartilage is sometimes mistaken for an arytenoid cartilage dislocation (Fig. 1). Electromyography (EMG) data from patients with an immobile VF accompanied by an 'overhanging' arytenoid cartilage, however, will almost always show complete denervation or poor reinnervation of the thyroarytenoid (TA) muscle. Therefore, in nontraumatic cases, anterior displacement or an overhanging, sagging arytenoid cartilage should not raise the suspicion for arytenoid dislocation (Fig. 2) [45].

In longstanding UVFP, supraglottic hyperfunction may obscure visualization of the VFs. Maneuvers such as humming can serve to relax the ventricular folds (unloading the larynx) to permit a more thorough evaluation of the glottis closure [46].

SLN damage is tricky to identify. The controversial list of laryngoscopic signs include an obliquely shaped glottis, rotation of the posterior commissure toward the weak side, lower VF height on the involved side, and bowed, thin and shortened VF.

In addition to the larynx, the following structures are examined during flexible laryngoscopy: the soft palate for velopharyngeal closure; and the tongue base, pharynx, and hypopharynx for asymmetry, abnormal spontaneous movements, and pooling of secretions in the pyriform sinus and vallecula on the affected side [47]. Loss of sensation in the hypopharynx secondary to SLN compromise can result in pooling of

Figure 2



Laryngoscopic view of a patient with left vocal fold immobility and an overhanging arytenoid. Laryngeal electromyography confirmed that the immobility was caused by a neuropathic process, and not by cricoarytenoid joint dislocation or subluxation [45].

secretions in the pyriform sinus and delayed relaxation of the cricopharyngeus (Fig. 3).

3- Stroboscopy and videostroboscopy

Videostroboscopy has been the standard tool for the evaluation of VF vibration in patients with UVFP [48]. During VF vibration observed in stroboscopy, the denervated side shows wide undulating amplitudes like the fluttering of a flag in the wind (although amplitude could be radically reduced) and a loss of mucosal waves. Asymmetry in phase and amplitude is obvious between the normal and denervated side [49].

Studying the mucosal waves by means of stroboscopy may be recommended for monitoring the course of laryngeal paralysis. When the VFs were shown to be denervated in the EMG, there was a complete lack of mucosal waves [50]. A return of the mucosal waves was always correlated with signs of reinnervation in the EMG. Most frequently, however, the VFs stayed immobilized for the entire observation time of more than 1 year, despite the fact that the EMG showed good reinnervation and the vibratory pattern was completely normalized with excellent mucosal waves. Fex and Elmqvist [50] explained this finding by misdirected reinnervation [49].

Sercarz *et al.* [51] stated that stroboscopy cannot reliably distinguish RLN paralysis from vagal paralysis. They also stated that, in VFP, the mucosal wave is always affected but not invariably absent in RLN and vagal paralysis. They explained the absent mucosal waves in some patients by poor glottic closure that reduced the degree of VF contact, decreasing the ability of stroboscopy to detect the very subtle mucosal wave that generally occurs on the paralyzed VF.

4- High-speed laryngeal imaging

High-speed laryngeal imaging has evolved as a method of laryngeal visualization that overcomes many of the

limitations of videostroboscopy [52–54]. A method for automatic diagnosis of VFP has been developed by use of image analysis technology based on high-speed imaging [55]. Although high-speed imaging offers many exciting possibilities in the evaluation of dysphonic patients, the expense of the equipment prevents widespread use in everyday practice, and its clinical utility in VF motion impairment remains to be seen. Certainly, in most cases of UVFP, standard flexible laryngoscopy is adequate for diagnosis and treatment planning. Techniques such as videostroboscopy and high-speed imaging may be helpful for evaluation of more subtle cases of VF paresis and for monitoring the vibratory function of the VFs before and after treatment [56].

5- Videokymography

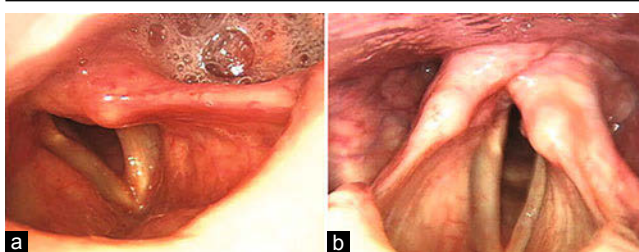
Videokymography (VKG) is a high-speed method for examination of the VF vibrations. The major advantages of VKG over high-speed imaging systems are lower cost, excellent spatial resolution, excellent image rate, unlimited duration of recordings, and fewer data to be stored and processed [57]. VKG findings in VFP include the following: a value of zero for closed phase and closed quotient; increase in open phase; increased opening and closing time of the paralyzed VF; decreased amplitude on the paralyzed VF; asymmetry in amplitude and in the timing of opening and closing phases [58]. The disadvantages of VKG, compared with high-speed imaging systems, arise mainly because only a single image line is monitored in VKG [57]. To compensate for the lack of a full image, it appears useful to use VKG as a complementary method to videolaryngostroboscopy (Fig. 4).

6- Electroglottography

Electroglottography (EGG) contributes information about the quality and duration of VF contact in patients with VFP and allows documentation and objective evaluation of consecutive examinations [59]. In patients with VFP, at least one of the following characteristics of EGG waveforms can be observed: prolonged closing phase, shortened opening phase, and prolonged open phase (Fig. 5) [60].

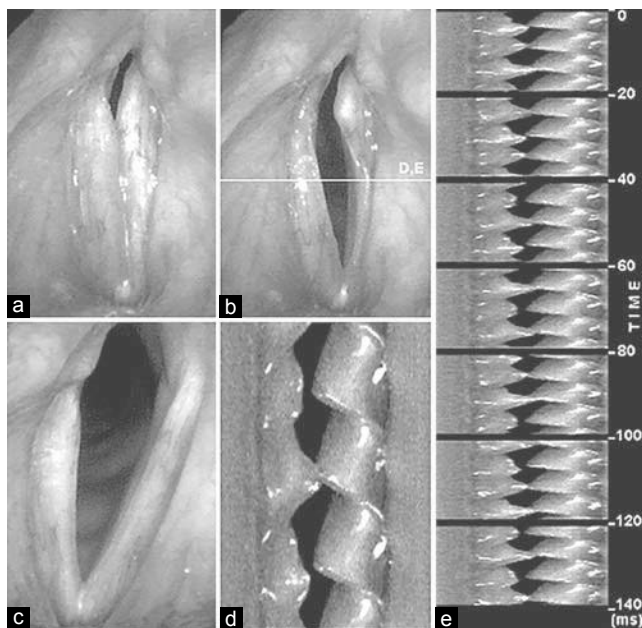
Zagólski [59] indicated that % irregularity (which is a frequency perturbation measure) best represents the changes in VF function in elderly individuals with VFP. Mueller [61] stated that EGG waveforms recorded in patients with VFP should be interpreted with great caution, particularly in elderly individuals, who may have considerable vocal perturbations even when VF mobility is unimpaired.

Figure 3



Variable laryngoscopic findings for two individuals with left vocal fold paralysis. Laryngoscopy for patient A (a) reveals anterior displacement of the arytenoid, flaccidity of the true vocal fold (VF), and salivary pooling in the left pyriform sinus. In contrast, patient B (b) has a fairly upright arytenoid with atrophic VF with only minimal flaccidity [1].

Figure 4



A male patient, aged 78 years, suffering from right vocal fold paralysis. (a) Laryngoscopic image at the phase of maximally closed glottis. A glottal gap remains in the posterior part. (b) Laryngoscopic image at the phase of maximally open glottis. The horizontal line marks the recording position for the videokymography (VKG) images (d) and (e). (c) Vocal folds (VFs) during breathing. The left VF is fully abducted. The right paralyzed VF remains in the medial position. (d) VKG: single image revealing the vibration of the VFs in detail (total time displayed: ca. 18 ms). Irregularities in the vibration are apparent especially on the right paralyzed VF. The irregularities are related to dysphonia of this patient. The left VF shows strong mucosal waves, which follow the opening movement and propagate laterally over the surface of the VF. (e) Sequence of seven VKG images monitoring the vibration of the VFs during a time interval of 140 ms. The third VKG image (beginning at 40 ms) corresponds to the image (d) [57].

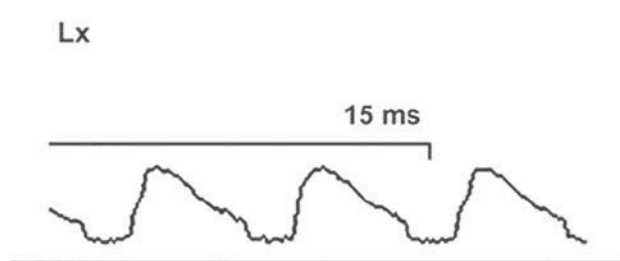
Owing to the lack of generally accepted norms for the interpretation of EGG waveforms, Zagólski [59] mentioned that the data and waveforms should be analyzed and compared for each individual and always related to other clinical data for that person.

Additional instrumental measures

A- Acoustic and aerodynamic measures

The acoustic and aerodynamic measurements provide an objective qualification of voice in patients with UVFP [62]. Eskenazi *et al.* [63] compared six acoustic parameters with perceptual evaluation by experienced jury listeners using the GRBAS method on a scale from 1 to 7. Regression analysis showed that jitter was well correlated with grade G (overall dysphonia) and grade R (roughness), whereas signal-to-noise ratio was correlated with grade B (breathiness). In their study on patients with UVFP, Hartl *et al.* [62] stated that breathiness was best correlated with airflow measurements.

Figure 5



An example of an electroglottography waveform recorded in a patient with right vocal fold paralysis. Prolonged closing and opening phase. Duration of vocal fold (VF) contact differs between the cycles. This waveform shows periodicity but cycles of unequal length, amplitude, and contact irregularity reflecting abnormal VF contact patterns [59].

The acoustic findings that were observed in patients with VFP included reduction of dynamic range both in loudness and frequency, loss of high-frequency harmonics and high-frequency formants on the spectrogram, increased aperiodicity of the vibratory period (increased jitter), and increased noise-to-harmonic ratio [42].

The aerodynamic findings observed in patients with VFP included reduction of maximum phonation time (generally < 10 s) and increased mean airflow. Subglottic air pressure is usually diminished, the person being unable to raise the pressure below the VFs because of the poor glottic closure [42].

The major advantage of the acoustic and aerodynamic measurements is that they permit a longitudinal follow-up of each case by using these measures in pretherapy and post-therapy evaluations, whether the therapy was voice therapy or surgery. Netterville *et al.* [64] noted that postoperative measurements should be performed after about 3 months from surgery.

Yu *et al.* [65] stated that the use of a single acoustic or aerodynamic parameter for objective assessment of dysphonia is not appropriate. Acoustic measurements cover only part of the information contained in perceptual analysis. For this reason several teams have proposed a multiparametric approach comprising acoustic and aerodynamic parameters to enhance the scope of data.

B- Laboratory examinations

Laboratory testing has been described as part of the evaluation of patients with UVFP without a clear etiology. Such tests include rheumatoid factor, Lyme titer, erythrocyte sedimentation rate, antinuclear antibody, angiotensin-converting enzyme, syphilis testing, and blood chemistry analysis including

glucose [8]. Although results from these studies may be abnormal for medical diseases associated with UVFP, no studies support their routine use in the absence of a high clinical suspicion for a particular disease [12].

C- Laryngeal electromyography

Approach

For standard clinical purposes, the percutaneous approach proved to be the most suitable in the hands of many investigators [66,67].

Muscles investigated

The TA and the cricothyroid muscles on each side are investigated, as a representative of the recurrent and SLN-muscle systems. Kotby and Haugen [66] suggested that the first sitting of laryngeal electromyography (LEMG) should include recordings from the posticus muscle [31].

Activities recorded

EMG recordings from the laryngeal muscles are obtained at rest (during quiet breathing), during deep breathing, and during phonation at comfortable pitch and loudness levels. EMG recordings also are obtained with different sphincteric functions of the larynx (straining, coughing, and swallowing). The latter recordings are usually done last to avoid displacement of the laryngeal electrodes [31].

Guidelines for interpretation of laryngeal electromyography

- (1) *At rest:* The constant background postural activity of the laryngeal muscles makes it hard to interpret muscle activity triggered by inserting the needle. Equally, detecting pathological spontaneous activity is much more difficult than in most other muscles. At the same time, a lesion of the nerve also reduces the background activity and thus often makes the interpretation easier than in physiologically innervated laryngeal muscles [68].
- (2) *Interference pattern:* In laryngeal movements, unlike peripheral skeletal muscles, there is little chance for gradation of the degree of contraction. Accordingly, the comparison between partial versus full interference patterns is difficult. In unilateral neurogenic lesions of the larynx, the detection of a significant difference in the interference pattern in identical muscles on both sides of the larynx can be considered as pointing to a neuropathic lesion of the muscle.
- (3) Motor unit action potentials (MUAPs) of laryngeal muscles are normally biphasic or triphasic, of short mean duration (2–4 ms), and of small amplitude (150–800 μV) [31].

Value of laryngeal electromyography in vocal fold immobility

1- Diagnosis

Paralyzed vocal fold versus fixed vocal fold

LEMG is an important diagnostic tool for this purpose. Timing of LEMG should be at least 14 days after onset of immobility, to enable Wallerian degeneration to occur and spontaneous activity to emerge, and is most useful within 6 months of injury [69]. Normal electrical activity patterns of the LEMG support a diagnosis of arytenoid fixation [70], whereas abnormal electrical activity patterns, including patterns of denervation or reinnervation, support the diagnosis of VFP [71].

The following are the signs of denervation:

- (1) Spontaneous activity during rest. Spontaneous activity can include fibrillation potentials, increased insertional fibrillations (insertional activity), myotonic discharges, complex repetitive discharges, fasciculations, and positive sharp waves.
- (2) Spontaneous activity may occur only 10–14 days after the injury and such spontaneous activity implies that the muscle is degenerating or that the nerve has been injured and that the injury is ongoing.
- (3) Broadening of MUAPs.
- (4) Reduced recruitment during volitional activity. Recruitment is defined as the activation of motor units with increasing strength of voluntary muscle contraction. It reflects the number of MUAPs identifiable during increasing activation when performing tasks like voicing. Preferentially, individual action potentials are evaluated in correspondence with minimal activation [68].

The detection of spontaneous fibrillation potentials and the reduction in the number of motor units on activation (reflected through interference patterns) are some of the most reliable features in the diagnosis of neuromuscular pathologies (especially neurogenic lesions). These features cannot be used reliably in clinical LEMG. Accordingly, one is apt to rely heavily on the features (parameters) of the MUAPs. These MUAPs are known to show an increase in mean duration and voltage in cases of neurogenic lesions [31].

The following are the signs of reinnervation:

- (1) Polyphasic units are large-amplitude units with five or more baseline crossings of increased duration compared with normal units. Nascent units are defined as low-amplitude units with increased number of baseline crossings and do not meet the amplitude or duration criteria of polyphasic units. They can be observed at the

earliest 2 months after onset and indicate ongoing reinnervation (recent injury) [72].

- (2) In later stages (5–12 months after onset of nerve degeneration), spontaneous denervation potentials progressively disappear. The polyphasia and duration decrease but the amplitude increases, producing a giant wave. These large-amplitude motor units indicate an old but stable peripheral nerve injury [73].

LEMG interpretation is based upon recruitment, waveform morphology, and spontaneous activity. These variables offer five interpretations (Table 2).

Upper motor neuron versus lower motor neuron

In the first 3–6 weeks after an upper motor neuron injury, there may be abnormal spontaneous activity. After that time, examination shows electrical silence at rest with no abnormal spontaneous activity. However, EMG is neither sensitive nor specific in the diagnosis of upper motor neuron lesions [74].

Vagus versus recurrent laryngeal nerve

Comparison of findings between the cricothyroid and the TA indicates the site of lesion. If there are neuropathic findings in both muscles, a high injury is suspected, and imaging of the skull base and central nervous system is warranted. If there are abnormalities in only the TA, the RLN is implicated, directing attention to the lower neck and mediastinum [74].

2- Prognosis

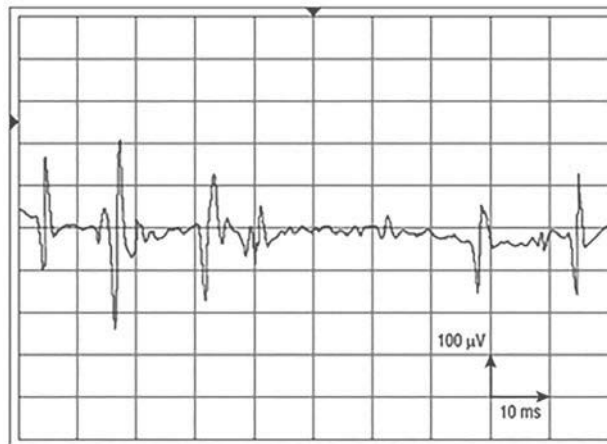
For neurapraxia, the diagnostic criterion in LEMG is the detection of a rarefied recruitment pattern or of single action potentials during voluntary contraction without pathological spontaneous activity (Figs. 6 and 7). Axonotmesis should be suspected if spontaneous activity, indicating neural degeneration, is detected (Figs. 8 and 9). This classification includes a

Table 2 Interpretation and classification of laryngeal electromyography findings [71]

Classes	Spontaneous activity	Recruitment of motor units	Individual motor unit morphology	Interpretation (prognosis)
I	Absent	Normal	Normal MUAPs	Normal
II	Absent	Reduced	Small polyphasic MUAPs	Reinnervation
III	Absent	Reduced	Very large MUAPs	Old injury
IV	Present	Reduced	Polyphasic MUAPs	Equivocal
V	Present	Absent	Fibrillations, etc.	Denervation

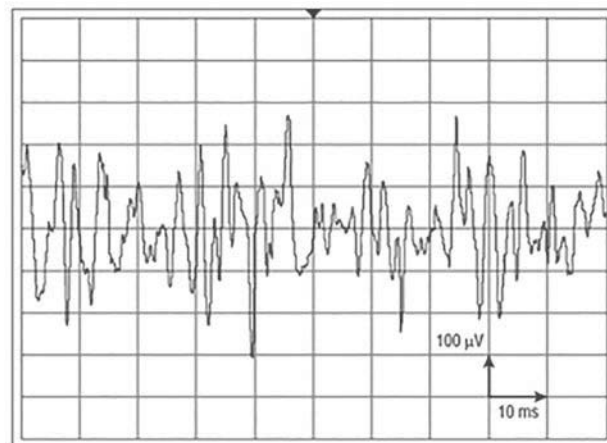
MUAP, motor unit action potential.

Figure 6



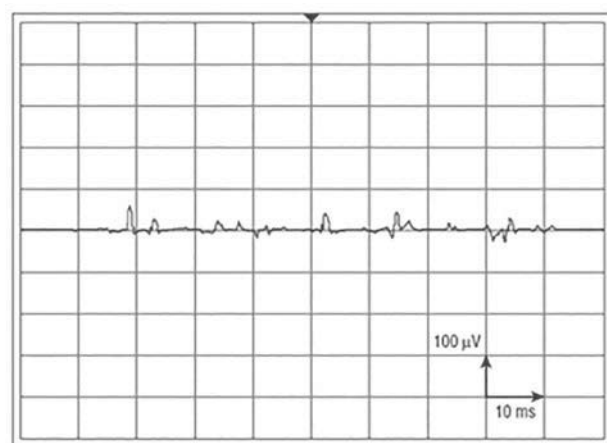Neurapraxy. Note the extremely rarefied firing pattern on phonation but no spontaneous activity at rest [75].

Figure 7



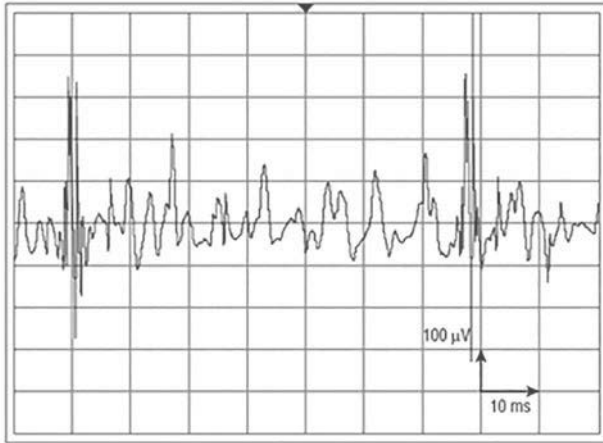
Neurapraxy. Note the slightly reduced recruitment on phonation, with no spontaneous activity at rest [75].

Figure 8



Axonotmesis. Spontaneous fibrillation activity at rest, with minimal recruitment on voluntary action [75].

Figure 9



Polyphasic, prolonged action potentials with giant amplitudes, indicating reinnervation 4 months after nerve injury [75].

certain level of prognosis on recovery, as neurapraxia is most likely to recover completely within 8–12 weeks, whereas axonotmesis is thought to have only a poor chance of recovery to a functional level [76]. If reinnervation occurs following axonotmesis, it is usually associated with sequelae, such as synkinesis, due to neuronal misdirection [68]. In neurotmesis, EMG shows fibrillation potentials and then electrical silence.

For evaluation of synkinetic reinnervation, the interference pattern of the TA muscle is evaluated during vowel vocalization and then during sniffing. If synkinesis has occurred, there will be an electrical signal with both tasks [68].

EMG studies can detect early stages of recovery of partial laryngeal nerve lesion far before clinical detection of return of movement in the immobile VF. The increase in the number of MUAPs with an increasing percentage of polyphasic potentials denotes early muscle reinnervation [66].

A meta-analysis including 503 patients that evaluated the utility of LEMG for accurate prediction of prognosis of motion recovery found that the LEMG was able to predict poor prognosis with 91% accuracy but was only able to predict good recovery 56% of the time [69].

The LEMG has its limits. Clinical experience has shown that the results of LEMG are often inconclusive. Fibrillation potentials (denervation pattern) are difficult to detect because of competing noise from neighboring muscles and because of the small size of the laryngeal muscles. A majority of patients with RLN paralysis do not have electrical silence in the early days after nerve trauma, because the nerve lesion

is incomplete. Normal interference patterns can be recorded, whereas laryngeal motion is absent for the same reason. Patients with reduced interference pattern or with polyphasic potentials certainly have a nerve lesion, but unfortunately the likelihood of recovery cannot be predicted. If recovery has to take place, it is usually observable in the first 3 months and rarely after 1 year following onset of paralysis [42].

D- Radiologic studies

When a clear-cut temporal relation exists between surgical iatrogenic trauma and VFP, no additional radiologic workup is necessary. When no cause can be found for the VFP, imaging studies are essential [12].

Chest X-ray versus computed tomography scan

Terris *et al.* [12] found that chest X-ray (CXR) was the most useful diagnostic tool as it identified a diagnosis in more than one-third of patients with previously undiagnosed UVFP. Altman and Benninger [11] stated that CXR is a useful screening study, but it is not sufficient for the full evaluation of VFP. In their study, there were three cases in which history, examination, and CXR failed to identify the etiology. In all of these cases, a computed tomography (CT) scan of the neck identified the etiology: esophageal cancer in one case and thyroid cancer in the other two. In the study by Glazer *et al.* [7], CXR missed 13 of 18 mediastinal lesions causing left UVFP, whereas history, examination, and CXR identified all lesions causing right UVFP. Song *et al.* [77] found that, of 19 CT-detected malignant neoplasms, eight were not detected on CXR. Five of them were associated with left-side paralysis and showed a metastatic node in the aortopulmonary window on CT. The other three were associated with right-side paralysis, and the CT scan detected one case of right apical lung carcinoma and two cases of metastatic nodes in the right upper paratracheal region. The proposed algorithm by Altman and Benninger [11] was to use CXR as a screening tool; if this is negative, then a contrast-enhanced, 3-mm section, CT scan of the neck should follow. Their description CT of the neck extends from 'the posterior fossa/skull base through the aortic triangle' on the left and to the 'thoracic inlet' on the right, making it a CT along the course of the vagus and RLN, and not purely a neck CT [8].

Furukawa *et al.* [34] also advocated a 'side-specific' evaluation that included ultrasound of the neck and CXR; if these initial tests were not revealing, a chest CT should follow for left-sided paralysis only. The same authors also noted a sex distinction with a higher rate of lung and esophageal cancer in male

patients and for thyroid cancer in female patients; this sex distinction became part of their paradigm with only male patients undergoing contrast esophagrams as a follow-up to the ultrasound and CXR for right-sided paralysis.

Neck ultrasonography

High-resolution ultrasonography can evaluate the thyroid gland, supraclavicular region, the entire jugular chain, and the cervical vagus nerve. It is useful for detecting subclinical neoplasia causing UVFP. Some thyroid tumors have deep location in the posterior part of the thyroid lobe, resulting in UVFP being the initial presentation rather than a palpable anterior neck mass.

Neck ultrasonography is the most sensitive and accurate imaging study for the differential diagnosis of thyroid tumors. If a suspicious tumor lesion is noted, fine-needle aspiration with cytologic examination should be performed immediately under ultrasound guidance [78].

Computed tomography versus magnetic resonance imaging

Jacobs *et al.* [79] have suggested a segmented approach to clinical–radiological examination of vagus nerve dysfunction, based on proximal and distal lesions. CT is the first-line choice for imaging investigation of distal vagus neuropathy. Contrast-enhanced images from the hyoid bone to the mediastinum should be obtained. In contrast, MRI is the first-line choice for imaging investigation of proximal vagus neuropathy. It is useful in patients with associated palatal or pharyngeal paralysis and/or other cranial neuropathies. In such cases, gadolinium-enhanced MRI of the posterior cranial fossa should extend from the medulla to the hyoid bone. If MRI is unavailable, thin-section, contrast-enhanced CT can be used, although brainstem lesions may not always be detected on CT scans [76].

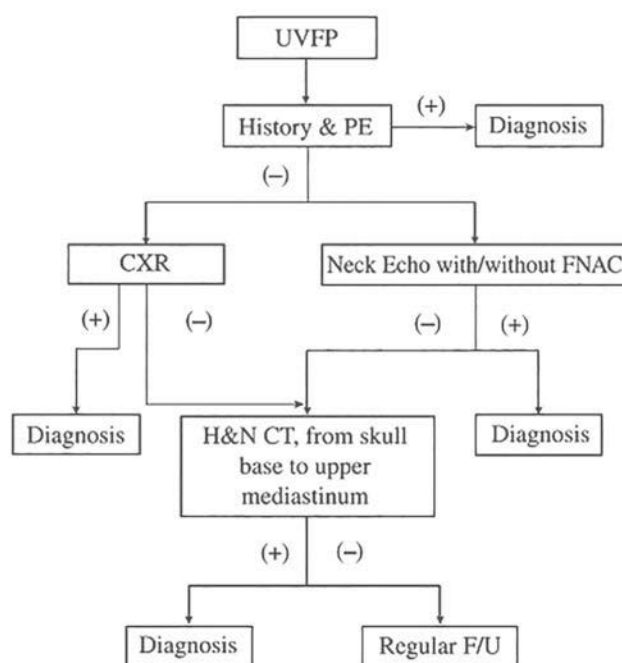
Summary of diagnostic imaging

It is difficult to make a practice recommendation on radiographic investigation of idiopathic VFP based on scientific evidence. The importance and potential superiority of CT scanning was advocated by some authors (e.g. Glazer *et al.* [7] and Song *et al.* [77]). Several other authors advocated that patients with UVFP be triaged to different imaging modalities based on the side of the lesion (e.g. Altman and Benninger [11] and Furukawa *et al.* [34]) or the clinical suspicion of the ordering physician (e.g. Jacobs *et al.* [79]). This clinical distinction was made on clinical grounds

such as accompanying cranial polyneuropathy. The advantage of the ‘proximal’ and ‘distal’ distinction may have its basis in the preference for MRI in skull base and intracranial imaging [8]. Ko *et al.* [4] proposed an algorithm for patients with UVFP (Fig. 10).

Richardson and Bastian [76] outlined a cost-effective and time and labor-efficient method for the clinical evaluation of VFP, including a focused history, vocal capability assessment to find deficits in the function of the palate, pharynx, and larynx, and, finally, an intense examination under topical anesthesia to demonstrate these deficits. In essence, it is the endoscopic version of a radiographic study from the skull base through the aortic arch. This method is streamlined as compared with prior protocols for evaluation of VFP, because it directs the necessary further workup according to the likely site of the lesion as indicated by the extended physical examination, and can be conducted entirely in the physician’s office. Radiographic workup should include CT of the skull base through the upper mediastinum if solely an RLN paralysis is present; it should include MRI of the skull base if high vagal signs and symptoms are present. If MRI is negative, CT may also be needed for complete evaluation. Neurologic signs that are not all ipsilateral require MRI of the brain and consultation with a neurologist. Esophageal obstruction combined with VFP mandates evaluation with esophagoscopy or an esophagram.

Figure 10



The proposed algorithm for patients with unilateral vocal fold paralysis (UVFP) [4]. PE, physical examination; CT, computed tomography; CXR, chest X-ray; FNAC, fine-needle aspiration with cytologic examination; FU, follow-up; H&N, head and neck.

E- Formal evaluation of swallowing

Modified barium swallow is the recommended method for evaluation of swallowing complaints, although flexible endoscopic evaluation of swallowing (FEES) and FEES with sensory testing (FEESST) have emerged as techniques that enable safe and convenient evaluation of swallowing that can be performed in the office [47]. Patients with UVFP frequently complain of dysphagia, particularly aspiration of liquids. A persistent glottic gap, associated sensory deficits, pharyngeal weakness, and delayed relaxation of the cricopharyngeus muscle may all contribute to dysphagia in UVFP cases [1].

In the study by Jang *et al.* [80], patients with VFP of central etiology showed a higher incidence of penetration and aspiration as compared with patients with peripheral etiology. In addition, they also demonstrated other oral and pharyngeal phase swallow problems — for example, delayed triggering of pharyngeal swallow, reduced pharyngeal peristalsis, and cricopharyngeal dysfunction.

Differential diagnosis of vocal fold paralysis Dislocation/subluxation of the cricoarytenoid joint with ankylosis

It is infrequent but presents following medical instrumentation used on the larynx and esophagus, and because of external neck trauma. Subluxation is joint dislocation with some remaining contact of the joint surface. Laryngoscopy is the most common first step in diagnosis. Clues that can raise the suspicion of an arytenoid cartilage dislocation when evaluating unilateral VF mobility include arytenoid cartilage edema, difference in VF level, and absence of a ‘jostle sign’, which is a brief lateral movement of the arytenoid cartilage on the immobile side during glottic closure caused by contact from the mobile arytenoid [81].

Disparity in height between the vocal processes is much easier to see in slow motion under stroboscopic light at various pitches. A posteriorly dislocated arytenoid results in a high vocal process and a stretched VF. An anterior dislocation results in a low vocal process and a short VF. Ascertaining the direction of dislocation is difficult, but critical, because it will affect the technique of reduction [82].

Because none of the above is pathognomonic for arytenoid cartilage dislocation, a high degree of suspicion and further diagnostic testing are needed to confirm this entity. Alexander *et al.* [83] reported the usefulness of helical CT in patients with arytenoid dislocation. Helical CT not only significantly reduces the time necessary to study the larynx but enables

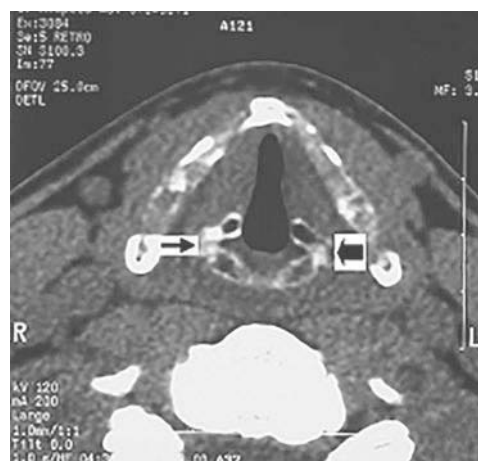
one to perform multiple high-resolution multiplanar reconstructions. Asymmetry in the joint space, specifically obliteration or widening, supports the diagnosis of arytenoid cartilage dislocation (Fig. 11). The widened joint space is usually filled with soft tissue density from hemarthrosis and fibrosis. Of course, joint fibrosis from another process, such as rheumatoid arthritis or severe laryngeal reflux, might look similar on a CT scan, but an adequate history and serologic studies should help determine the true etiology.

Rubin *et al.* [82] reported some limitations of CT: (i) in young patients, the cartilage is frequently not ossified and therefore difficult to assess; and (ii) one needs high-quality images with fine cuts and reconstructed images of the larynx, which are not available everywhere. They believed that, although a positive CT scan is helpful to confirm the diagnosis, a negative scan does not rule out dislocation. If the CT is equivocal, LEMG is useful to confirm diagnosis. LEMG is helpful in distinguishing a neurologic from a joint abnormality as the origin of a hypomobile or immobile VF. However, it is possible for both denervation and a joint dislocation to be present. Thus, the LEMG findings must be evaluated in the context of findings on laryngoscopy. For example, if there is marked asymmetry in vocal process height without a jostle sign, there is probably a structural problem in addition to, or despite, the LEMG findings [82]. If LEMG is not available, direct laryngoscopy with palpation of the cricoarytenoid joint shows no passive mobility.

Ankylosis of the cricoarytenoid joint – for example, in end-stage rheumatoid arthritis

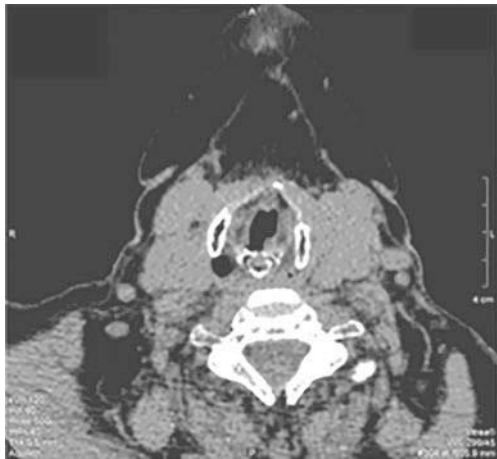The clinical presentation may vary from being asymptomatic to a constellation of upper aerodigestive

Figure 11



Computed tomography scan of the larynx with left arytenoid cartilage dislocation. Compare the obliterated left joint space (thick arrow) with the intact joint space on the right (thin arrow) [82].

Figure 12



Sclerosis of the right arytenoid due the cricoarytenoid rheumatoid involvement [85].

symptoms. The array of symptoms include odynophagia, foreign body sensation, dysphagia, sore throat, lump sensation in the throat, change in voice quality, referred otalgia, and respiratory symptoms [84]. High-resolution computed tomography is the modality of choice for assessing cricoarytenoid involvement in rheumatoid arthritis (Fig. 12) [86].

Similar to arytenoid dislocation, LEMG and direct laryngoscopy with palpation of the cricoarytenoid joint confirm the diagnosis.

Laryngeal malignancy with involvement of the joint or the thyroarytenoid muscle

Careful fiberoptic laryngoscopy combined with a CT scan will reveal neoplastic infiltration as the cause of VFI. LEMG may show decreased amplitude and recruitment of the TA muscle.

Posterior glottis stenosis or interarytenoid scarring

It is a common complication of prolonged endotracheal intubation. On palpation of the cricoarytenoid joint in patients with posterior glottis stenosis or interarytenoid scarring, the posterior commissure and contralateral arytenoid cartilage will be moved to the midline during the vocal process palpation because of the entire posterior glottic complex being fused with scar tissue [37].

Acknowledgements

Conflicts of interest

None declared.

References

- 1 Kupfer RA, Meyer TK. Evaluation of unilateral vocal fold immobility. *Curr Otorhinolaryngol Rep* 2014; 2:105–113.
- 2 Heman-Ackah YD, Sataloff RT. Laryngeal electromyography: basic concepts and clinical uses. *Laryngoscope* 2002; 58:233–238.
- 3 Rosenthal LH, Benninger MS, Deeb RH. Vocal fold immobility: a longitudinal analysis of etiology over 20 years. *Laryngoscope* 2007; 117:1864–1870.
- 4 Ko HC, Lee LA, Li HY, Fang TJ. Etiologic features in patients with unilateral vocal fold paralysis in Taiwan. *Chang Gung Med J* 2009; 32:290–296.
- 5 Wilson-Pauwels L, Akesson EJ, Sterwart PA. Vagus nerve In: L. Wilson-Pauswels, E.J. Akesson, P.A. Stewart (eds.). *Cranial nerves: anatomy and clinical comments*. Toronto: B.C. Decker Inc.; 1988. 126–137.
- 6 Willatt DJ, Stell PM. Vocal cord paralysis. In: Paparella MM, Shumrick DA, Gluckman JL, Meyerhoff WL, editors. *Otolaryngology*. Philadelphia: W.B. Saunders Company; 1991. 2289–2306.
- 7 Glazer HS, Aronberg DJ, Lee JK, Sagel SS. Extralaryngeal causes of vocal cord paralysis: CT evaluation. *Am J Roentgenol* 1983; 141:527–531.
- 8 Merati AL, Halum SL, Smith TL. Diagnostic testing for vocal fold paralysis: survey of practice and evidence-based medicine review. *Laryngoscope* 2006; 116:1539–1552.
- 9 Bando H, Nishio T, Bamba H, Uno T, Hisa Y. Vocal fold paralysis as a sign of chest diseases: a 15-year retrospective study. *World J Surg* 2006; 30:293–298.
- 10 MacGregor FB, Roberts DN, Howard DJ, Phelps PD. Vocal fold palsy: a re-evaluation of investigations. *J Laryngol Otol* 1994; 108:193–196.
- 11 Altman JS, Benninger MS. The evaluation of unilateral vocal fold immobility: is chest X-ray enough? *J Voice* 1997; 11:364–367.
- 12 Terris DJ, Arnstein DP, Nguyen HH. Contemporary evaluation of unilateral vocal fold paralysis. *Otolaryngol Head Neck Surg* 1992; 107:84–90.
- 13 Titche LL. Causes of recurrent laryngeal nerve paralysis. *Arch Otolaryngol* 1976; 102:259–261.
- 14 Younger D, Lange DJ, Lovelace RE. Neuromuscular disorders of the larynx. In: Blitzler A, et al., editors. *Neurologic disorders of the larynx*. New York: Thieme; 1992.
- 15 Holinger LD, Holinger PC, Holinger PH. Etiology of bilateral abductor vocal cord paralysis: a review of 389 cases. *Ann Otol Rhinol Laryngol* 1976; 85(Pt 1):428–436.
- 16 Brazis PW, Masdeu JC, Biller J. *Localization in clinical neurology*. 6th ed. Philadelphia, PA: Lippincott Williams & Wilkins; 2011.
- 17 Yousem DM, Grossman RI. *Neuroradiology: the requisites*. 3rd ed. Philadelphia: Elsevier; 2010.
- 18 Bansal M. *Diseases of ear, nose and throat*. 1st ed. New Delhi: Jaypee Brothers Medical Publishers (P) Ltd; 2013.
- 19 Vachha B, Cunnane MB, Mallur P, Moonis G. Losing your voice: etiologies and imaging features of vocal fold paralysis. *J Clin Imaging Sci* 2013; 3:15.
- 20 Sigal R. Infrahyoid neck. *Radiol Clin North Am* 1998; 36:781–799.
- 21 Aronson AE. *Clinical voice disorders*. New York: Georg Thieme; 1990.
- 22 Gacek RR, Lyon MJ. Fiber components of the recurrent laryngeal nerve in the cat. *Ann Otol Rhinol Laryngol* 1976; 85(Pt 1):460–471.
- 23 Sunderland S. The anatomy and physiology of nerve injury. *Muscle Nerve* 1990; 13:771–784.
- 24 Seddon H. Three types of nerve injury. *Brain* 1943; 66:237–288.
- 25 Sunderland S. *Nerves and nerve injuries*. 2nd ed. Baltimore: Williams and Wilkins; 1978.
- 26 Campbell WW. Evaluation and management of peripheral nerve injury. *Clin Neurophysiol* 2008; 119:1951–1965.
- 27 Kline DG, Hudson AR, New E. *Nerve injuries: operative results for major nerve injuries, entrapments and tumors*. 1st ed. Philadelphia: W.B. Saunders; 1995.
- 28 Eckel HE. Laryngeal nerve disorders. In: M. Anniko, M. Bernal-Sprekelsen, V. Bonkowsky, P.J. Bradley, S. Lurato (eds). *Otorhinolaryngology, head and neck surgery*. European Manual of Medicine. Springer, Berlin, Heidelberg; 2010; 519–525.
- 29 Crumley RL. Unilateral recurrent laryngeal nerve paralysis. *J Voice* 1994; 8:79–83.
- 30 Crumley RL. Laryngeal synkinesis: its significance to the laryngologist. *Ann Otol Rhinol Laryngol* 1989; 98:87–92.
- 31 Kotby MN, Fadly E, Madkour O, Barakah M, Khidir A, Alloush T, Saleh M. Electromyography and neurography in neurology. *J Voice* 1992; 6:159–187.

- 32 Woodson GE. Configuration of the glottis in laryngeal paralysis. I: Clinical study. *Laryngoscope* 1993; 103(Pt 1):1227–1234.
- 33 Koufman JA, Walker FO, Joharji GM. The cricothyroid muscle does not influence vocal fold position in laryngeal paralysis. *Laryngoscope* 1995; 105:368–372.
- 34 Furukawa M, Furukawa MK, Ooishi K. Statistical analysis of malignant tumors detected as the cause of vocal cord paralysis. *ORL J Otorhinolaryngol Relat Spec* 1994; 56:161–165.
- 35 Kotby MN. Voice disorders; recent diagnostic advances. *Egypt J Otolaryngol* 1986; 3:69–98.
- 36 Meurman OH. Vocal cord paralysis following thyroid surgery; a study of 104 cases. *Acta Chir Scand* 1951; 101:360–378.
- 37 Rosen CA, Simpson CB. *Operative techniques in laryngology*. Berlin, Heidelberg: Springer-Verlag; 2008.
- 38 Kashima HK. Documentation of upper airway obstruction in unilateral vocal cord paralysis: flow-volume loop studies in 43 subjects. *Laryngoscope* 1984; 94:923–937.
- 39 Rubin AD, Sataloff RT. Vocal fold paresis and paralysis. *Otolaryngol Clin North Am* 2007; 40:1109–1131.
- 40 LaBlance GR, Maves MD. Acoustic characteristics of post-thyroidectomy patients. *Otolaryngol Head Neck Surg* 1992; 107:558–563.
- 41 Lundy DS, Casiano RR. 'Compensatory falsetto': effects on vocal quality. *J Voice* 1995; 9:439–442.
- 42 Finck C. Laryngeal dysfunction after thyroid surgery: diagnosis, evaluation and treatment. *Acta Chir Belg* 2006; 106 78–387.
- 43 Hong KH, Youn HW, Kim CH. The vertical level of the paralyzed vocal fold in unilateral vocal fold paralysis. *Korean J Otolaryngol* 2000; 43:866–872.
- 44 Rontal E, Rontal M. Permanent medialization of the paralyzed vocal fold utilizing botulinum toxin and Gelfoam. *J Voice* 2003; 17:434–441.
- 45 Blitzer A, Jahn AF, Keider A. Semon's law revisited: an electromyographic analysis of laryngeal synkinesis. *Ann Otol Rhinol Laryngol* 1996; 105:764–769.
- 46 Belafsky PC, Postma GN, Reulbach TR, Holland BW, Koufman JA. Muscle tension dysphonia as a sign of underlying glottal insufficiency. *Otolaryngol Head Neck Surg* 2002; 127:448–451.
- 47 Merati AL. In-office evaluation of swallowing: FEES, pharyngeal squeeze maneuver, and FEESST. *Otolaryngol Clin North Am* 2013; 46(1): 31–39.
- 48 Oyamada Y, Yumoto E, Nakano K, Goto H. Asymmetry of the vocal folds in patients with vocal fold immobility. *Arch Otolaryngol Head Neck Surg* 2005; 131:399–406.
- 49 Kitzing P. Stroboscopy — a pertinent laryngological examination. *J Otolaryngol* 1985; 14:151–157.
- 50 Fex S, Elmqvist D. Endemic recurrent laryngeal nerve paresis. Correlation between EMG and stroboscopic findings. *Acta Otolaryngol* 1973; 75:368–369.
- 51 Sercarz JA, Berke GS, Ming Y, Gerratt BR, Natividad M. Videostroboscopy of human vocal fold paralysis. *Ann Otol Rhinol Laryngol* 1992; 101:567–577.
- 52 Patel R, Dailey S, Bless D. Comparison of high-speed digital imaging with stroboscopy for laryngeal imaging of glottal disorders. *Ann Otol Rhinol Laryngol* 2008; 117:413–424.
- 53 Kendall KA. High-speed digital imaging of the larynx: recent advances. *Curr Opin Otolaryngol Head Neck Surg* 2012; 20:466–471.
- 54 Woo P. Objective measures of laryngeal imaging: what have we learned since Dr. Paul Moore. *J Voice* 2014; 28:69–81.
- 55 Voigt D, Döllinger M, Yang A, Eysholdt U, Lohscheller J. Automatic diagnosis of vocal fold paresis by employing phonovibrogram features and machine learning methods. *Comput Methods Programs Biomed* 2010; 99:275–288.
- 56 Kimura M, Imagawa H, Nito T, Sakakibara K, Chan RW, Tayama N. Arytenoid adduction for correcting vocal fold asymmetry: high-speed imaging. *Ann Otol Rhinol Laryngol* 2010; 119:439–446.
- 57 Švec JG, Šram F, Schutte HK. Videokymography in 2000: the present state and perspectives of the high-speed line-imaging technique. In: Braunschweig T, Hanson J, Schelhorn-Neise P, Witte H, editors. *Advances in quantitative laryngoscopy, voice and speech research. Proceedings of the 4th International Workshop [ISBN: 3-00-005636-X]*. Jena, Germany: Friedrich-Schiller University; 2000. 57–62.
- 58 Schutte HK, Švec JG, Šram F. First results of clinical application of videokymography. *Laryngoscope* 1998; 108(Pt 1):1206–1210.
- 59 Zagólski O. Electroglottography in elderly patients with vocal-fold palsy. *J Voice* 2009; 23:567–571.
- 60 Zagólski O, Carlson E. Electroglottographic measurements of glottal function in vocal fold paralysis in women. *Clin Otolaryngol Allied Sci* 2002; 27:246–253.
- 61 Mueller PB. The aging voice. *Semin Speech Lang* 1997; 18:159–168; quiz 168–169.
- 62 Hartl DA, Hans S, Vaissière J, Brasnu DA. Objective acoustic and aerodynamic measures of breathiness in paralytic dysphonia. *Eur Arch Otorhinolaryngol* 2003; 260:175–182.
- 63 Eskenazi L, Childers DG, Hicks DM. Acoustic correlates of vocal quality. *J Speech Hear Res* 1990; 33:298–306.
- 64 Netterville JL, Jackson CG, Civantos F. Thyroidectomy in the functional rehabilitation of neurotologic skull base surgery patients. *Am J Otol* 1993; 14:460–464.
- 65 Yu P, Ouaknine M, Revis J, Giovanni A. Objective voice analysis for dysphonic patients: a multiparametric protocol including acoustic and aerodynamic measurements. *J Voice* 2001; 15:529–542.
- 66 Kotby MN, Haugen LK. Clinical application of electromyography in vocal fold mobility disorders. *Acta Otolaryngol* 1970; 70:428–437.
- 67 Kotby MN. Percutaneous laryngeal electromyography. Standardization of the technique. *Folia Phoniatr (Basel)* 1975; 27:116–127.
- 68 Volk GF, Hagen R, Pototschnig C, Friedrich G, Nawka T, Arens C, et al. Laryngeal electromyography: a proposal for guidelines of the European Laryngological Society. *Eur Arch Otorhinolaryngol* 2012; 269:2227–2245.
- 69 Rickert SM, Childs LF, Carey BT, Murry T, Sulica L. Laryngeal electromyography for prognosis of vocal fold palsy: a meta-analysis. *Laryngoscope* 2012; 122:158–161.
- 70 Rontal E, Rontal M, Silverman B, Kileny PR. The clinical differentiation between vocal cord paralysis and vocal cord fixation using electromyography. *Laryngoscope* 1993; 103:133–137.
- 71 Koufman JA, Postma GN, Whang CS, Rees CJ, Amin MR, Belafsky PC, et al. Diagnostic laryngeal electromyography: the Wake Forest experience 1995–1999. *Otolaryngol Head Neck Surg* 2001; 124:603–606.
- 72 Guntinas-Lichius O, Sittel C. *Neurology of larynx and trachea*. Berlin, Heidelberg: Springer-Verlag; 2010. 257–268.
- 73 Hirano M, Nosoe I, Shin T, Maeyama T. Electromyography for laryngeal paralysis. In: Hirano M, Kirchner J, Bless D, editors. *Neurology of larynx: recent advances*. 1st ed. Boston, MA: College Hill; 1987. 232–248.
- 74 Blitzer A, Crumley RL, Dailey SH, Ford CN, Floeter MK, Hillel AD, et al. Recommendations of the Neurology of Larynx Study Group on laryngeal electromyography. *Otolaryngol Head Neck Surg* 2009; 140:782–793.
- 75 Sittel C, Stennert E, Thumfart WF, Dapunt U, Eckel HE. Prognostic value of laryngeal electromyography in vocal fold paralysis. *Arch Otolaryngol Head Neck Surg* 2001; 127:155–160.
- 76 Richardson BE, Bastian RW. Clinical evaluation of vocal fold paralysis. *Otolaryngol Clin North Am* 2004; 37:45–58.
- 77 Song SW, Jun BC, Cho KJ, Lee S, Kim YJ, Park SH. CT evaluation of vocal cord paralysis due to thoracic diseases: a 10-year retrospective study. *Yonsei Med J* 2011; 52:831–837.
- 78 Wang CP, Chen TC, Lou PJ, Yang TL, Hu YL, Shieh MJ, et al. Neck ultrasonography for the evaluation of the etiology of adult unilateral vocal fold paralysis. *Head Neck* 2012; 34:643–648.
- 79 Jacobs CJ, Harnsberger HR, Lufkin RB, Osborn AG, Smoker WR, Parkin JL. Vagal neuropathy: evaluation with CT and MR imaging. *Radiology* 1987; 164:97–102.
- 80 Jang YY, Lee SJ, Jeon JY, Lee SJ. Analysis of video fluoroscopic swallowing study in patients with vocal cord paralysis. *Dysphagia* 2012; 27:185–190.
- 81 Sataloff RT, Bough ID Jr, Spiegel JR. Arytenoid dislocation: diagnosis and treatment. *Laryngoscope* 1994; 104(Pt 1):1353–1361.
- 82 Rubin AD, Hawkshaw MJ, Moyer CA, Dean CM, Sataloff RT. Arytenoid cartilage dislocation: a 20-year experience. *J Voice* 2005; 19:687–701.
- 83 Alexander AE Jr, Lyons GD, Fazekas-May MA, Rigby PL, Nuss DW, David L, Williams K. Utility of helical computed tomography in the study of arytenoid dislocation and arytenoid subluxation. *Ann Otol Rhinol Laryngol* 1997; 106:1020–1023.
- 84 Montgomery WW. Cricoarytenoid arthritis. *Laryngoscope* 1963; 73:801–836.
- 85 Stojanović S, Belić B. Laryngeal manifestations of rheumatoid arthritis. In: Matsuno H, editor. *Innovative rheumatology*. 1st ed. InTech; 2013. 216–245.
- 86 Bayar N, Kara Sa, Keles I, Koc C, Altinok, D, Orkun S. Cricoarytenoid in rheumatoid arthritis: radiologic and clinical study. *J Otolaryngol* 2003; 32:373–378.