

Orbital complications of sinus origin: diagnosis, differential diagnosis, and management

Nassim Talaat^a, Sherif Safwat^b, Nader Naguib^c, Fady Ghareb^a

^aDepartment of Otolaryngology, Faculty of Medicine, Cairo University, Cairo,

^bNational Institute of Laser Enhanced Science and ^cDepartment of Otolaryngology, Faculty of Medicine, Beni Suif University, Beni-Suef, Egypt

Correspondence to Nassim Talaat, MD, Department of Otolaryngology, Faculty of Medicine, Cairo University, Cairo, Egypt 11121, 30 morad street

Tel: 01223412755; fax: 35734442
e-mail: nasantalat@yahoo.com

Received 11 December 2012

Accepted 13 April 2013

The Egyptian Journal of Otolaryngology
2014, 30(1):10-16

Objective

The aim of this study was to propose a proper and standardized protocol for the management of patients diagnosed with orbital complications of sinus origin. This depends on the original clinical diagnosis, or as the patient sent from the ophthalmology department, after computerized tomography, and sometimes pathology, some cases proved to be of nonsinus origin.

Materials and methods

This is a retrospective study that included 62 patients diagnosed with orbital complications of sinus origin and treated in the last 8 years; the data collected included medical history, detailed examination including endoscopic findings, radiological results, and finding at surgical intervention if performed. Follow-up data were collected for at least 6 months after management.

Results

Sinusitis of different etiologies can affect the orbit, affection is not always by direct extension, and the orbit may also be affected by noninfectious lesions from the sinuses.

Conclusion

Proper management of orbital complications of sinusitis requires meticulous assessment of history, examination, and radiology for a proper diagnosis without delay that may adversely affect vision.

Keywords:

complication, orbit, sinusitis

Egypt J Otolaryngol 30(1):10-16

© 2014 The Egyptian Oto - Rhino - Laryngological Society
1012-5574

Introduction

The most common sinus pathology affecting the eye is acute bacterial rhinosinusitis, which is mostly a mild and self-limiting disease, but it may progress to severe and life-threatening complications; one of these complications is orbital, where visual loss is a direct consequence [1].

Orbital inflammation is still classified by Chandler's original description as preseptal and postseptal; the latter includes subperiosteal abscess, orbital abscess, and orbital cellulitis. The condition may progress to cavernous sinus thrombosis. Periorbital swelling is a common presenting feature together with proptosis, and sometimes, visual affection. It is well known that these complications are more common in young patients [2]. Computerized tomography (CT) with contrast remains the optimal imaging study for orbital inflammation.

If the diagnosis is established, conservative management in the form of oral or parental antibiotics or surgical management is carried out according to certain parameters; the most important factor in predicting the failure of antibiotic treatment is abscess formation. Patients with fever and proptosis are at a risk of developing subperiosteal orbital abscesses [3].

Another important sinus lesion that affects the orbit is fungal sinusitis, whether invasive or not; the ratio of orbital affection reaches over 70% in the invasive form and about 12% in the noninvasive form. CT findings may be similar in both forms; whereas orbital floor invasion is found only in the invasive form, involvement of the extraocular muscles and optic atrophy are found more often in the chronic than in the acute invasive form. It should be kept in mind that patients with acute invasive fungal sinusitis may have limited evidence of orbital involvement on scanning, despite extensive clinical disease [4].

Depending only on clinical examination, the cause of orbital affection may not be clear, whether it is bacterial or fungal, acute or chronic, and even whether this orbital affection is really because of sinus disease.

CT findings may not always explain the clinical condition as sometimes the patient may be completely blind, with the CT showing only minimal opacity.

Materials and methods

This is a retrospective study that includes 84 patients, diagnosed and treated in the ENT department, faculty of medicine, Cairo University, in the period

between 2003 and 2011. All the patients were initially diagnosed with orbital complications because of sinus disease. Patient age ranged from 6 to 71 years. There were 39 females and 45 males.

The data collected for all patients included the following:

- (1) Medical history as noted in the admission sheet.
- (2) Results of nasal and sinus examination including endoscopic findings.
- (3) Radiology including CT, MRI, and others, but at least every case included had CT paranasal sinuses coronal cuts.
- (4) Results of ophthalmological consultation.
- (5) Details of management, including operative details if any.
- (6) Photography for the patient if available.

- (7) Follow-up data for at least 6 months after treatment.

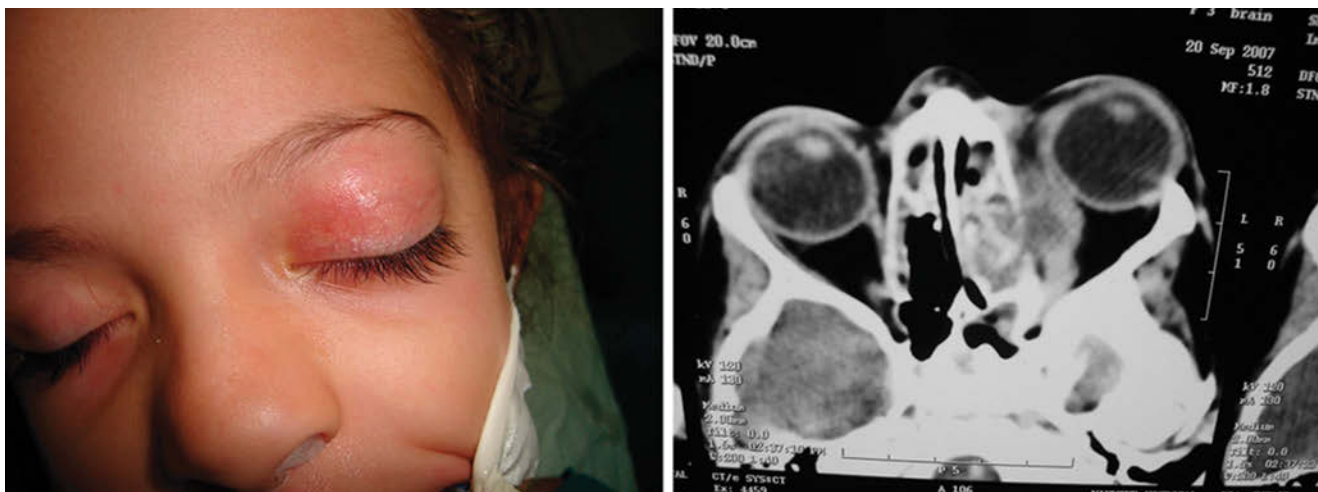Results

According to history, endoscopic examination, CT findings, and the operative findings in patients who were operated upon, patients were divided into six groups in terms of the final diagnosis:

Group A: acute bacterial rhinosinusitis, which included 27 patients (Fig. 1).

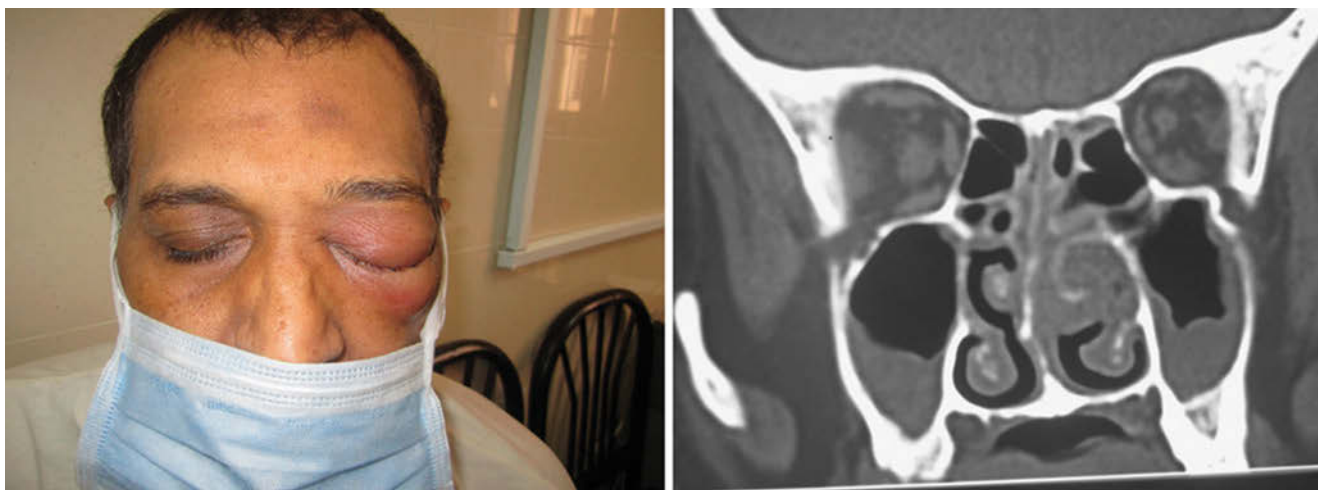
Group B: mucormycosis, which included 13 patients (Fig. 2).

Figure 1



Acute sinusitis in a child complicated by subperiosteal abscess.

Figure 2



Mucormycosis.

Group C: indolent fungal sinusitis, which included 14 patients (Fig. 3).

Group D: orbital pseudotumors, which included four patients (Fig. 4).

Group E: orbital tumors, which included three patients (Fig. 5).

Group F: unknown, one patient (Fig. 6).

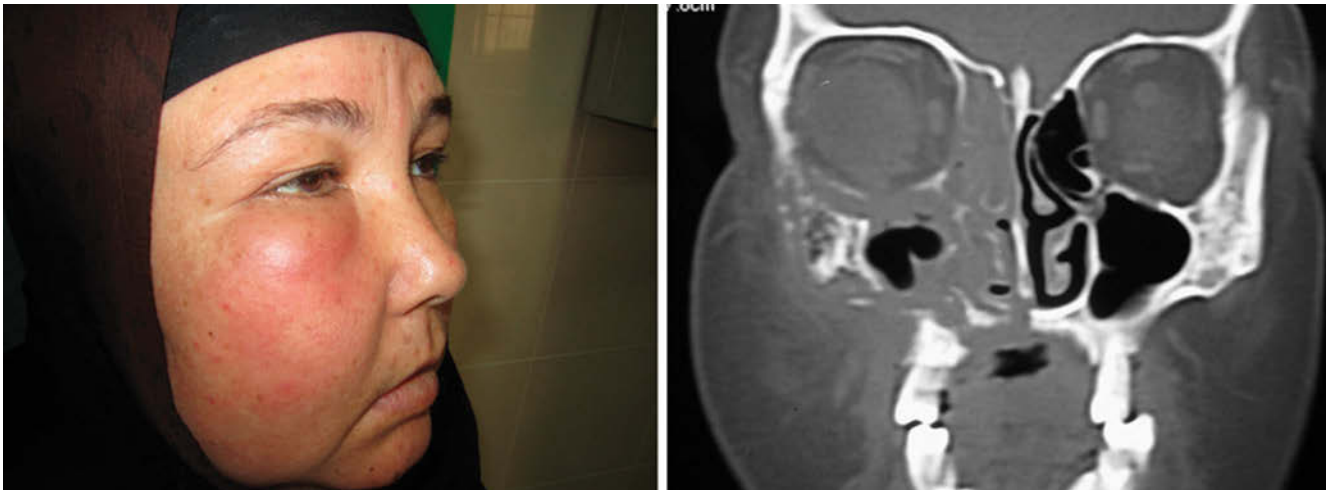
Data were statistically described in terms of mean \pm SD, median and range, or frequencies (number of cases) and percentages when appropriate. Comparison of numerical variables between the study groups was carried out using the Mann–Whitney *U*-test for independent samples when comparing two groups and

the Kruskal–Wallis test with post-hoc multiple two-group comparisons when comparing more than two groups. For comparison of categorical data, the χ^2 -test was used. The exact test was used when the expected frequency was less than 5. *P* values less than 0.05 were considered statistically significant. All statistical calculations were carried out using computer programs statistical package for the social science (SPSS Inc., Chicago, Illinois, USA) version 15 for Microsoft Windows.

We had chosen six varieties to compare between the study groups shown in Figs 7–11. Figure 7 shows the mean ages of the patients in the different study groups.

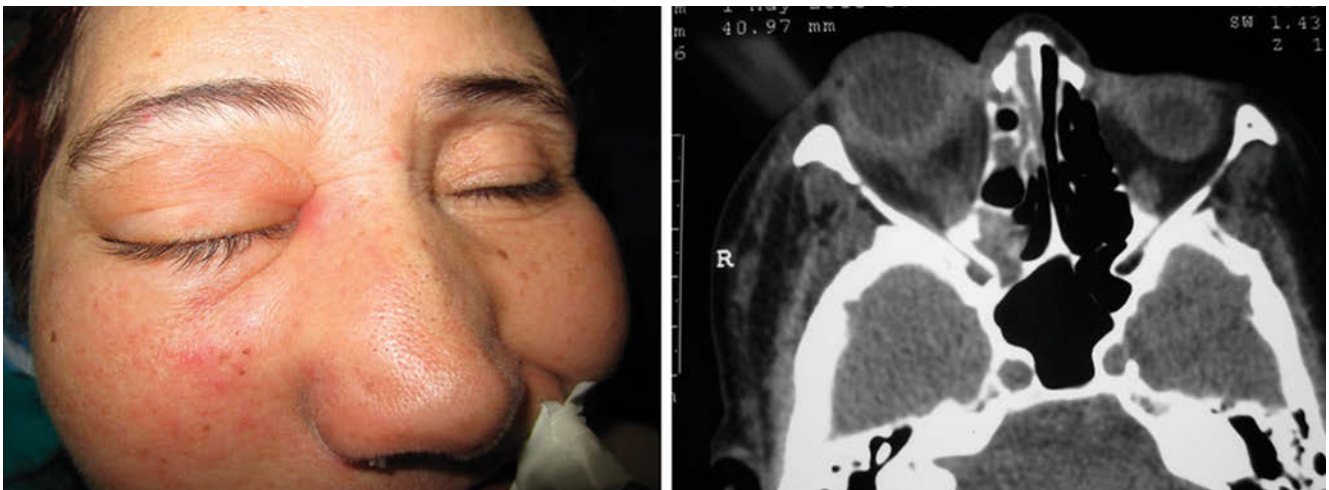
Figure 8 shows the presenting symptom, whether it was nasal (n), orbital (o), or both (n/o), in the different

Figure 3



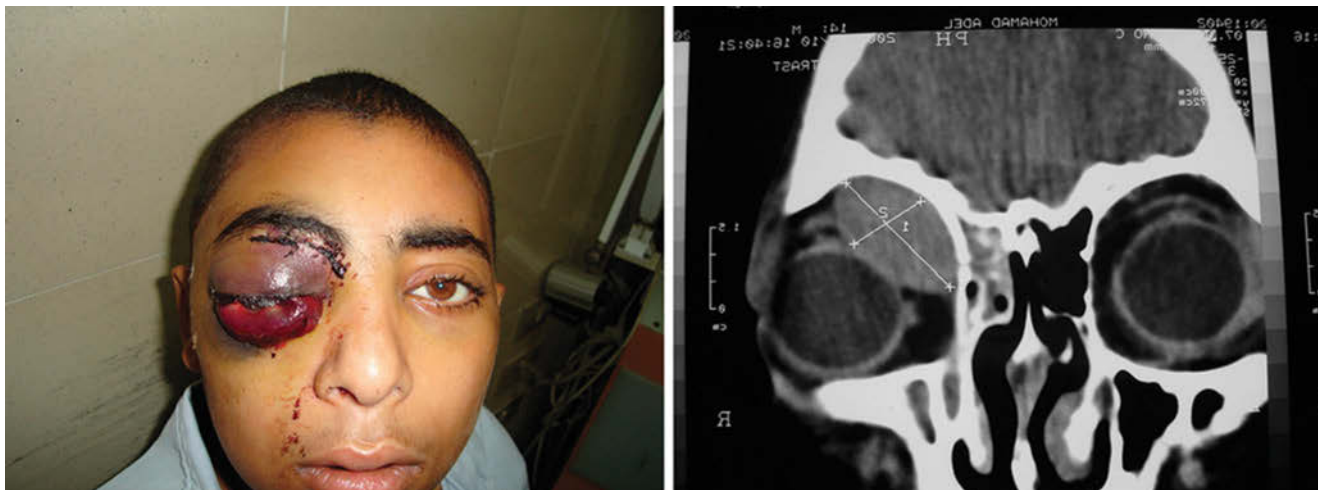Indolent fungal sinusitis.

Figure 4



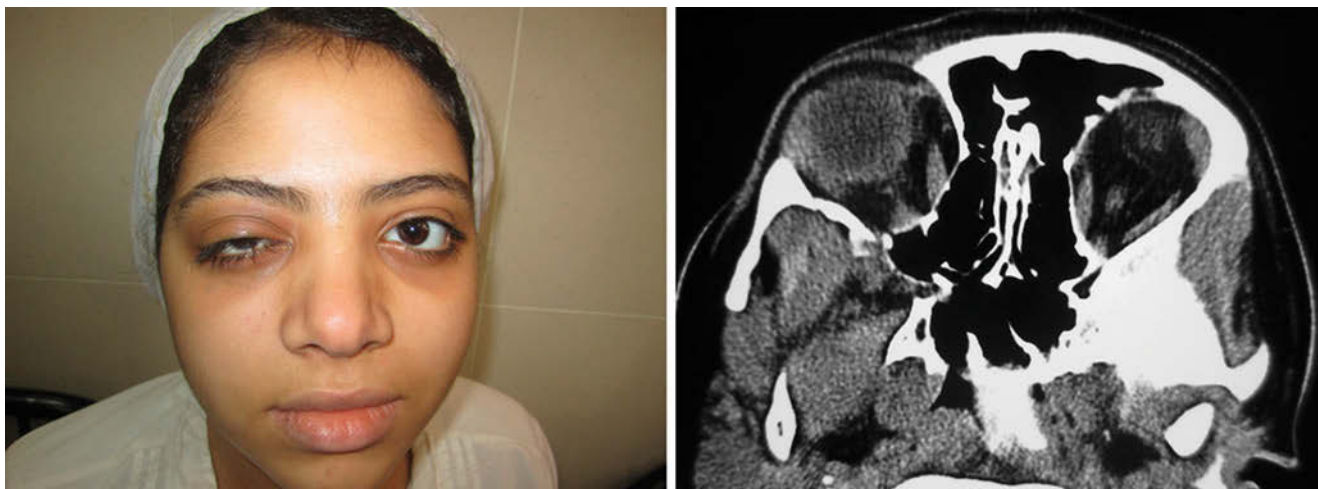Orbital pseudotumors.

Figure 5



Orbital tumors.

Figure 6



Unknown.

groups; nasal symptoms were mainly nasal block and discharge, whereas orbital symptoms were mainly swelling around the eye, proptosis, and visual problems.

In most cases, nasal endoscopy shows findings that are indicative of the causative pathology, whereas in some cases, nasal examination is not conclusive and may even show no abnormalities (by indicative nasal endoscopy, we mean signs that diagnose the causative pathology, i.e. in acute bacterial rhinosinusitis, purulent nasal discharge and marked mucosal edema are indicative of the disease).

Figure 9 shows the percent of indicative nasal endoscopy in different groups.

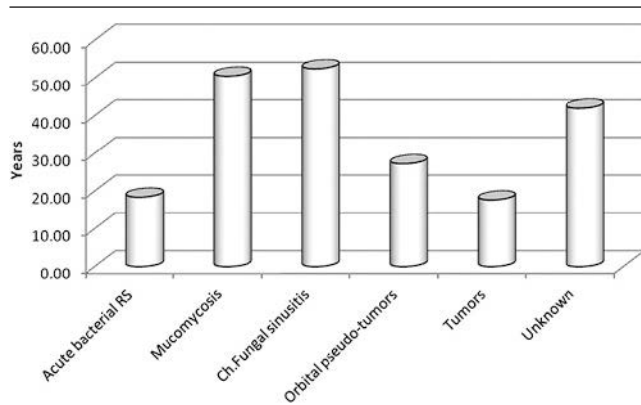
Being the most important radiologic investigation, CT is almost always diagnostic; however, in some

rare cases, the CT findings are not comparable to the orbital affection or CT may be completely normal. Figure 10 shows the percent of positive CT findings in the different groups.

Figure 11 shows the distribution of treatment modalities between the study groups, whether it is surgical, medical, or both.

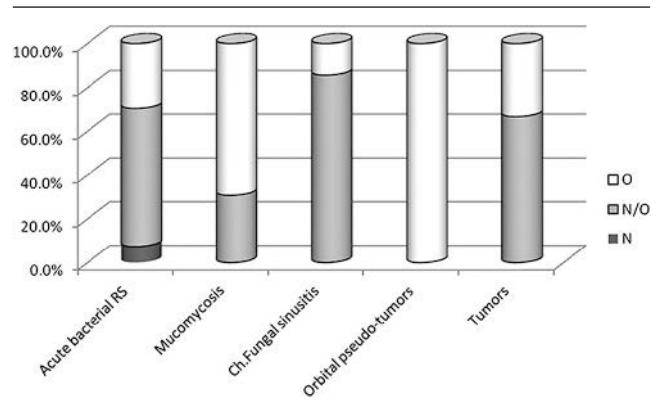
Medical and surgical treatment varied according to the diagnosis: patients with acute bacterial rhinosinusitis who had no abscess by CT with no visual acuity diminution were treated medically by parental antibiotics and steroids, and those who failed to improve or had abscess or showed diminution of vision were managed by endoscopic sinus surgery for drainage and decompression; out of 27 patients, only 10 were managed medically.

Figure 7



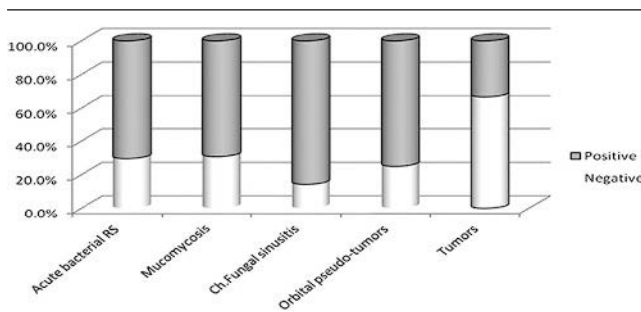
Mean age of the patients in the different study groups.

Figure 8



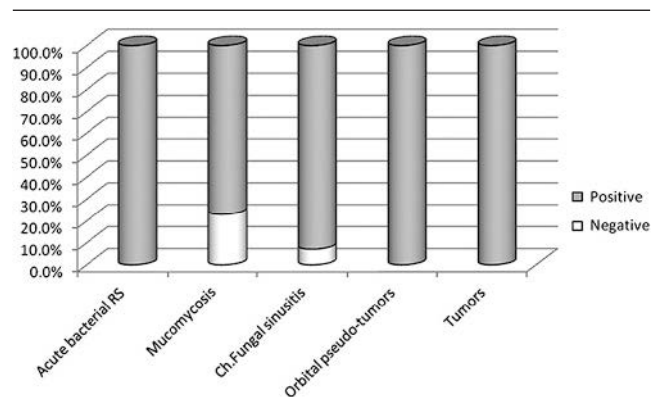
Distribution of findings of assessment of history between the study groups. n, nasal; n/o, nasal/orbital; o, orbital.

Figure 9



Distribution of examination findings between the study groups.

Figure 10



Distribution of computed tomography findings between the study groups.

In cases of mucormycosis, all the 13 patients were administered amphotericin B; in addition, endoscopic debridement was performed in six cases. Four of the remaining cases were candidates for surgery but their poor general condition did not allow this.

Similarly, among the 14 patients with indolent fungal sinusitis, only six were operated upon because of the poor general condition of the patients and the presence of some contraindications to surgery, for example, bleeding tendency.

Most of patients with orbital pseudotumors (3/4) and all patients with orbital tumors (3/3) received a surgical intervention.

It was difficult to compare the prognosis in different groups; we considered the prognosis as good if the patient survived and the vision was saved or at least if deterioration had ceased (Figure 12).

Discussion

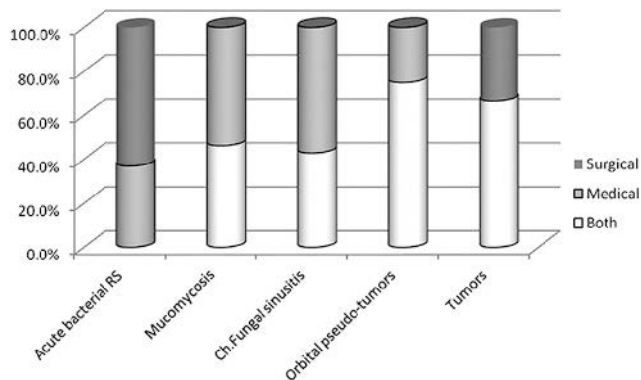
The distribution of the patients showed that acute bacterial rhinosinusitis (group A) was the major cause

of orbital affection and most of the patients were young (mean = 18.41); fungal sinusitis whether acute (group B) or chronic (group C) represent together the second major group, with mean age about 50, this goes with the literature where orbital cellulitis is mainly a disease of children [5].

In our study, there was no sex predominance (29 males and 33 females); we did not have any case with bilateral affection. In the group of patients with bacterial rhinosinusitis, there were no cases with secondary intracranial infection, whereas this was found in four of the 13 patients with acute fungal sinusitis.

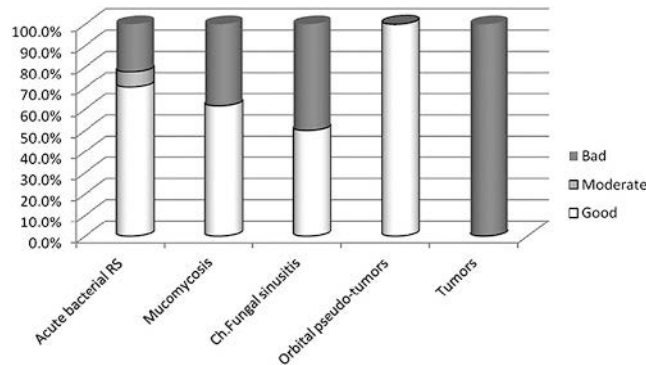
The spread of infection from the ethmoids to the orbit is very rapid, and patients reported a brief history of ophthalmic symptoms usually less than 3 days; the presenting symptoms were orbital (24) in the form of swelling around the eye, and visual problems, orbital and nasal (35), nasal (two): upper respiratory tract infection, nasal blockage, and discharge, development of orbital complications may even occur

Figure 11



Distribution of treatment modalities between the study groups.

Figure 12



Distribution of good prognosis between the study groups.

under antibiotic treatment [6]. In most cases, nasal endoscopy showed findings that were indicative of the causative pathology (72%), whereas in some cases, the nasal examination was not conclusive and even showed no abnormalities (28%). The accuracy of the CT proved to be superior to that of endoscopic examination (93.4% positive). CT is the most important single investigation [7] and all patients with orbital complications are candidates for high-resolution CT axial and coronal cuts, either immediate or delayed (only with normal ocular movement and vision). Visual assessment is mandatory including color vision, and immunological profile for patients with fungal sinusitis. In group A, It should be noted that in both the medical and the surgical groups, the good prognosis was about 70%; thus, the prognosis did not depend on the modality of treatment, but on the overall management including proper diagnosis and timing of intervention. Dewan *et al.* [8] reported that for abscesses larger than 2 cm, combined sinus and abscess drainage improve the prognosis. The following protocol was proposed for the management of patients with orbital complications because of bacterial rhinosinusitis:

All patients were admitted (except patients with minor edema) endoscopic and ophthalmic assessment including vision every 1 h intravenous antibiotics:

- (1) Any deterioration of vision and or fixed globe emergency drainage.
- (2) Visual or neurological symptom of cavernous sinus thrombosis emergency CT drainage under cover of antibiotics.
- (3) Good vision with proptosis CT if not improving drainage, if improving: Follow-up CT within 24 h if improving continue medical.
- (4) No visual loss or proptosis CT within 24 h improving continue medical.

In fungal sinusitis, the condition was different: In cases of the acute (fulminant) invasive form, surgical debridement did not improve the prognosis but, on the contrary, worsened it, as medical treatment alone led to an 85% improvement (6/7 cases), whereas including surgery led to only a 33% improvement (2/6 cases), and in the chronic invasive and granulomatous forms, surgical debridement improved the prognosis (66% compared with 37% in medical treatment alone).

Factors affecting the prognosis in fungal sinusitis were mainly the general condition of the patient including the immunity and the presence of intracranial extension [9].

In the orbital pseudotumor group, three of four patients were treated surgically, with a good prognosis in all; it should be mentioned that originally orbital pseudotumors were not of sinus origin, but the presentation with proptosis and the fact that opacity may be an accidental finding in the CT make these patients candidates for endoscopy at least for a tissue biopsy.

In the orbital tumor group, the three patients were managed by an endoscopic biopsy and then surgical excision or chemotherapy according to the pathology; here, the prognosis was related to the original pathology.

Conclusion

- (1) Proper management of orbital complications of sinus origin requires a team of an expert rhinologist, ophthalmologist, radiologist, and internist.
- (2) Endoscopy and radiology are important for a proper diagnosis.
- (3) Surgical skill is not the only factor that affects the prognosis but also proper decision making at the proper time.

Acknowledgements

Conflicts of interest

There are no conflicts of interest.

References

- 1 Suhaili DN, Goh BS, Gendeh BS. A ten year retrospective review of orbital complications secondary to acute sinusitis in children. *Med J Malaysia* 2010; 65:49–52.
- 2 Beswell J, Bauman NM. Management of pediatric orbital cellulitis and abscess. *Curr Opin Otolaryngol Head Neck Surg* 2011; 19:467–473.
- 3 Huang SF, Lee TJ, Lee YS, Chen CC, Chin SC, Wang NC. Acute rhinosinusitis-related orbital infection in pediatric patients: A retrospective analysis. *Ann Otol Rhinol Laryngol* 2011; 120:185–190.
- 4 Chandrasekharan R, Thomas M, Rupa V. Comparative study of orbital involvement in invasive and non invasive fungal sinusitis. *J Laryngol Otol* 2012; 126:152–158.
- 5 Yang M, Quah BL, Seah LL, Looi A. Orbital cellulitis in children-medical treatment versus surgical treatment. *Orbit* 2009; 28:124–136.
- 6 Sinclair CF, Berkowitz RG. Prior antibiotic therapy for acute sinusitis in children and the development of subperiosteal orbital abscess. *Int J Pediatr Otorhinolaryngol* 2007; 71:1003–1006.
- 7 Parvizi N, Choudhury N, Singh A. Complicated periorbital cellulitis: Case report and literature review. *J Laryngol Otol* 2012; 126:94–96.
- 8 Dewan MA, Meyor DR, Wladis EJ. Orbital cellulitis with subperiosteal abscess: Demographics and management outcomes. *Ophthal Plast Reconstr Surg* 2011; 27:330–332.
- 9 Sridhar J, Lam BL, Pasol J, Sternau L. Neuro-ophthalmic manifestations of fungal disease. *J Neuroophthalmol* 2012; 32:197-201.