

CASE REPORT

Open Access

# Bilateral antrochoanal polyps: a case report

Kaoutar cherrabi<sup>1,2\*</sup>, Nabil Touihem<sup>2,3</sup> , Ismail Nakkabi<sup>2,3</sup>  and Karim Nadour<sup>2,3</sup> 



## Abstract

**Background:** Antrochoanal or Killian polyp is a rare polyp of the maxillary sinus in adults. It is generally unilateral, implanted on the lateral wall of the maxillary sinus upon the uncinate process. Bilateral cases are very rare; only 14 cases have been cited from 1980 to 2020.

**Case presentation:** Our patient presented with a complete bilateral nasal obstruction, this symptom persisted for more than 10 years, with a perceived prolapse in his throat in the last 4 months. Anterior rhinoscopy showed a polyp that took up the totality of his nasal vestibule. Posterior rhinoscopy showed a polyp bulging behind the uvula.

The challenge in this case is related to diagnosis decision; conditions with the same clinical presentation are several. Diagnosis was established through the clinical, radiological, and endoscopic aspects, and confirmed by histological findings. Management was obtained through functional endoscopic sinus surgery; no recurrence was noted in the 12-month follow-up, and clinical signs had completely subsided.

**Conclusion:** Diagnosis in bilateral forms of Killian polyp is perplexing; however, its management is generally simple, with excellent outcome. We report the case of the 15th patient along with a systematic literature review discussing bilateral Killian polyps, illustrated by a rare case of enormous bilateral antrochoanal polyps.

**Keywords:** Antrochoanal polyp, Bilateral, Rare, CT, Surgery, Endoscopy

## Background

Antrochoanal polyp is a rare form of nasal polyps in adults; they are more seen in children and adolescents [1]. Bilateral forms are very rare [1–7]. Only 14 cases have been mentioned in the literature [8–21]. Diagnosis difficulty is generally due to the scarcity of this disease, and the similar clinical presentation of more frequent differential diagnosis [1–4]. Management is generally surgical through functional endoscopic sinus surgery, and outcome is great with clinical improvement and no recurrence in follow-up [8–21].

This is a very rare case of bilateral antrochoanal polyp that has long been treated as sinonasal polyposis, without any response to treatment; the aim of this article is to pinpoint the importance of thorough evaluation of

clinical and endoscopic findings during patient's follow-up in chronic rhinosinusitis to re-establish diagnosis and rearrange management strategy according to patient's case.

## Case presentation

A 45-year-old man came to daytime clinic in the Oto-rhino-laryngology department; he had no history of atopy or allergic rhinitis, and no other general conditions and comorbidities.

This patient have had bilateral chronic nasal obstruction for more than 10 years, associated with sporadic headaches, anosmia, nasal discharge, and the sensation of a mass in his throat. No other symptoms were noted.

No relevant medical or familial history was noted; there were no similar cases in the family.

He had never had any surgical interventions.

Anterior rhinoscopy showed a greyish polyp that took on the totality of both nasal cavities, visible in the nasal vestibule. No further landmarks of nasal cavity were

\* Correspondence: [cherrabi.kaoutar@gmail.com](mailto:cherrabi.kaoutar@gmail.com)

<sup>1</sup>ENT and Cervico-Facial Surgery Department, Hassan II University Hospital, Fez, Morocco

<sup>2</sup>Faculty of Medicine and Pharmacy, Sidi Mohammed Ben Abdellah University, Fez, Morocco

Full list of author information is available at the end of the article

visible. Oropharyngeal examination showed exteriorization of a multi-lobular mass behind the uvula.

The patient underwent laboratory and radiological tests. A mild inflammatory syndrome was found with CRP (C Reactive protein) at 35; white blood count was at 12,000, and no other anomalies were found. Respiratory assessment did not find any signs of chronic obstructive diseases, and cardiac assessment was unremarkable.

Computed tomography of paranasal sinuses showed an almost complete opacification of maxillary sinuses and the presence of soft tissue masses passing through the maxillary ostium and extending into the corresponding nasal cavities and posteriorly to the adjacent nasopharynx. The other sinuses were normally aerated. (Figs. 1 and 2).

A biopsy was performed and showed an inflammatory polyp.

The diagnostic challenge consisted on the heterogeneous pool of differential diagnosis, and the non-specific clinical presentation of this chronic condition.

Malignancy was first ruled out based on the chronic evolution and the absence of signs of infiltration to

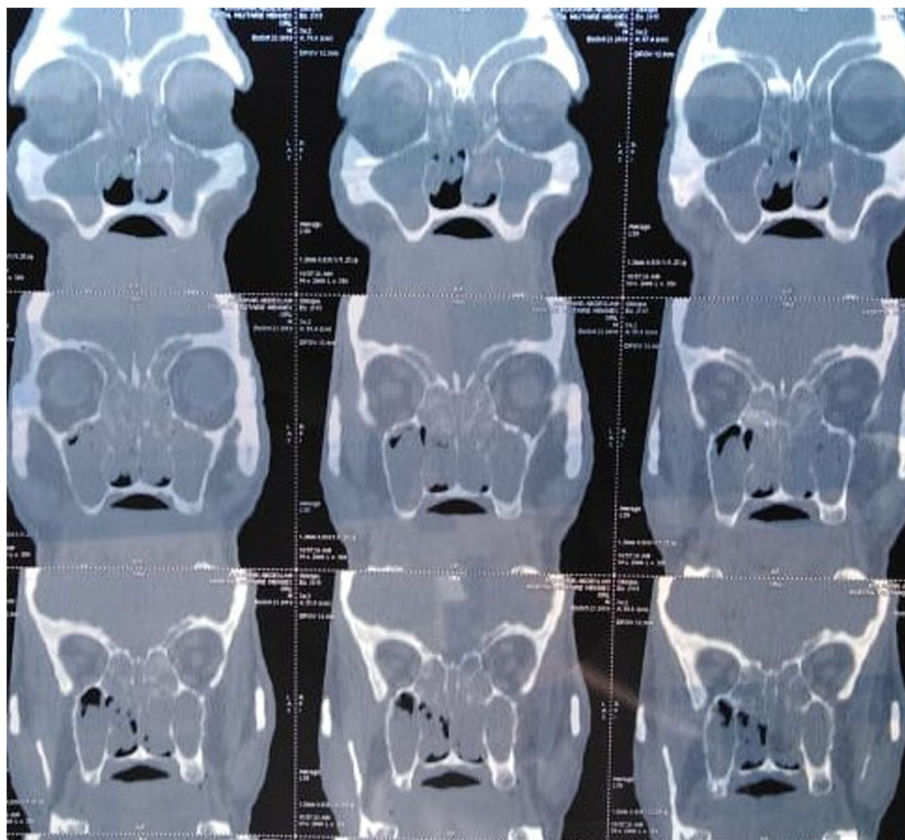
osseous walls. Then several chronic conditions were considered: Fernand-Widal syndrome, nasal polyposis, and allergic or infectious chronic rhinosinusitis. The diagnosis of bilateral antrochoanal polyp was maintained upon clinical, radiological, endoscopic and histological findings.

These polyps were classified grade III according to Chung et al.'s classification [6].

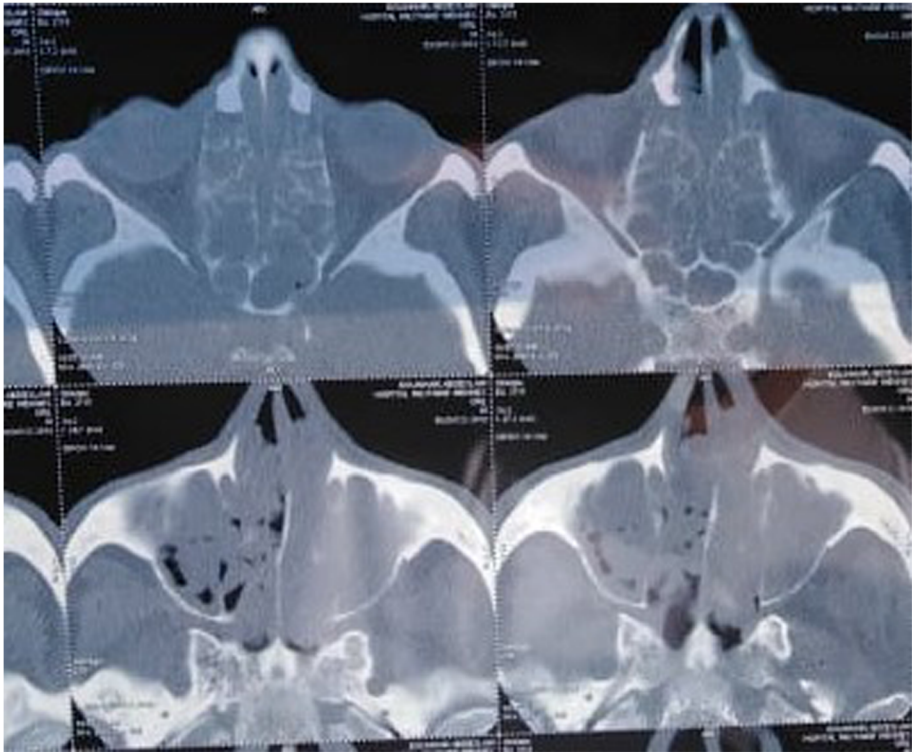The patient first received a medical preparation with steroids and antibiotics before endoscopic surgery.

Oral steroids were prescribed: Prednisone 20 mg, 3 tablets once a day for 5 days, and a course of amoxicillin clavulanate, 1g three times a day for a week. No local treatment was prescribed because of the total obstruction of both nasal cavities.

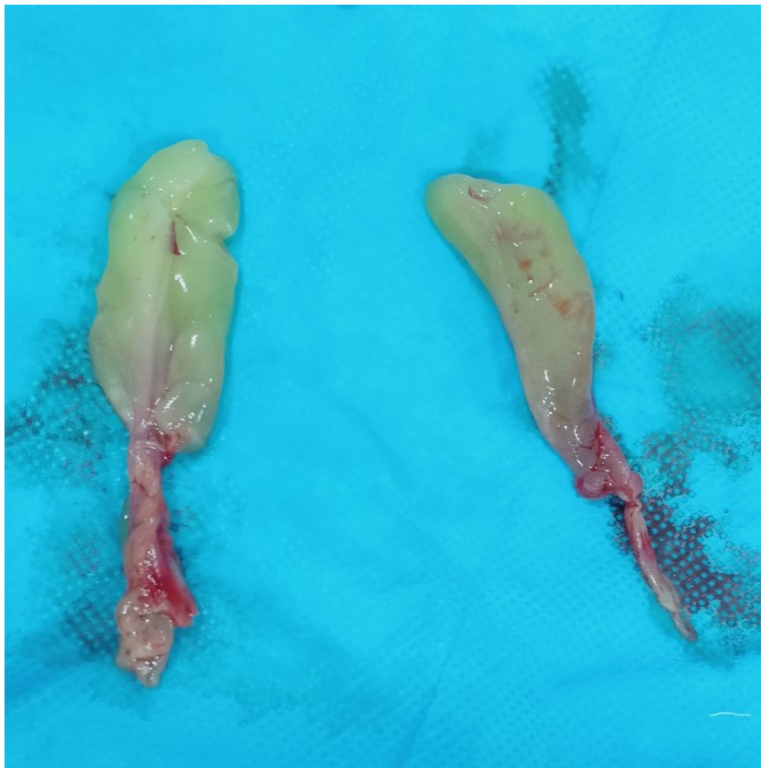The surgical procedure relied on functional endoscopic sinus surgery (FESS) under general anesthesia. It consisted of an uncinectomy, an antrostomy of the middle meatus, and a marsupialization of the polyps that were both implanted upon the uncinate process, and the polyps were then pulled through the oral cavity. The surgical intervention went on without any particular adverse event.



**Fig. 1** Coronal computed tomography (CT) scan sections of sinus cavities: showing an enlarged maxillary meatus, with blocked maxillary, frontal and sphenoidal sinuses, without bone defect



**Fig. 2** Sinus axial CT scan sections of sinus cavities



**Fig. 3** Macroscopic aspect of bilateral Killian polyps

No changes in surgical technique were necessary.

In immediate postoperative care, the patient received first-line analgesia; ablation of nasal packing was performed 24 h postoperatively. No adverse events were reported.

The macroscopic aspect is typical of an antrochoanal polyp (Fig. 3). Histological examination confirmed the diagnosis of a bilateral form of Killian polyps.

The 12-month postoperative endoscopic control showed that mucosa was undergoing a healthy recovery process; no signs of recurrence or other abnormalities were noted.

The patient adhered to treatment; no complaints were reported.

No adverse events were reported.

## Discussion

Antrochoanal polyps (ACP) are a rare form of polyps of the maxillary sinus in adults; the bilateral forms are even rarer [1–9]. Professor Killian was the first to describe an antrochoanal polyp in 1906 [1]. This polyp is generally implanted on the lateral and inferior wall of the maxillary sinus, most specifically inserted on the uncinate process [1–4]. It is seen mostly in adolescents and young adults, with no predilection for a certain gender. The

most frequent symptoms are related to a dysfunction in the sinus drainage: pus discharge, headache, and nasal obstruction. Prolapse into the oropharynx can be responsible for snoring [2]. Bilateral forms are very rare; they have the same benign prognosis as the unilateral forms [1–4].

## Etiological notions

The causes of antrochoanal polyps is still unclear: allergy, chronic rhinosinusitis, viral infections as well as bacterial ones are associated with a higher incidence of this benign tumor. Besides, anatomical variants that increase pressure inside the maxillary sinus are also incriminated in their formation (Fig. 4).

## Epidemiological notions

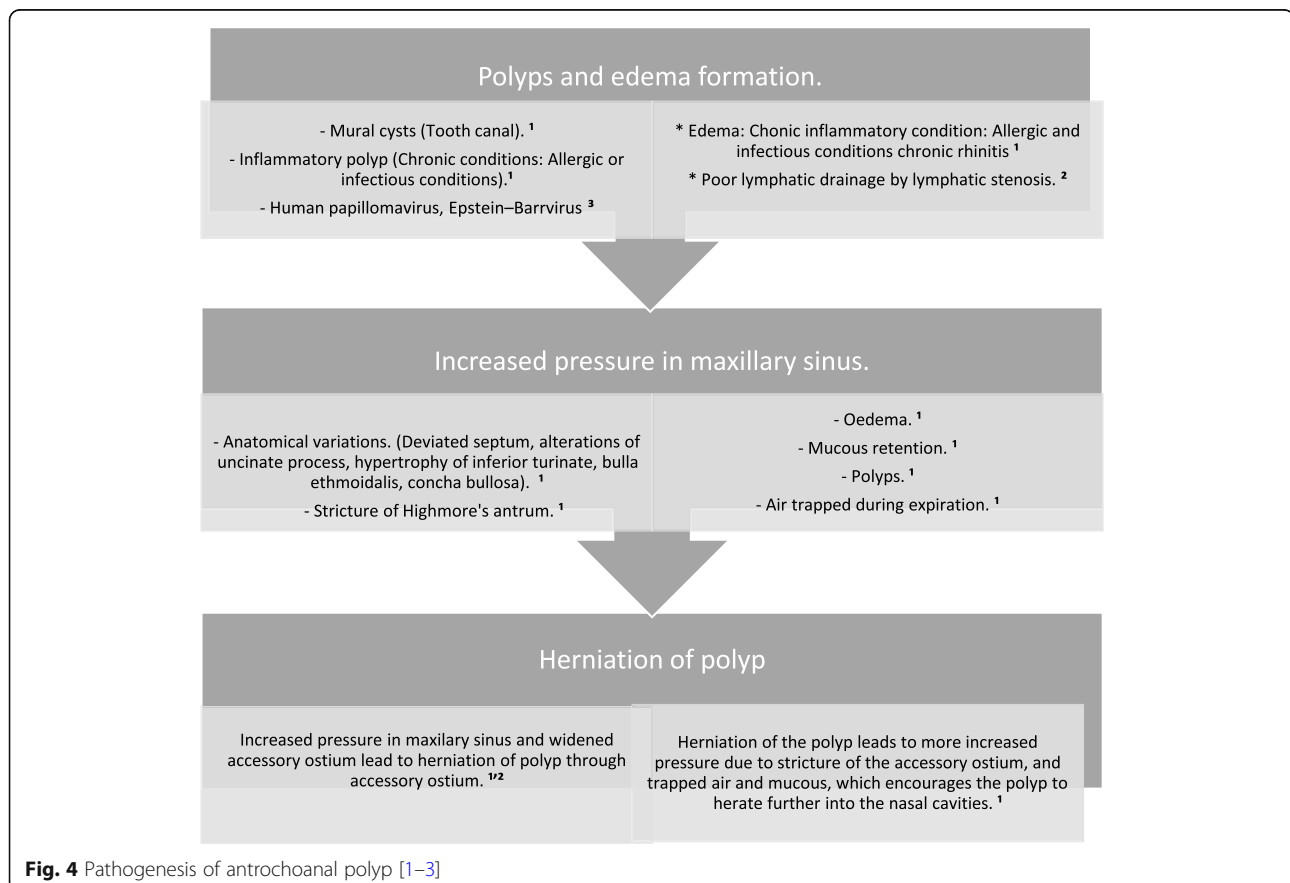
Ages of patients ranged from 6 years old to 62 (Fig. 5).

Among the 14 patients, we found 7 females and 7 males (Fig. 6).

Ethnic origin is shown in Fig. 7.

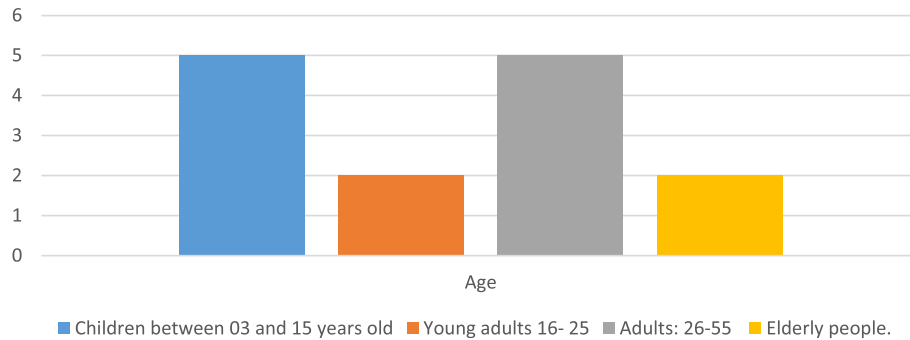
## Clinical presentation

The most common clinical presentation of ACP is nasal obstruction, sometimes bilateral, depending on the prolapse in the oropharynx [1–5]. Other symptoms are also





Age range of patients found in literature review.

**Fig. 5** Age range of patients found in literature review [8–21]

cited in the literature, such as epistaxis, rhinorrhea, posterior nasal discharge, anosmia, foreign body sensation, halitosis, and snoring [1].

#### Rhinoscopy findings

Often, ACP is present as a bright mass coming in the middle meatus, with a stalk through the accessory ostium, with the presence of an egg-shaped mass behind the uvula [1–5].

#### Radiological findings

Radiological investigation through computed tomography and/or magnetic resonance imaging, allows to see the origin of the mass, the sinuses involved, as well as the absence of extension to cranial cavity and orbital cavities [1–6].

In the CT (computed tomography) scan, the diagnosis of ACP is established upon the presence of a mass filling the maxillary sinus into the middle meatus through the maxillary ostium, and into the choanae [1]. In the

magnetic resonance imaging, the typical aspect is hypointense T1, enhanced T2 signals, and peripheral enhancement after gadolinium administration [1].

Shung et al. have established a radiological classification to antrochoanal polyps according to extension to nasopharynx and visibility of accessory ostium [6].

In Stage I, polyp does not reach nasopharynx.

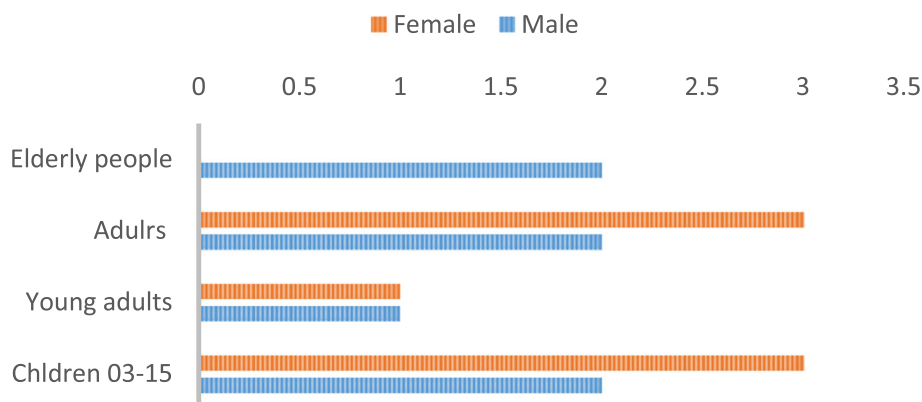
Stage II is defined as a polyp that goes through the accessory ostium of the maxillary ostium that is fully occluded.

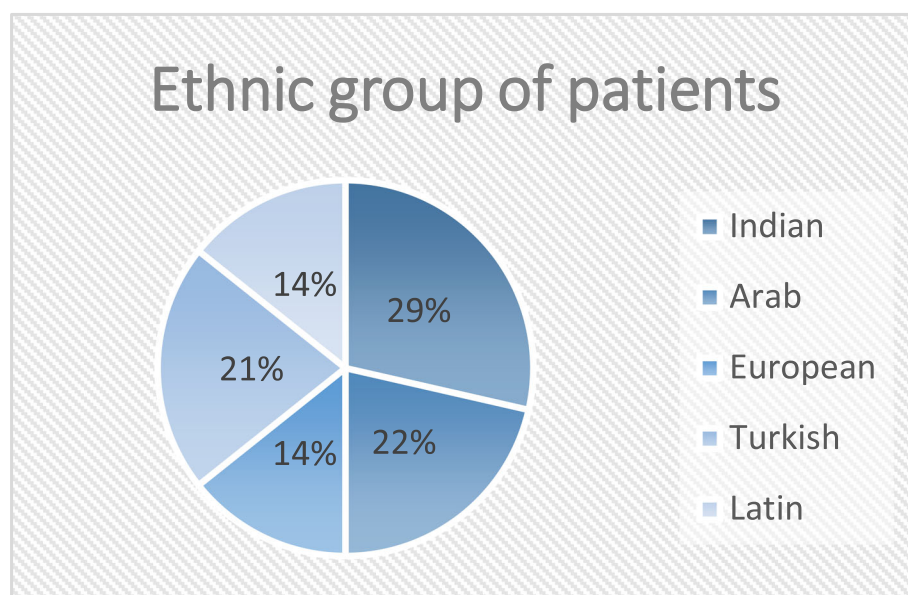
Stage III is defined when the antrochoanal polyp goes to the choanae, and the accessory ostium is partially occluded.

Besides, the same authors established a correlation between radiological aspect and histological findings, the more advanced the stage, the more important the inflammatory aspect in histological specimen [6].

Lee DH et al. find that children tend to present more advanced stages, which is explained by authors with late diagnosis in this age group [4].

GENDER REPARTITION IN AGE GROUPS

**Fig. 6** Gender repartition in age groups in patients with bilateral antrochoanal polyp [8–21]



**Fig. 7** Age ethnic groups in patients with bilateral antrochoanal polyps [8–21]

#### Matrix organizing findings in 14 cases

The matrix for organizing findings concerning 14 cases are found in the literature (Table 1) [8–21].

#### Macroscopic and histological aspects

Macroscopically, ACP appears like a white greyish mass, originating from the middle meatus into the nasal cavity, in some cases, with exteriorization into the oral cavity behind the uvula [1, 5]. Histological examination shows inflammatory polyps [1, 5]. The histological aspect shows infiltrates that are less inflammatory and eosinophilic than nasal polyposis [1, 4, 7, 8].

#### Differential diagnosis

Differential diagnoses are established upon clinical, endoscopic, and radiological findings (Table 2) [5].

#### Positive diagnosis

Histological aspect is the gold standard diagnostic tool. However, the combination of endoscopy and computed tomography, and MRI of sinonasal cavities in some cases can guide diagnostic reasoning [1, 4–6].

#### Management

However, mini-Caldwell and trans-canine have been described for good exposure and hence the complete removal of ACP [6]. However, the mini-invasive endoscopic technics by FESS (Functional endoscopic sinus surgery) is the gold standard surgical technic, since it has the same outcome with less risk of complications [1, 4–6].

The cornerstone of successful surgical removal of ACP is the identification and removal of its origin and bulk [5].

The surgical management though FESS is successful in most cases; the recurrent cases are due most probably to the growth of residual polypoid tissue in the maxillary antrum [6].

Establishing a communication between the natural maxillary ostium and the accessory ostium is key to avoid recirculation phenomenon postoperatively [4].

Shayasate et al. claim that recurrences are more frequent in children, and that follow-up for 24 months allows to diagnose 95% of recurrences [7].

Bilateral forms of antrochoanal polyp are very rare [1–4]. Establishing the right diagnosis and planning the surgical procedure are based on the presence of bilateral nasal obstruction, nasopharyngeal mass, the endoscopic aspect on preoperative evaluation and on computed tomography; the histological aspect confirms this diagnosis [1–9, 11, 14, 17–21].

#### Conclusions

Bilateral antrochoanal polyp is a rare benign condition that is very ill-lived by patients. Only 14 cases have been found in the literature. Strengths of this case reside in the presentation of a rare condition, presenting outside the age group in unilateral forms, and in a clinical context that had been misleading into considering other differential diagnosis.

It can be present in patients with all ages, and without particular pattern of gender predilection, early diagnoses upon clinical, endoscopic, and radiological and

**Table 1** Matrix for organizing findings in 14 cases found in literature [8–21].

	Age	F/ M	Ethnic origin	Medical history	Clinical presentation	Endoscopic aspect	CT scan aspect	Surgical technique	Preoperative finding	Macroscopic aspect	Histological aspect	Postoperative follow-up
Sinha SN et al. (1980) [8]	10	M	Indian	No allergy, injury, epistaxis, or any other disorder	Nasal obstruction (2 years). Signs of sinus congestion and infection (3 months)	Solitary bluish mass, attached to middle meatus	On X-ray, both antrums were blurry.	Polypectomy	Septum straight Choanae filled with polyps	Bluish mass	Inflammatory polyp	Not mentioned
Myatt HM et al. (1996) [9]	12	F	English	No allergy, no asthma, no other symptoms	Nasal obstruction + rhinorrhea (3 months)	Mass asymmetrical, left bigger in size	CT scan coronal section: quasi-total opacification of sinuses with liquid air levels	Tumor resection through FESS	The polyps were coming from the maxillary meatus into the nasal cavities, to the choanae.	Polyps	Inflammatory benign polyp	3 months without signs of recurrence
Basu et al. (2001) [10]	12	F	Indian	No allergy, no asthma, no other symptoms	Nasal obstruction and lump in throat (3 months)	Polyps, asymmetrical, right one bigger in size	CT scan: Mixte density mass, into nasal cavities and choanae, osteomeatal complexes widened	Caldwell-luck technique: Tumor resection and denudation of maxillary sinus walls	Polypoid maxillary sinus, cavities, polyp going to nasal cavities and choanae	Polyps	Inflammatory polyp	6 months
Jmeian S et al. (2006) [11]	6	F	Jordanian	No allergies	Nasal obstruction						Benign polyp	6 months, no recurrence.
Yilmaz et al. (2007) [12]	24	F	Turkish		Nasal obstruction, and oral mass	Bilateral greyish polypoid masses	CT identified soft tissue masses filling the maxillary sinuses and extending through the middle meatus into the choanae on both sides	FESS	Polyps passed through enlarged natural ostia of the maxillary sinuses on both sides	Greyish polypoid masses	Benign inflammatory nasal polyp for both lesions	No recurrence was observed in a 12-month follow-up period.
Konstantinidis I et al. (2008) [13]	49	F	German		Nasal obstruction			FESS			Benign	No 6 months
Sousa W et al. (2011) [14]	37	M	Brazilian	No allergies, asthma, or any other symptom	Nasal obstruction for 4 years	Polypoid tumor emerging from each maxillary sinus through widened ostia and extending to the nasopharynx	Computed tomography of the paranasal sinuses showed that the maxillary sinuses were filled with soft tissue density material that reached the nasal cavity and the choanae. The	Caldwell-Luc approach and FESS	Single cystic tumor that was implanted on the lateral wall	Cystic polypoid tumors	Benign	No 6 months

**Table 1** Matrix for organizing findings in 14 cases found in literature [8–21]. (Continued)

Age	F/ M	Ethnic origin	Medical history	Clinical presentation	Endoscopic aspect	CT scan aspect	Surgical technique	Preoperative finding	Macroscopic aspect	Histological aspect	Postoperative follow-up
Singhal P et al. (2011) [15]	32	F	Indian	No allergies	Nasal obstruction for 2 years, exacerbation in last 3 months Headache in last 6 months	other sinuses were normally aerated. Mass in maxillary sinuses, widening of maxillary ostea, mass filling choanae	FESS	No anatomical variation, polyps coming from middle meatus, filling nasal cavities into choanae	White polyps, glossy surface	Benign polyps	None mentioned
Sabino HA et al. (2014) [14]	48	M	Brazilian	No atopy, no ontological complaints, no headaches, no cacostmia, no asthma Allergy to nonsteroidal anti-inflammatory	Nasal obstruction for the last 30 years, bilateral, worse on the left side	Polypoid mass completely occluding nasal cavities, and going to the choanae Enlarged ostiomeatal complex	CT scan of sinuses: disclosed soft tissue masses on both nasal cavities, bilateral enlargement of ostiomeatal complex	FESS	Single large polypoid mass, in each nostril, coming from the medial wall of the maxillary sinus. Right conchae bullosa, edema and fluid retention in anterior and posterior ethmoid cells	Polypoid lesion, inflammatory	4 months postoperatively, no recurrence
Oner F et al. (2015) [17]	20	M	Turkish	Headache and pressure in the face for 6 months	Cystic fibroid mass protruding from middle meatus into the nasal cavity, and into the choanae, bilaterally	CT scan of sinuses: opacification of maxillary sinuses, and the presence of a mass protruding through middle meatus into choanae	FESS	The mass originated from the maxillary ostia to the choanae, bilaterally.	Cystic polypoid lesion	Benign polyp	None cited
Chodankar S et al. (2015) [18]	57	M	Indian	No history of asthma or allergy, no history of bleeding or any other sign	Bilateral nasal obstruction for the last 3 years. Increasing in symptoms in	CT scan showed mass through maxillary ostia to nasal cavities, into the choanae. Widening of ostio meatal complex was noticed.	FESS	Mass from middle ostia to the nasal cavities and into choanae	Mass polypoid, glossy surface	Inflammatory nasal polyp	None cited



**Table 1** Matrix for organizing findings in 14 cases found in literature [8–21]. (Continued)

	Age	F/ M	Ethnic origin	Medical history	Clinical presentation	Endoscopic aspect	CT scan aspect	Surgical technique	Preoperative finding	Macroscopic aspect	Histological aspect	Postoperative follow-up
Alashoura AS, et al. (2016) [19]	62	M	Saudi Arabian	No allergies, headache, sinusitis, epistaxis, or any other symptoms	Bilateral nasal obstruction for 6 years, worsened in the last few months	Solitary polyp in middle meatus		FESS	Solitary nasal polyp coming from middle maxillary meatus, to nasal cavities, and choanae		Inflammatory polyp	No occurrence in 6 months follow-up
Aksakal C et al (2018) [20]	11	M	Turkish	No allergies		Yellow polypoid mass	CT showed polyp extruding from middle meatus into the choanae	FESS	Polyps coming from maxillary ostia into the nasal cavity and the choanae		Inflammatory polyp	No recurrence in 8 months follow-up
Iziki O et al. (2019) [21]	44	F	Moroccan	No allergies, no asthma, no particular allergies	Nasal obstruction for 2 years	Pale polypoid masses from both nasal cavities		FESS			Inflammatory polyp	No recurrence in 12 months follow-up

**Table 2** Differential diagnosis established upon clinical, endoscopic, and radiological findings [5]

Benign:	Malignant:
- Nasal polyp	- Squamous cell carcinoma
- Mucous retention cyst	- Adenoid cystic carcinoma
- Antrochoanal polyp	- Adenocarcinoma
- Mucocele	- Esthesio-neuroblastoma
- Dacryocystocele	- Chordoma
- Nasal dermoid glioma	- Lymphoma
- Encephalocele	- Melanoma
- Osteoma	- Rhabdomyosarcoma
- Schneiderian papilloma	- Fibrous histiocytoma
- Juvenile nasopharyngeal angiofibroma	
- Hemangiopericytoma	
- Capillary hemangioma	
- Cavernous hemangioma	
- Vascular malformation	
- Granulomatosis with polyangiitis	
- Sarcoidosis	

histological findings is possible. And treatment is generally surgical, with excellent prognosis

### Patient's perspective

The patient claimed that nasal obstruction subsided along with all the other symptoms, with a significant improvement of his sense of smell.

### Abbreviations

ACP: Antrochoanal polyp; CRP: C-Reactive protein; FESS: Functional endoscopic surgery; CT: Computed tomography

### Acknowledgements

Not applicable

### Informed consent

The patient understood the conditions, the importance of different tests, the different steps of surgical management, the medical treatment, and the postoperative follow-up, and consented to the different steps of management, and publication.

### Authors' contributions

KC conceived and designed the analysis, collected the data, performed the analysis and wrote the paper. NT contributed data or analysis tools and wrote the paper. IN contributed in surgery. KN assisted in writing the paper. All authors approved the final version of the manuscript.

### Funding

None

### Availability of data and materials

Not applicable

### Declarations

### Ethics approval and consent to participate

Not applicable

### Consent for publication

A written informed consent for publication was obtained from the patient.

### Competing interests

The authors declare that they have no competing interests.

### Author details

<sup>1</sup>ENT and Cervico-Facial Surgery Department, Hassan II University Hospital, Fez, Morocco. <sup>2</sup>Faculty of Medicine and Pharmacy, Sidi Mohammed Ben

Abdellah University, Fez, Morocco. <sup>3</sup>ENT and Cervico-Facial Surgery Department, Moulay Ismail Military Hospital, Meknes, Morocco.

Received: 2 December 2020 Accepted: 18 March 2021

Published online: 12 April 2021

### References

- Frosini P, Picarella G, De Campora E (2009) Antrochoanal polyp: analysis of 200 cases. *Acta Otorhinolaryngol Ital* 29(1):21–26
- Piquet JJ, Chevalier D, Leger GP, Rouquette I, LeconteHoucke M (1992) Microchirurgie endo-nasale du polype antrochoanal. *Acta Otorhinolaryngol Belg* 46(3):267–271
- Yilmaz E, Alatas N, Ucar F, Cora T, Buruk K, Unlu Y (2019) Investigation of human papillomavirus (HPV) and Epstein-Barr virus (EBV) in antrochoanal polyps. *Am J Otolaryngol* 40(3):389–392. <https://doi.org/10.1016/j.amjoto.2019.02.008> Epub 2019 Feb 19. PMID: 30808528
- Lee DH, Yoon TM, Lee JK, Lim SC (2016) Difference of antrochoanal polyp between children and adults. *Int J Pediatr Otorhinolaryngol* 84:143–146. <https://doi.org/10.1016/j.ijporl.2016.03.004>
- Woodworth BA, Poetker DM, Reh DD (2016) Rhinosinusitis with nasal polyposis. *Adv OtorhinolaryngolBasel*, Karger 79:1–12. <https://doi.org/10.1159/000444957>
- Chung S-K, Chang B-C, Dhong H-J (2002) Surgical, radiologic, and histologic findings of the antrochoanal polyp. *Am J Rhinol* 16(2):71–76. <https://doi.org/10.1177/194589240201600201>
- Chaiyasate S, Roongrotwattanasiri K, Patumanond J, Fooanant S (2015) Antrochoanal polyps: how long should follow-up be after surgery? *Int J Otolaryngol* 2015:2974175 pages. <https://doi.org/10.1155/2015/297417>
- Sinha SN, Kumar A (1980) Bilateral antrochoanal polyps. *Ear Nose Throat J* 59(4):178–179PMID: 7363852. <https://doi.org/10.1177/014556138005900409>
- Myatt HM, Cabrera M (1996) Bilateral antrochoanal polyps in a child: a case report. *J Laryngol Otol* 110(3):272–274. <https://doi.org/10.1017/S0022215100133390>
- Basu SK, Bandyopadhyay SN, Bora H (2001) Bilateral antrochoanal polyps. *J Laryngol Otol* 115(7):561–562. <https://doi.org/10.1258/0022215011908225>
- Jmeian S (2006) Bilateral antrochoanal polyps in a child: an extremely rare case. *JRMS* 13(6):57–58
- Yilmaz YF, Titiz A, Özcan M, Tezer MS (2007) Bilateral antrochoanal polyps in an adult: a case report. *B-ENT* 3(2):97–99
- Konstantinidis I, Tsakiropoulou E, Vital I (2008) Bilateral antrochoanal polyps originated from inferior meatal anastomoses. *Laryngo-Rhino-Otol* 87(6):417–419. <https://doi.org/10.1055/s-2007-995464>
- Sousa DW, Pinheiro SD, Silva VC, Bastos JP (2011) Bilateral antrochoanal polyps in an adult. *Braz J Otorhinolaryngol* 77(4):539. English, Portuguese. PMID: 21860986. <https://doi.org/10.1590/s1808-86942011000400023>
- Singhal P, Gupta N (2011) Bilateral antrochoanal polyp in an adult: a rarity. *Clin Rhinol* 4(9):145–146
- Sabino HA, Faria FM, Tamashiro E, Lima WT, Valera FC (2014) Bilateral antrochoanal polyp: case report. *Braz J Otorhinolaryngol* 80(2):182–183. <https://doi.org/10.5935/1808-8694.20140037>
- Oner F, Sakat MS, Gozeler MS, Altas E, Uuncu H, Kilic K (2015) Bilateral antrochoanal polyp. *J Craniofac Surg* 26(7):e661–e662. <https://doi.org/10.1097/SCS.0000000000002072> PMID: 26468860
- Chodankar S, Tiwari M. Bilateral antrochoanal polyp in an elderly male—a rarity. *Odisha J Otorhinolaryngol* 2015;9.
- Alashoura AS, Alshaikh NA, Yeak S (2016) Bilateral antrochoanal polyps: a case report and literature review. *Pan Arab J Rhinol* 6(2):59–63. <https://doi.org/10.4103/2090-7540.200619>
- Aksakal C (2018) Bilateral antrochoanal polyp in a child. *J Craniofac Surg* 29(8):2368–2369. <https://doi.org/10.1097/SCS.0000000000004947> PMID: 30320689
- Iziki O, Rouadi S, Abada RL, Roubal M, Mahtar M (2019) Bilateral antrochoanal polyp: report of a new case and systematic review of the literature. *J Surg Case Rep* 2019(3):rjz074. <https://doi.org/10.1093/jscr/rjz074>

### Publisher's Note

Springer Nature remains neutral with regard to jurisdictional claims in published maps and institutional affiliations.