

Role of virtual bronchoscopy in foreign body inhalation in children

Mohamed A. Hassan^a, Tamer A. Youssef^a and Mohamed El-Gharib^b

Departments of ^aOtorhinolaryngology and ^bRadiodiagnosis, Ain Shams University, Cairo, Egypt

Correspondence to Tamer A. Youssef, MD, Department of Otorhinolaryngology, Ain Shams University, 3 Ahmed Sanan Street, Saint Fatima, 11361, Cairo, Egypt
Tel: +20 100 158 7000; fax: +20 237 797 164; e-mail: tayoussef@yahoo.com

Received 17 January 2013

Accepted 20 July 2013

The Egyptian Journal of Otolaryngology
2013, 29:249–253

Objective

To investigate the usefulness of three-dimensional images on the basis of multidetector computer tomography (MDCT) in the evaluation of suspected foreign body (FB) aspiration in children.

Patients and methods

A total of 28 children presented to Ain Shams University hospital with suspected FB inhalation. All patients underwent chest radiographs. Of the patients, eight with inconclusive history, physical examination, and negative radiograph findings for FB inhalation underwent MDCT. All patients underwent rigid bronchoscopy (RB) and the results were compared with the findings of chest radiographs and virtual bronchoscopy images.

Results

Four patients were negative by radiography and MDCT scan, and were subjected to RB, with no FB found. The other four patients who were negative by radiography turned out to be positive by MDCT and were subjected to RB, which was positive for FB in only 3 patients. MDCT had a negative predictive value of 100%, whereas its positive predictive value was 75%.

Conclusion

RB should always be performed as a first-line procedure in the presence of a combination of characteristic clinical and radiographic signs. In the other patients, the presence of FB can be confirmed by MDCT in order to reduce the negative RB rate.

Keywords:

bronchoscopy, foreign body, virtual bronchoscopy

Egypt J Otolaryngol 29:249–253
© 2013 The Egyptian Oto - Rhino - Laryngological Society
1012-5574

Introduction

Most of the cases of foreign body (FB) aspiration occur during early childhood, with a peak incidence between the ages of 10 and 24 months [1]. The negative predictive values for clinical history of FB inhalation, symptoms, physical examination, and soft tissue radiographs were shown to be 50, 57.1, 83.3, and 50.6%, respectively [2]. These numbers underscore the fact that history, physical examination, or radiological examination cannot reliably exclude an FB aspiration. Rigid bronchoscopy (RB) is the principal method used for the extraction of a tracheobronchial FB, but its use as a diagnostic tool implies a certain rate of negative exams, exposing the child to the risk of procedure-related and anesthesia-related complications [3].

The imaging with multislice computer tomography (CT) with realistic three-dimensional (3D) reconstruction and virtual bronchoscopy is exceptional, with a reported sensitivity of 100%. In one retrospective study of 51 patients, spiral CT had a sensitivity of 100%, a specificity of 66.7%, a positive predictive value of 93.3%, and a negative predictive value of 100% for detecting airway FBs when compared with findings on RB [4].

In this study, we investigated the usefulness of 3D images on the basis of multidetector computer tomography (MDCT) in the evaluation of suspected FB aspiration in children in order to reduce the negative RB rate.

Patients and methods

This prospective observational study was carried out in Ain Shams University Hospital between November 2011 and December 2012 following institutional review board approval and after obtaining parents' consent. A total of 28 children (16 females, 12 males) presented to the ENT department, Ain Shams University, during this period with suspected FB inhalation. All patients underwent posteroanterior and lateral view chest radiographs. Eight patients with inconclusive history, physical examination, and negative radiograph findings for FB inhalation underwent MDCT. Positive radiograph findings included detection of radio-opaque FB or its effects such as mediastinal shift, abnormal heart size, emphysema, or atelectasis.

CT scans were performed in these patients using a helical CT scanner (Acquilion 64; Toshiba Medical

Systems, Tokyo, Japan), with 2-mm collimation, 1.5 pitch, 120 kV, 100 mA, and a gantry rotation speed of 3608/s. Images were reconstructed at 1-mm intervals using a standard reconstruction algorithm. Scanning extended from the level of the thoracic inlet through the superior portions of the lung bases. The scan was performed under spontaneous breathing in all patients because of their inability to hold their breath. Neither of the patients was sedated because of a possible complication of sedation causing respiratory distress. No intravenous contrast agent was used. Then, all images were imported into the 3D reconstructive type to reconstruct the 3D images in the vendor workstation (Vitrea II; Toshiba Medical Systems). For the virtual bronchoscopy images, navigation through the tracheobronchial tree was performed interactively by the workstation monitor and a computer mouse until the FB was found. If any one of the images reconstructed found FB, the patient would be defined as positive. All patients were administered anti-inflammatory treatment to reduce airway inflammation and secretion; dexamethasone was applied before surgery to boost stress resistance and minimize edema in the larynx and trachea.

RB was performed in the operating room under inhalation anesthesia and the results were compared with the findings of chest radiographs and virtual bronchoscopy images.

Postoperative therapies aiming at containing inflammation, relieving cough, and eliminating sputum were administered generally for 3–5 days in the form of oral antibiotics and steroids.

Results

A total 28 children (16 females and 12 males), mean age of 2.5 years (range from 6 months to 14 years), presented to our department with suspected FB inhalation. Twenty patients had a positive radiograph finding either by the presence of radio-opaque FB in 11 patients or suggestive of FB inhalation in nine. The other eight patients had a radiograph finding not suggestive of FB inhalation and underwent MDCT. They were all children with a suspected history of FB aspiration, but three of them presented late (2–3.5 months) by repeated attacks of cough treated as bronchial asthma or with a nonresolving chest infection. In all patients, the disease course ranged from 2 h to 3.5 months, with a median of 18 days. The eight MDCT studies were free from motion artifacts. All of patients underwent RB, which indicated 17 cases with FBs.

Four patients were negative by radiography and MDCT scan, and were subjected to RB, with no FB found. The other four patients who were negative by radiography turned out to be positive by MDCT (Figs 1 and 2), and were subjected to RB, which was positive for FB in only three patients. Virtual bronchoscopy results were the same as MDCT and did not provide any new information.

Three children had 'false-positive' chest radiographs (Table 1) and one had a 'false-positive' MDCT (Table 2),

but RB failed to show any FB, except for abundant viscous mucous. The positive predictive value for radiograph was 85%, whereas its negative predictive value was 62.5%. In children with a suspected history and/or physical examination and nonconclusive radiograph findings for FB inhalation, MDCT had a negative predictive value of 100% and a positive predictive value of 75%. FB removal was performed successfully in 20 patients (17 with positive radiograph findings and three with positive MDCT but with negative radiograph) at the first attempt.

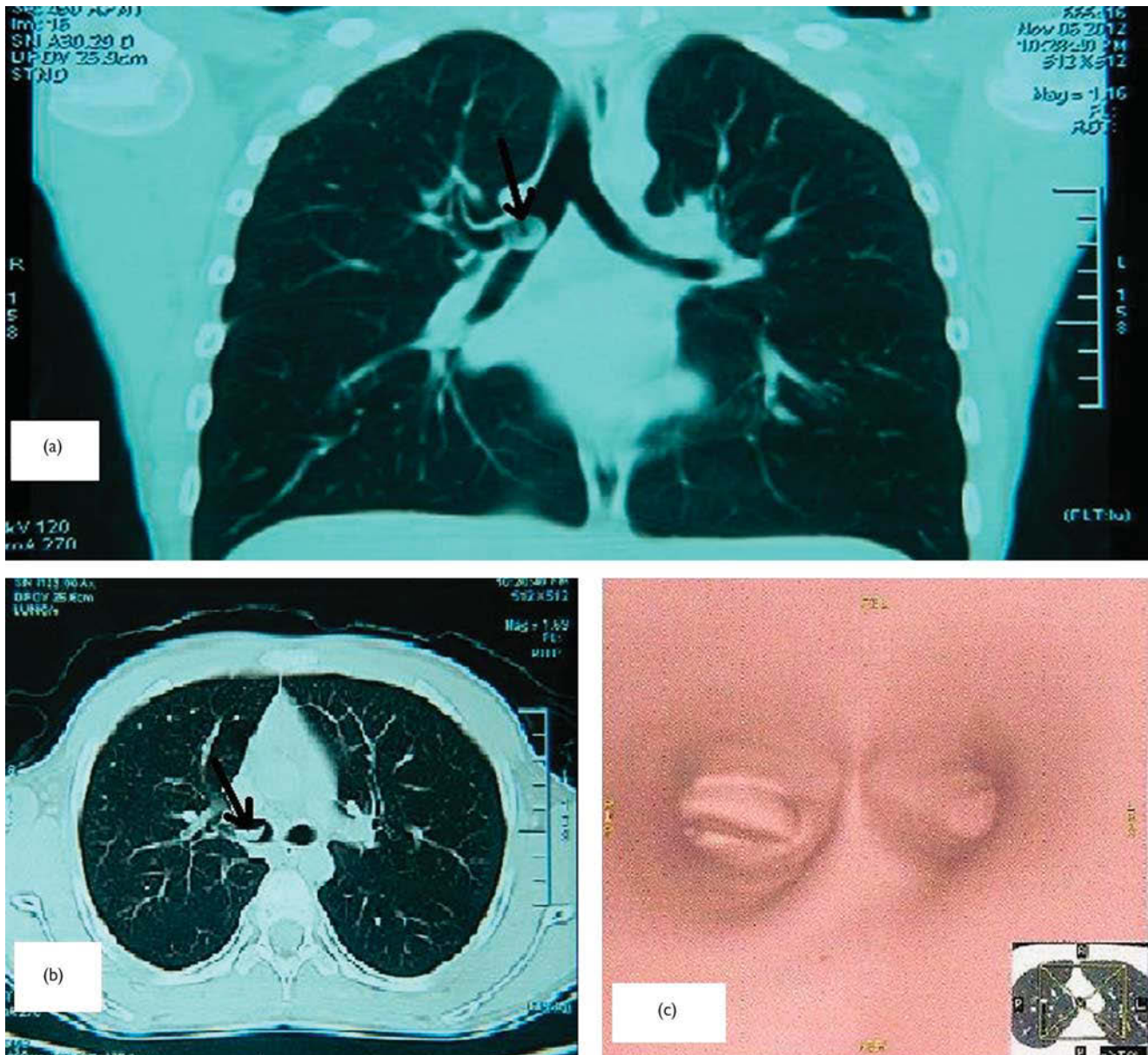
The location of the FB was the right main bronchus in 10 patients, the left main bronchus in seven patients, and the trachea in three. Both MDCT and RB showed the same location of the FB in three children. The nature of the removed FBs was organic such as peanuts fragments (eight patients) and water melon seeds (three patients) or nonorganic such as small plastic parts of toys (four patients) and hair pins (five patients, all older female children wearing a veil).

Discussion

The positive clinical diagnosis of bronchial FB in children is often difficult. There are no typical symptoms for FB aspiration, leading to a high misdiagnosis rate up to 25% [5]. Before a definite diagnosis of FB aspiration in children can be established, they are often misdiagnosed and treated as having upper respiratory tract infection, pneumonia, laryngitis, and asthma, resulting in prolonged or recurring symptoms, and causing a delay in diagnosis and more complications. FB aspiration mostly occurs in children younger than 3 years of age who cannot express themselves and their parents usually provide an unclear history and describe the condition as swallow of rather than aspiration of FBs [6,7]. Complementary investigations therefore play an essential role in children with a suspected bronchial FB, with the objective of decreasing the negative RB rate. Chest radiography is usually the first diagnostic study ordered, with a reported sensitivity and specificity of 72% to detect abnormalities consistent with an FB aspiration [8]. Thus, about one-third of patients with an FB aspiration have normal chest radiographs at the time of presentation [8–10]. This is in agreement with the current study as all the children had an unclear history of FB aspiration and chest radiography had a positive predictive value of 85%, whereas its negative predictive value was 62.5%. A doubt in terms of the diagnosis therefore sometimes persists after completion of the clinical assessment and chest radiography.

Recent progress in medical imaging, with the development of MDCT has decreased the acquisition time and improved image quality. 3D images on the basis of MDCT can provide virtual tracheobronchoscopy, thereby facilitating the management of bronchial FB in children by replacing RB in doubtful cases. According to Cevizci and colleagues, MDCT can be performed in children with minimal radiation risks, provided it is performed in line with the guidelines proposed by Paterson and Frush [11,12]. This examination can be performed in children without sedation,

Figure 1

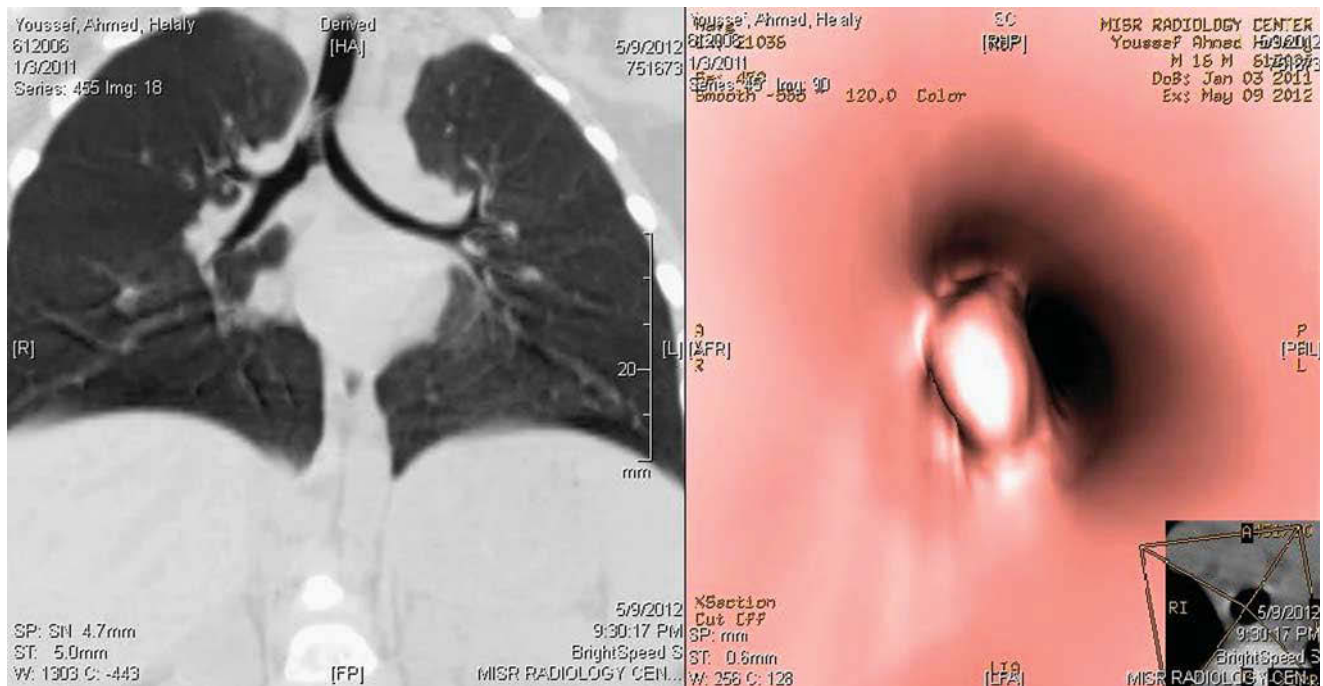


An 11-year-old girl with a query history of aspiration presented with repeated attacks of cough and was misdiagnosed and treated as bronchial asthma. Coronal (a) and axial (b) multidetector computer tomography (MDCT) images indicated a rounded foreign body in the right main bronchus (arrows). Virtual bronchoscopy (c) indicated a rounded foreign body in the right main bronchus, which showed a small plastic part of a toy in the right main bronchus and was successfully retrieved.

as it only takes a few seconds in a cooperative patient. In a retrospective review of 1007 patients with FB aspirations, Gang *et al.* [13] found that 84% ($n = 843$) of patients were in the bronchial tree. In our work, both MDCT and RB showed the same location of the FB. MDCT can reduce the RB operating time by providing the surgeon with precise information about the site and size of the bronchial FB. According to various studies, the sensitivity of MDCT for the detection of bronchial FB is close to 100%, with a specificity between 66.7 and 100% [12]. False positives are generally related to the presence of a mucus plug or artifact [14]. No false negatives have been reported to date, but the sensitivity of this examination cannot be determined reliably because of the small sample sizes of published series [15,16].

Our results are in agreement with this as no false-negative results were found in children with a suspicious history and with negative radiograph findings of FB aspiration. Both MDCT and RB showed the same location of the FB in three children. Therefore, we consider that the 3D images on the basis of MDCT might be taken as the ascertaining diagnosis method for suspected FB. One child had a false-positive result (12.5%) because of the presence of viscid secretions. Selection of specific criteria for children for MDCT decreased the examined number and increased the false-positive rate, but minimized the number of children exposed to radiation. Using this protocol, we had four false-positive cases (three cases with false-positive radiograph and one with false-positive MDCT). The misdiagnosis rate in this study was 14.3%,

Figure 2



As one and half years old male presented with unresolved chest infection for 1 month. Multidetector computer tomography and virtual bronchoscopy indicated small foreign body in the lower trachea. Rigid bronchoscopy indicated a small peanut in the lower trachea just before the right main bronchus.

Table 1 Radiograph results in the detection of foreign body aspiration in the 28 patients

| | Radiograph | False results | Predictive rate (%) | History of foreign body aspiration | Clinical examination |
|----------|------------|---------------|---------------------|------------------------------------|----------------------|
| Positive | 20 | 3 | 85 | 18 | 18 |
| Negative | 8 | 3 | 62.5 | 10 | 10 |

Table 2 Virtual bronchoscopy results in the detection of foreign body aspiration

| | Multidetector computer tomography | False results | Predictive rate (%) | History of foreign body aspiration | Clinical examination | Radiograph |
|----------|-----------------------------------|---------------|---------------------|------------------------------------|----------------------|------------|
| Positive | 4 | 1 | 75 | - | 8 | - |
| Negative | 4 | 0 | 100 | 8 (2 query history) | - | 8 |

which is better than studies using only radiograph [5], but worse than studies applying MDCT to all children with suspected FB inhalation [4,11,14].

According to our results, virtual bronchoscopy images and MDCT images provide equally valuable information in children with suspected FB aspiration and prevent unnecessary conventional bronchoscopic examinations. However, virtual bronchoscopy increased the total examination time and cost, and it did not provide additional information over MDCT images in the evaluation of FB aspiration. This is in agreement with the work of Kocaoğlu *et al.* [17], who concluded that virtual bronchoscopy only adds to the examination time and cost; it does not provide additional information over thin-section axial MDCT.

Most objects aspirated in children are organic and radiolucent, whereas only about 15% of the FBs are radio-

opaque [4,18]; this is in agreement with this study in children younger than 4 years of age as the most common inhaled FB was peanuts and small plastic toys. The tradition of wearing veil in females as early as 9 years in the Arabic culture increased the risk of radio-opaque FB aspiration in older females. In this work, five females (17.9%) had aspirated hair pins. It is important to raise awareness in adults to avoid placing pins and inedible objects in their mouths. Children younger than 3 years of age should not be allowed to eat peanuts and their play rooms should be cleaned of small objects that could be inhaled.

In clinical practice, MDCT assistance is needed in locating and defining the specific and accurate position of FB, especially when we could not find the FB in the main bronchus when it fell in distant small bronchus branch in the peripheral lung regions. RB should always be performed as a first-line procedure in the

presence of a radio-opaque, obstructive FB, or in the presence of a combination of characteristic clinical and radiographic signs. In the other patients, MDCT could be considered as a selective criterion for RB. Also, for those who are negative on MDCT, the performance of RB should not be considered temporarily.

Conclusion

A timely diagnosis is critical in ensuring the optimal clinical course for patients with suspected FB aspiration. In practice, RB should always be performed as a first-line procedure in the presence of a combination of characteristic clinical and radiographic signs. In the other patients, the presence of a FB can be confirmed by MDCT in order to reduce the negative RB rate.

Acknowledgements

Conflicts of interest

There are no conflicts of interest.

References

- 1 Zhijun C, Fugao Z, Niankai Z, Jingjing C. Therapeutic experience from 1428 patients with pediatric tracheobronchial foreign body. *J Pediatr Surg* 2008; 43:718–721.
- 2 Kiyan G, Gocmen B, Tugtepe H, Karakoc F, Dagli E, Dagli TE. Foreign body aspiration in children: the value of diagnostic criteria. *Int J Pediatr Otorhinolaryngol* 2009; 73:963–967.
- 3 Zaytoun GM, Rouadi PW, Baki DH. Endoscopic management of foreign bodies in the tracheobronchial tree: predictive factors for complications. *Otolaryngol Head Neck Surg* 2000; 123:311–316.
- 4 Hong SJ, Goo HW, Roh JL. Utility of spiral and cine CT scans in pediatric patients suspected of aspirating radiolucent foreign bodies. *Otolaryngol Head Neck Surg* 2008; 138:576–580.
- 5 Cataneo AJ, Cataneo DC, Ruiz RL Jr. Management of tracheobronchial foreign body in children. *Pediatr Surg Int* 2008; 24:151–156.
- 6 Torres de Amorim e Silva CJ, Fink AM. Case 137: pneumonia and bronchiectasis secondary to unrecognized peanut impaction. *Radiology* 2008; 248:1080–1082.
- 7 Jacob SS, Jacob JJ, Paul TV. Foreign body aspiration in a boy with Prader-Willi Syndrome. *Singapore Med J* 2008; 49:e12–e14.
- 8 Reilly J, Thompson J, MacArthur C, Pransky S, Beste D, Smith M, *et al.* Pediatric aerodigestive foreign body injuries are complications related to timeliness of diagnosis. *Laryngoscope* 1997; 107:17–20.
- 9 Chiu CY, Wong KS, Lai SH, Hsia SH, Wu CT. Factors predicting early diagnosis of foreign body aspiration in children. *Pediatr Emerg Care* 2005; 21:161–164.
- 10 Tan HK, Brown K, McGill T, Kenna MA, Lund DP, Healy GB. Airway foreign bodies (FB): a 10-year review. *Int J Pediatr Otorhinolaryngol* 2000; 56: 91–99.
- 11 Paterson A, Frush DP. Dose reduction in paediatric MDCT: general principles. *Clin Radiol* 2007; 62:507–517.
- 12 Cevizci N, Dokucu AI, Baskin D, Karadağ CA, Sever N, Yalçın M. Virtual bronchoscopy as a dynamic modality in the diagnosis and treatment of suspected foreign body aspiration. *Eur J Pediatr Surg* 2008; 18:398–401.
- 13 Gang W, Zhengxia P, Hongbo L, Yonggang L, Jiangtao D, Shengde W, *et al.* Diagnosis and treatment of tracheobronchial foreign bodies in 1024 children. *J Pediatr Surg* 2012; 47:2004–2010.
- 14 Haliloglu M, Ciftci AO, Oto A, Gumus B, Tanyel FC, Senocak ME, *et al.* CT virtual bronchoscopy in the evaluation of children with suspected foreign body aspiration. *Eur J Radiol* 2003; 48:188–192.
- 15 Tong B, Zhang L, Fang R, Sha Y, Chi F. 3D images based on MDCT in evaluation of patients with suspected foreign body aspiration. *Eur Arch Otorhinolaryngol* 2013; 270:1001–1007.
- 16 Bhat KV, Hegde JS, Nagalotimath US, Patil GC. Evaluation of computed tomography virtual bronchoscopy in paediatric tracheobronchial foreign body aspiration. *J Laryngol Otol* 2010; 124:875–879.
- 17 Kocaoglu M, Bulakbasi N, Soyulu K, Demirbag S, Tayfun C, Somuncu I. Thin-section axial multidetector computed tomography and multiplanar reformatted imaging of children with suspected foreign-body aspiration: Is virtual bronchoscopy overemphasized? *Acta Radiol*. 47; 2006. pp. 746–751.
- 18 Louie MC, Bradin S. Foreign body ingestion and aspiration. *Pediatr Rev* 2009; 30:295–301.