

Atypical superior semicircular canal dehiscence case report

Samir Asal

Department of Otorhinolaryngology, Faculty of Medicine, Audiology Unit, Alexandria University, Alexandria, Egypt

Correspondence to Samir Asal, MD, Department of Otorhinolaryngology, Faculty of Medicine, Audiology Unit, Alexandria University, 182 Omar Lofty Street Sporting Tram Station, Alexandria 21111, Egypt
Tel: +20 122 454 9955;
e-mail: samir_asal@yahoo.com

Received 21 November 2012

Accepted 8 February 2013

The Egyptian Journal of Otolaryngology
2013, 29:209–215

Superior canal dehiscence syndrome is a rare medical condition with many variants. In this case report, we present a 35-year-old patient who presented with atypical presentation of superior canal dehiscence syndrome. We discuss his audiological, vestibular, and radiological findings before and after surgery. We present a protocol to establish the diagnosis of a similar condition, especially those presenting atypically.

Keywords:

acoustic reflexes, autophony, conductive hearing loss, superior semicircular canal dehiscence syndrome, Vertigo

Egypt J Otolaryngol 29:209–215
© 2013 The Egyptian Oto - Rhino - Laryngological Society
1012-5574

Introduction

Superior canal dehiscence syndrome (SCDS) is a rare medical condition of the inner ear, first described in 1998 by Dr Lloyd B. Minor [1], leading to hearing and balance disorders in those affected [2–4]. The symptoms are caused by a thinning or complete absence of a part of the temporal bone overlying the superior semicircular canal of the vestibular system. This may result from slow erosion of the bone or physical trauma to the skull and there is evidence that the defect or susceptibility is congenital [5,6]. In ~2.5% of the general population, the bones of the head develop to only 60–70% of their normal thickness in the months following birth. This genetic predisposition may explain why this thinned section of temporal bone makes it more fragile and susceptible to damage through physical head trauma or from slow erosion. An explanation for this erosion of the bone has not yet been found [7].

Superior canal dehiscence (SCD) can affect both hearing and balance to different extents in different individuals [7]. Symptoms include autophony; this includes the individual's own speech or other self-generated noises (e.g. heartbeat, eye movements, creaking joints, chewing) that are heard unusually loudly in the affected ear.

Dizziness/vertigo/chronic disequilibrium caused by the dysfunction of the superior semicircular canal and Tullio phenomenon, sound-induced vertigo, disequilibrium or dizziness, nystagmus, and oscillopsia, are symptoms associated with superior semicircular canal disease (SSCD). Other symptoms include hyperacusis ear fullness in the affected ear, pulsatile tinnitus, brain fog, fatigue, and headache/migraine [8].

The presence of dehiscence can be detected by a high-definition (≤ 0.6 mm) coronal computed tomography (CT) scan of the temporal bone; currently, it is the most reliable way to distinguish between SCDS and other conditions of the inner ear involving similar symptoms such as Ménière's disease and perilymphatic fistula [8].

Other diagnostic tools include the vestibular evoked myogenic potential or the VEMP test, videonystagmography, electrocochleography, and the rotational chair test.

An accurate diagnosis is very important as unnecessary exploratory middle-ear surgery may thus be avoided. Several of the symptoms typical to SCDS (e.g. vertigo and Tullio) may also be present singly or as part of Ménière's disease, sometimes causing the one illness to be confused with the other. There are reported cases of patients being affected by both Ménière's disease and SCDS concurrently [8].

As SCDS is a very rare and still a relatively unknown condition, establishment of an accurate diagnosis of this distressing (and even disabling) disease may take some time as many health care professionals are not yet aware of its existence.

Case report

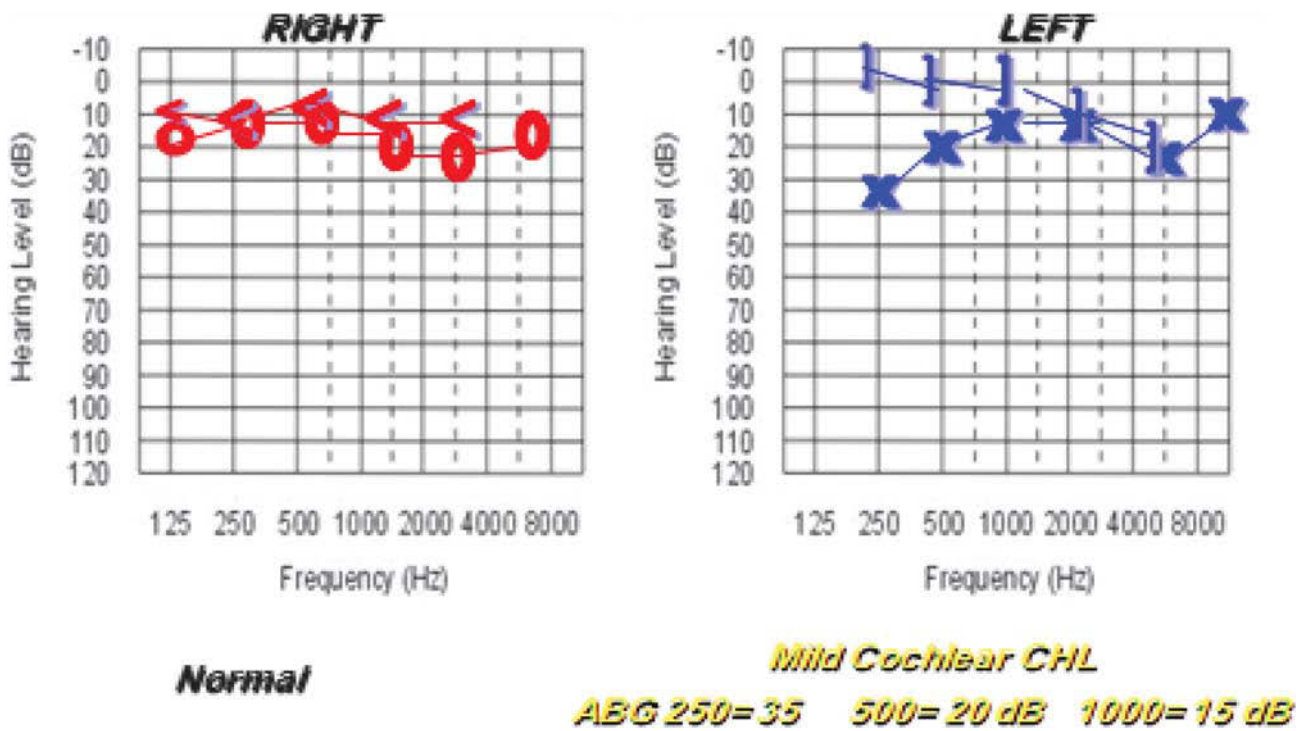
A 35-year-old Egyptian man presented with complaints of left ear autophony, left ear fullness, dizziness, and chronic disequilibrium since June 2007, that is, 2 months from examination of the patient. On detailed questioning of the patient, he reported that he tends to hear his eye movement in the left ear, and that his dizziness tends to be induced by loud sounds and coughing.

Otosopic examination revealed no abnormal findings. Tuning fork tests showed a positive Rinne test in both ears, with the Weber test lateralizing to the left ear.

Audiometric examination indicated normal hearing in the right ear; low-frequency hearing loss was detected in the left ear. Air-bone gaps in the left ear were 35, 20, and 15 dB HL at 250, 500, and 1000 Hz, respectively (Fig. 1).

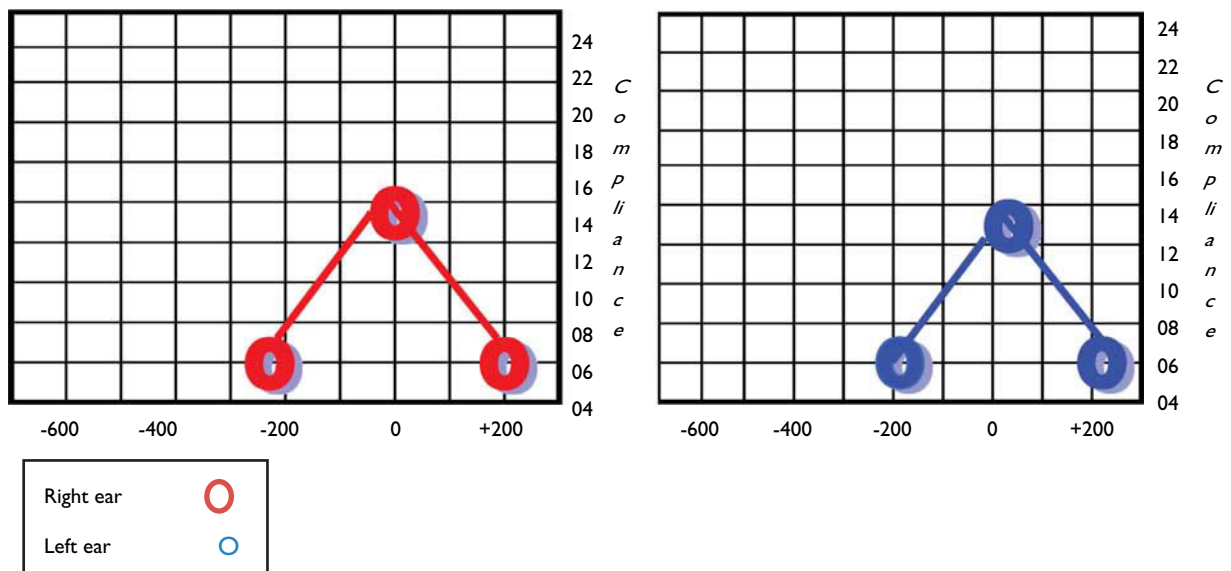
Tympanometry was performed; both ears were type A with intact reflexes. The presence of such an airborne gap in the presence of intact reflexes was highly suspicious of SSCD (Fig. 2, Table 1).

Figure 1



Pure tone audiogram at the time of diagnosis showing low-frequency conductive hearing loss (CHL) in the left ear.

Figure 2



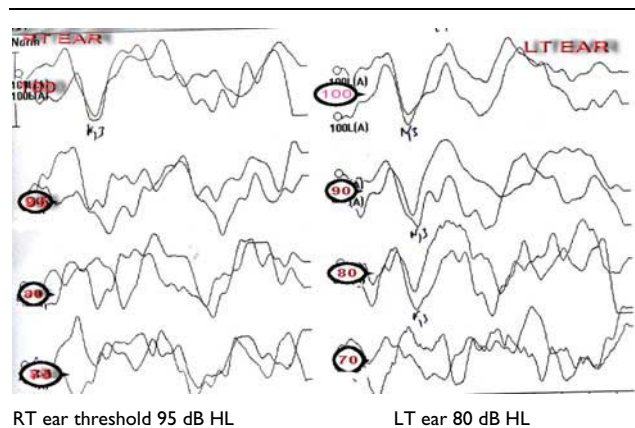
Tympanometry at the time of diagnosis showing bilateral type A.

Vestibular assessment was carried out. The standard videonystagmography tests, spontaneous nystagmus test, Gaze evoked nystagmus test, and oculomotor tests (Saccade, Pursuit, Optokinetic) all indicated the absence of spontaneous and gaze evoked nystagmus as well

Table 1 Acoustic reflexes threshold before surgery

Ear	Contralateral				Ipsilateral		
	500	1000	2000	4000	500	1000	2000
Right	95	90	95	100	90	90	95
Left	90	95	95	90	95	90	90

Figure 3



Vestibular evoked myogenic potential traces at the time of diagnosis showing decreased threshold in the LT. LT, left ear; RT, right ear.

as within normal performance at the oculomotor tests. Customized tests examining the vestibulo-ocular reflex in response to sound and pressure were carried out. Sound-induced mixed down beating vertical torsional nystagmus known as the Tullio phenomenon was positive in the left ear. The sound stimulus used was a 2000 Hz pure tone at 110 dB HL for 5 s. Changing the pressure in the external auditory canal using the tragus and tympanometry failed to elicit any nystagmus. Changing pressure in the middle ear by the Valsalva maneuver also failed to elicit any nystagmus. The head thrust test showed no corrective saccades in all three semicircular canal planes.

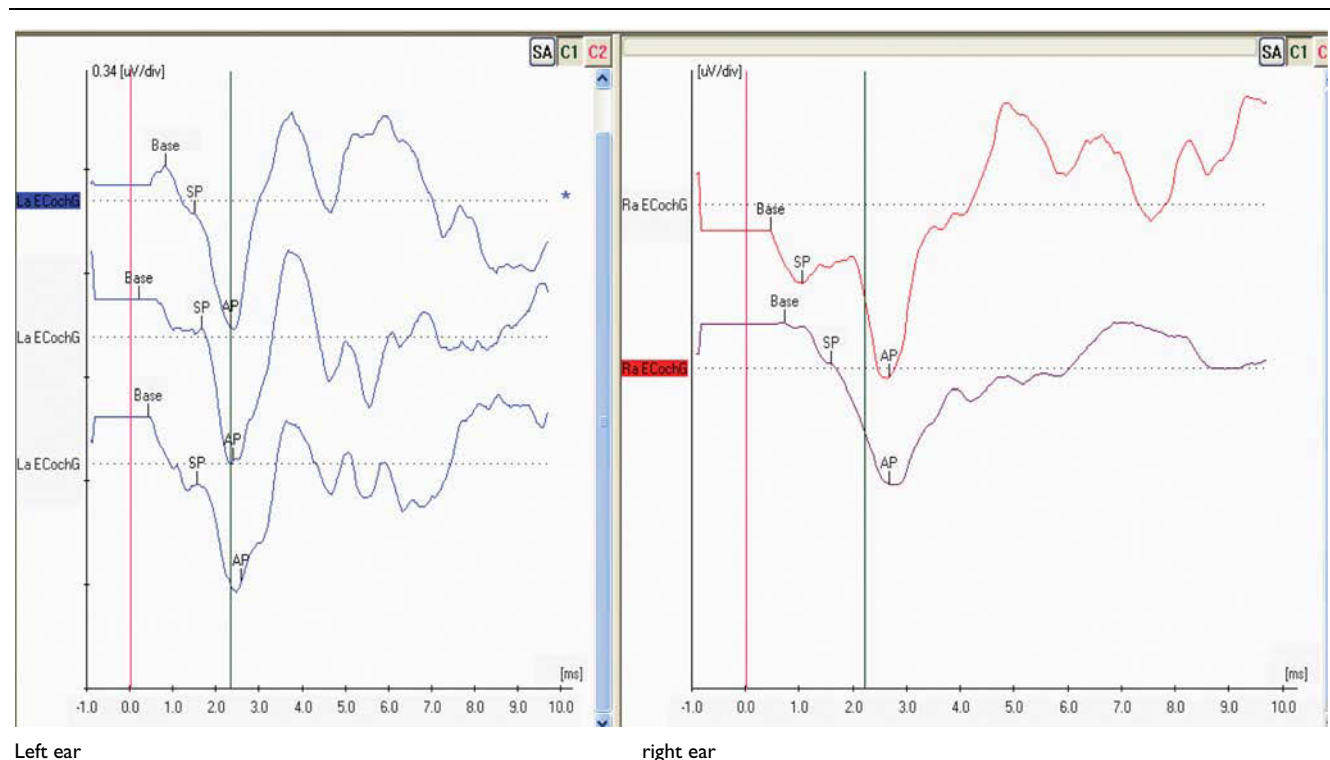
Measurement of the myogenic potential threshold induced by acoustic stimulation of the vestibular system (VEMP) showed a right ear threshold of 100 dB HL and a left ear threshold of 80 dB HL (Fig. 3).

EchoG showed an SP/AP ratio 0.28 for the left ear versus 0.23 for the right ear (Fig. 4).

Finally, the diagnosis was confirmed by the presence of left-side dehiscence on CT temporal bone.

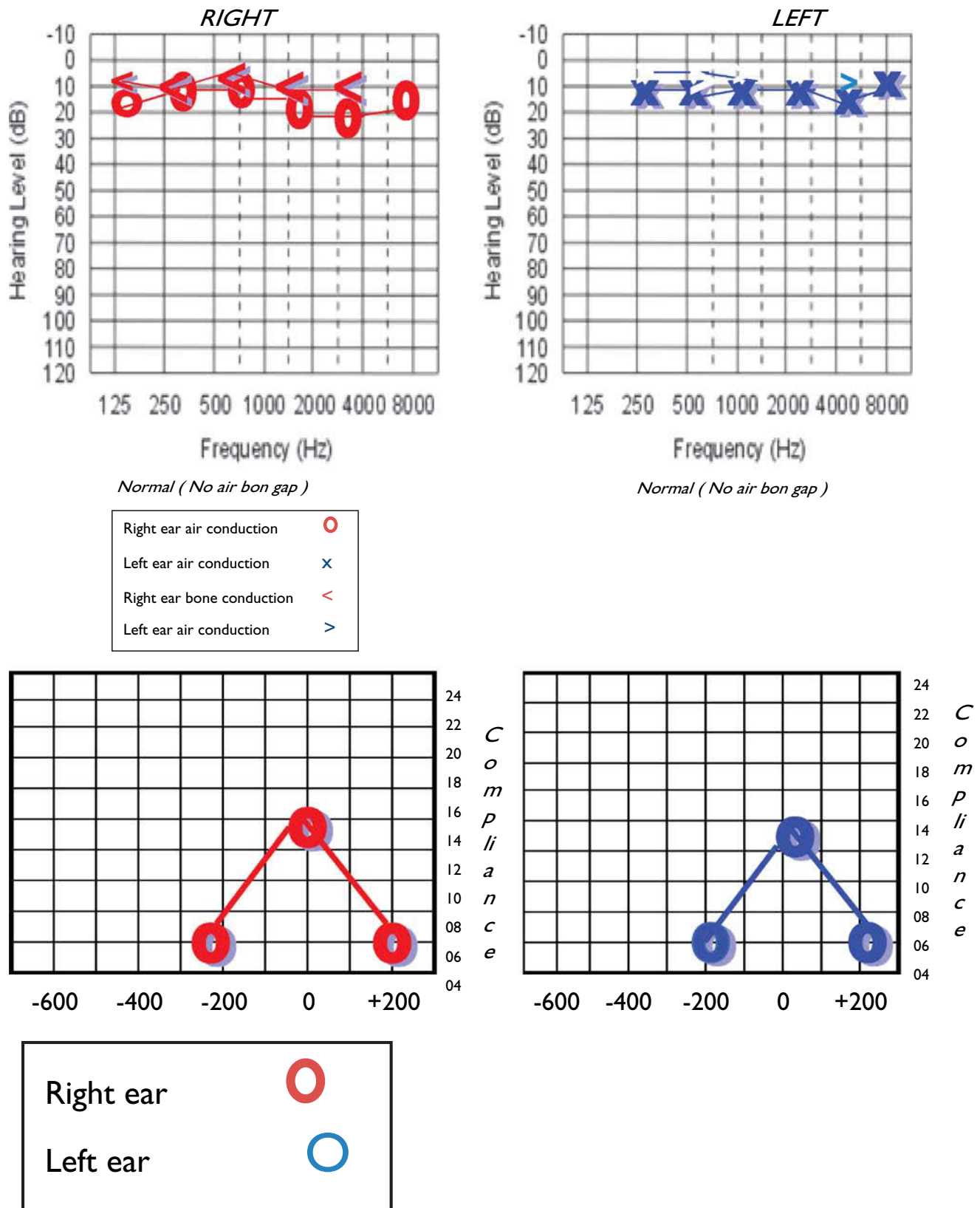
Surgical repair of the dehiscence by resurfacing using fascia and a bone graft was carried out. Postoperative assessment showed that complete reversibility of symptoms had occurred. The Rinne test was positive in both ears, with no lateralization of the Weber test. Audiometric examination indicated the absence of an air gap in the left ear, that is, bilateral within normal hearing (Fig. 5). No change was detected in the tympanometry and acoustic

Figure 4



EchoG traces at the time of diagnosis.

Figure 5



Pure tone audiometer after performing the operation.

reflexes (Table 2). On vestibular examination, the Tullio phenomenon was absent.

Measurement of the myogenic potential threshold induced by acoustic stimulation of the vestibular system (VEMP) showed a right ear threshold of 95 dB HL and a left ear threshold of 90 dB HL (Fig. 6).

Research involving the patient was approved by the institutional review board. All clinical investigations were performed according to the principles of the Declaration of Helsinki.

Discussion

In order to explain the pathophysiology of the process, Minor, who presented the first work describing the SSCD syndrome as an independent clinical entity, hypothesized that the absence of bone cover overlying the superior semicircular canal (SSC) was equivalent to a third window. This allows the movement of the cupula of the SSC to transmit the increase in the pressure to the round or oval window, or an increase in intracranial pressure [1].

Minor's hypothesis is also supported by experimental models based on laboratory animals [9,10], and it is currently the most accepted explanation in the medical literature.

Table 2 Acoustic reflex thresholds after the surgery

Ear	Contralateral				Ipsilateral		
	500	1000	2000	4000	500	1000	2000
Right	95	90	95	100	90	90	95
Left	90	95	95	90	95	90	90

The diagnosis of SSCD is made on the basis of the clinical history, the results of the physical examination, and radiological confirmation [11].

The clinical presentation of SSCD is variable. The most frequent forms of presentation are episodes of vertigo and oscillopsia induced by three possible causes [1,3,12].

- (1) Loud noises (Tullio's phenomenon).
- (2) Changes in pressure in the external auditory canal transmitted to the middle ear (Hennebert's sign).
- (3) Valsalva maneuver.

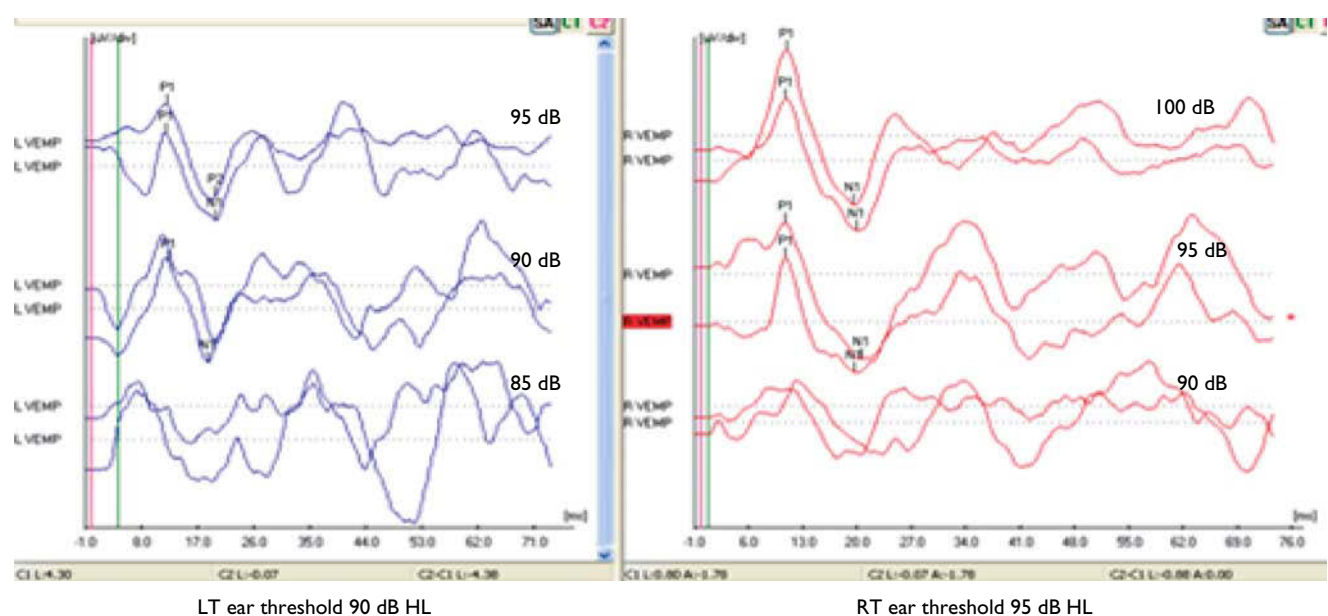
In many of these patients, the presence of a perilymphatic fistula at the level of the oval or the round window or Meniere's disease is suspected before any diagnosis of SSCD is made.

Another form of clinical presentation described in several of the most recent works is conductive hearing loss, in an isolated form or together with vestibular symptoms and signs.

The audiograms in these patients show that SSCD is associated with an air-bone gap of 10 dB or greater at lower frequencies for most ears with this disorder. This air-bone gap is not caused by a disorder in middle-ear conductive mechanisms because stapedius reflex responses are intact in these patients and middle-ear explorations (performed before the recognition of SSCD) have commonly indicated no abnormality [13,14]. It is likely that the same mechanism responsible for the vestibular abnormalities also underlies the auditory manifestations. The third mobile window allows acoustic energy to be dissipated through the dehiscence [13].

In the case of SSCD, rotational nystagmus is obtained in a clockwise direction that beats downwards, with an

Figure 6



Tympanometry after the operation.

amplitude of the turn between 1 and 7°, that of the vertical component between 1 and 5°, and that of the horizontal component less than 1.5°. Halmagyi *et al.* propose the presentation of clicks at 110 dB to reproduce nystagmus as a rapid screening test in patients with vertigo and suspicion of SSCD. This was found to be present in the patient [15].

Ampullofugal (excitatory) deflection of the cupula in the superior canal results from loud sounds, positive pressure in the external auditory canal, and the Valsalva maneuver against pinched nostrils. The eye movements resulting from these stimuli are conjugate (relatively equivalent for both eyes) and have slow phase components that are directed upward with torsional motion of the superior pole of the eye away from the affected ear. Conversely, negative pressure in the external canal, Valsalva against a closed glottis, and jugular venous compression cause ampullopetal (inhibitory) deflection of the cupula in the superior canal. The eye movements resulting from these stimuli are downward, with torsional motion of the superior pole of the eye toward the affected ear (i.e. in the same plane but opposite in direction to those resulting from the excitatory stimuli). These eye movement findings have been documented using three-dimensional search coil techniques and can be observed on clinical examination [16]. Frenzel lenses should be used when these observations are being made in the clinic because visual fixation can lead to suppression of the evoked eye movements. The case presented shows atypicality in that it showed no pressure induced nystagmus.

A longer length of dehiscence overlying the superior canal (5 mm) can lead to dysfunction in the affected canal [3,16]. The function in individual semicircular canals is evaluated by measuring the three-dimensional vestibulo-ocular reflex (VOR) induced by rapid, high-acceleration, transient head movements (head thrusts) in the planes of each of the canals [17,18]. Hypofunction in an individual canal leads to a deficient VOR caused by head thrusts that would result in an excitatory response from the canal if its function were intact. Quantitative evaluation of the three-dimensional VOR in response to head thrusts has shown that the VOR induced by excitation of the affected superior canal often has reduced gain when the dehiscence has a length of 5 mm or more. This reduced function in the canal may be caused by compression of the membranous canal by the overlying dura and temporal lobe. The eye movements caused by sound and pressure stimuli in these patients may not align with the plane of the superior canal when function in the canal is reduced [3,16].

VEMP responses have a lower threshold in SCD [11,19,20]. The mechanism responsible for the lowered VEMP threshold in these patients is also likely to be related to the lowered impedance for transmission of sound and pressure stimuli created by the third mobile window. Thus, the VEMP stimulus in an ear with SCD results in larger activation of the sacculus than a comparable stimulus in an ear without dehiscence. Lowered

thresholds for VEMP responses have also been reported in patients with an enlarged vestibular aqueduct [21].

The findings in this study indicate that the assessment of VEMP responses can be particularly useful in the search for the cause of an air-bone gap on audiometry. Conductive HL caused by a middle ear abnormality typically results in an absence of a VEMP response to click stimuli in the affected ear.

Surgery is performed using the middle fossa approach with fascia and hydroxyapatite cement placed over the bony defect. Surgical repair leads to a high success rate (93%). SCD is a highly treatable vestibulopathy once recognized. The success of treatment is high, with resolution of symptoms in greater than 90% of patients who require surgical intervention [22]. This is the case with the case presented, where on reversibility of the pathology and absence of the third window mechanism, reversibility was observed in symptoms and signs.

Conclusion

CT findings of dehiscence do not necessarily imply active clinical symptoms; therefore, the CT scan alone is not sufficient for the diagnosis of SSCD. Additional audiologic and vestibular studies are very useful for confirmation of clinically active SSCD. We suggest the following protocol to aid the diagnosis of SSCD: (a) assessment of medical history, (b) auditory manifestations; bone conduction hyperacusis, air-bone gap with intact acoustic reflexes, (c) vestibular manifestations; eye movement in the direction of the dehiscent superior canal caused by loud sound and pressure (external auditory canal, middle ear, or intracranial), VEMP threshold 85 dB HL or less, (d) high-resolution CT of temporal bone (0.5 mm sections).

Acknowledgements

Conflicts of interest

There are no conflicts of interest.

References

- 1 Minor LB, Solomon D, Zinreich JS, Zee DS. Sound- and/or pressure-induced vertigo due to bone dehiscence of the superior semicircular canal. *Arch Otolaryngol Head Neck Surg* 1998; 124:249–258.
- 2 Minor LB. Superior canal dehiscence syndrome. *Am J Otol* 2000; 21:9–19.
- 3 Minor LB, Cremer PD, Carey JP, Della Santina CC, Streubel S-O, Noah WEG. Symptoms and signs in superior canal dehiscence syndrome. *Ann N Y Acad Sci* 2001; 942:259–273.
- 4 Minor LB. Clinical manifestations of superior semicircular canal dehiscence. *Laryngoscope* 2005; 115 (10 1): 1717–1727.
- 5 Murray M. Old bone collection reveals basis for some dizziness. *The Hopkins Gazette* 8 March 1999; Vol. 28: NO. 25.
- 6 Duffy J. The clue in the old bones. *Hopkins Medical News* 1999. Available at: http://www.hopkinsmedicine.org/hmn/S99/mu_8.html.
- 7 Albuquerque W, Bronstein AM. 'Doctor, I can hear my eyes': report of two cases with different mechanisms. *J Neurol Neurosurg Psychiatry* 2004; 75:1363–1364.
- 8 Hopkins Medicine - symptoms & diagnosis of SCDS & mèneière's disease. Available at: <http://www.hopkinsmedicine.org/Otolaryngology/vestibular/patients.html>.
- 9 Hirvonen TP, Carey JP, Liang CJ, Minor LB. Superior canal dehiscence: mechanisms of pressure sensitivity in a chinchilla model. *Arch Otolaryngol Head Neck Surg* 2001; 127:1331–1336.

- 10 Carey JP, Hirvonen TP, Hullar TE, Minor LB. Acoustic responses of vestibular afferents in a model of superior canal dehiscence. *Otol Neurotol* 2004; 25:345–352.
- 11 Brantberg K, Bergenius J, Mendel L, Witt H, Tribukait A, Ygge J. Symptoms, findings and treatment in patients with dehiscence of the superior semicircular canal. *Acta Otolaryngol* 2001; 121:68–75.
- 12 Rhoton AL Jr., Pulec JL, Hall GM, Boyd AS Jr. Absence of bone over the geniculate ganglion. *J Neurosurg* 1968; 28:48–53.
- 13 Minor LB, Carey JP, Cremer PD, Lustig LR, Streubel S-O, Ruckenstein MJ. Dehiscence of bone overlying the superior canal as a cause of apparent conductive hearing loss. *Otol Neurotol* 2003; 24:270–278.
- 14 Mikulec AA, McKenna MJ, Ramsey MJ, Rosowski JJ, Herrmann BS, Rauch SD, *et al.* Superior semicircular canal dehiscence presenting as conductive hearing loss without vertigo. *Otol Neurotol* 2004; 25:121–129.
- 15 Halmagyi GM, McGarvie LA, Aw ST, Yavor RA, Todd MJ. The click-evoked vestibulo-ocular reflex in superior semicircular canal dehiscence. *Neurology* 2003; 60:1172–1175.
- 16 Cremer PD, Minor LB, Carey JP, Della Santina CC. Eye movements in patients with superior canal dehiscence syndrome align with the abnormal canal. *Neurology* 2000; 55:1833–1841.
- 17 Halmagyi GM, Curthoys IS, Cremer PD, Henderson CJ, Todd MJ, Staples MJ, D'Cruz DM. The human horizontal vestibulo-ocular reflex in response to high-acceleration stimulation before and after unilateral vestibular neurectomy. *Exp Brain Res* 1990; 81:479–490.
- 18 Cremer PD, Halmagyi GM, Aw ST, Curthoys IS, McGarvie LA, Todd MJ, *et al.* Semicircular canal plane head impulses detect absent function of individual semicircular canals. *Brain* 1998; 121:699–716.
- 19 Watson SRD, Halmagyi GM, Colebatch JG. Vestibular hypersensitivity to sound (Tullio phenomenon): structural and functional assessment. *Neurology* 2000; 54:722–728.
- 20 Streubel S-O, Cremer PD, Carey JP, Weg N, Minor LB. Vestibular-evoked myogenic potentials in the diagnosis of superior canal dehiscence syndrome. *Acta Otolaryngol Suppl* 2001; 545:41–49.
- 21 Sheykhleslami K, Schmerber S, Kermany MH, Kaga K. Vestibular-evoked myogenic potentials in three patients with large vestibular aqueduct. *Hear Res* 2004; 190 (1–2): 161–168.
- 22 Hillman TA, Kertesz TR, Hadley K, Shelton C. Reversible peripheral vestibulopathy: the treatment of superior canal dehiscence. *Otolaryngol Head Neck Surg* 2006; 134:431–436.