

Endoscopic reconstruction of skull base defects using a nasal septal flap in paediatric patients

Hossam M. El-Bosraty^a and Wael Shehata^b

^aDepartment of Otolaryngology, Cairo University and
^bDepartment of Otorhinolaryngology, October 6
University, Cairo, Egypt

Correspondence to Hossam M. El-Bosraty, MD,
Department of Otolaryngology, Faculty of Medicine,
October 6 University, Giza, Egypt
Tel: +01005684945; e-mail: bosraty@yahoo.com

Received 19 November 2012

Accepted 20 December 2012

The Egyptian Journal of Otolaryngology
2013, 29:159–165

Introduction

The repair of skull base defects after skull base surgeries is a major problem. Postoperative cerebrospinal fluid leak in reconstruction of the anterior skull base defect using a nasal septal flap was minimal when compared with other techniques. The nasal septal flap should be considered as the first line of treatment after transnasal endoscopic skull base surgery.

Objectives

Evaluation of the usefulness and reliability of endoscopic endonasal skull base reconstruction using a nasal septal flap.

Patients and methods

This study was carried out on 10 paediatric patients with skull base defects because of different pathologies. These patients were admitted in El-Kasr El-Ainy Hospital, Otorhinolaryngology Department. These patients included one patient with a germ cell tumour, five patients with a congenital encephalocele and four patients with skull base defects because of trauma to the skull base.

Results and conclusion

Various endoscopic techniques have been described to separate the cranial cavity from the sinonasal cavity to prevent infection, pneumocephalus and cerebrospinal fluid leak. Different techniques were used to close the anterior skull base defects such as multilayer free graft, suturing the dural defect combined with free graft and reconstruction based on a vascularized graft. The nasal septal flap should be considered as the first line of treatment after transnasal endoscopic skull base resections.

Keywords:

endoscopic, nasal septal flap, reconstructive, skull base defect, surgery

Egypt J Otolaryngol 29:159–165
© 2013 The Egyptian Oto - Rhino - Laryngological Society
1012-5574

Introduction

Surgery of the anterior skull base and infratemporal fossa has evolved over the past 40 years to incorporate a variety of open approaches, and more recently, endoscopic approaches. Endoscopic endonasal approaches for ventral skull base lesions have been developed in the recent era [1].

However, one of the challenges of endoscopic endonasal skull base approaches is the reconstruction of large defects of the skull base [2]. Closure of these skull base defects is performed to separate the cranial cavity from the sinonasal cavity to prevent infection, pneumocephalus and a cerebrospinal fluid (CSF) leak [3].

Various endoscopic techniques have been described for reconstruction of the ventral skull base defects to prevent CSF leak [4]. Previously, fat grafts were used or fascia lata with the insertion of external lumbar drain (ELD) for closure of large dural defects after the endoscopic endonasal skull approaches [5].

Recently, a nasal septal flap vascularized by the posterior septal branch of the sphenopalatine artery combined with a balloon catheter has been used without the insertion of lumbar drain for closure of large dural defects [6].

Spontaneous or iatrogenic leak after endoscopic sinus surgery tends to be small in size, less than 5 mm. These leaks are amenable to closure using some combination of underlayered bone, overlaid fascia and a free mucosal graft [7].

Advances in surgical techniques, instrumentation and intraoperative image guidance have enabled endoscopic removals of larger tumours with large dural defects [8]. The nasal septal flap based on the posterior naso-septal artery is easily harvested endoscopically and the procedure requires minimal extra training for endoscopic surgeons. It is suitable for large dural defects of the anterior, middle and lateral skull base [9].

Endoscopic endonasal skull base reconstruction using a nasal septal flap seems to be useful and reliable for ventral skull base defects after endoscopic endonasal approaches as combined with the previous single-layer reconstructions using free fat grafts or fascia lata [6].

Patients and methods

This study was carried out on 10 paediatric patients with skull base defects because of different pathologies. These patients were admitted in El-Kasr El-Ainy Hospital,

Otorhinolaryngology Department, from April 2009 to September 2011. These patients included one patient with a germ cell tumour, five patients with a congenital encephalocele and four patients with skull base defects because of trauma.

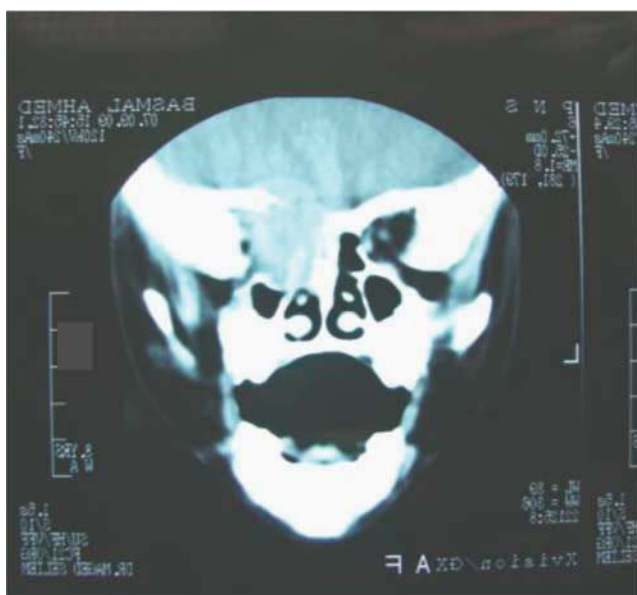All patients were subjected to the following:

- (1) Preoperative evaluation: assessment of personal and otorhinolaryngological history.
- (2) Otorhinolaryngological examination: full head and neck examination, general examination and endoscopic endonasal examination.
- (3) Radiological investigations: computed tomography (CT) scan and MRI.
- (4) Post operative follow-up:
 - (a) Early (after 1 week): clinical examination after removal of the nasal pack for crusts, CSF leak and other complications.
 - (b) Intermediate (after 3–4 weeks): clinical and endoscopic examination for viability of the flap, CSF leak and septal perforation.
 - (c) Late (after 6 months): clinical examination, endoscopic examination and radiological evaluation either by CT scan or by MRI to confirm complete healing of the defect.

Flap design and surgical technique

Initially, a vasoconstriction of the nasal cavity with oxymetazoline 0.05% is performed and the nasal septum is infiltrated with 0.5–1% lidocaine with adrenaline 1/200 000. Usually, the right middle concha is removed so that the skull base approach is performed, which makes the ipsilateral visibility of the vascular pedicle and the rise of the septal flap easy (Figs 1–9).

Figure 1



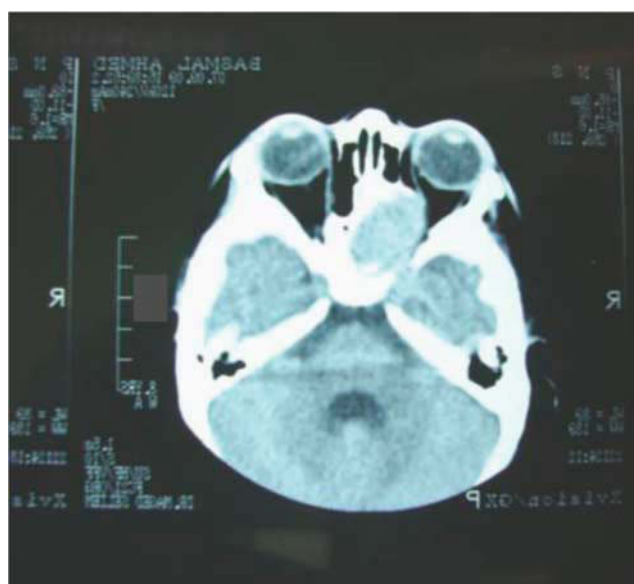Computed tomographic paranasal sinuses coronal cut of a 1-year-old patient with a right-side encephalocele.

The first incision (inferior incision) must be made parallel to the nasal fossa floor from the posterior to the anterior direction between the septum and the floor.

The second incision (superior incision) must be parallel to the first incision, maintaining 1–2 cm of distance of the nasal roof to preserve the olfactory neuroepithelium.

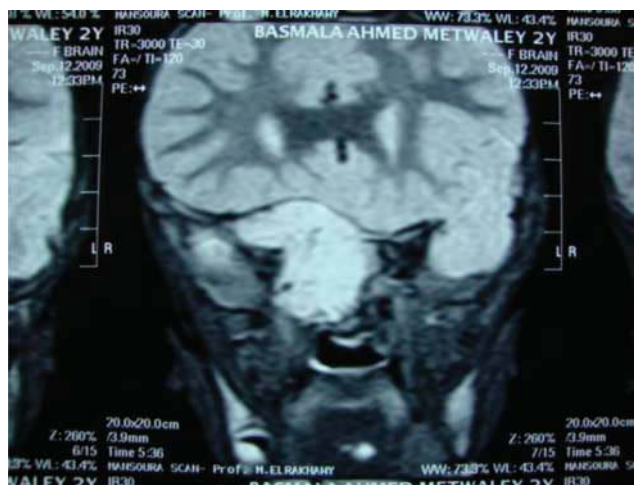
The two horizontal incisions must be joined by a vertical incision anteriorly, and these incisions can be modified in accordance with the specific area to be reconstructed. The two incisions are posteriorly extended in direction to the rostrum sphenoidale. The inferior incision is continued with a vertical incision in the posterior free edge of the nasal septum and then laterally at a level slightly below the sphenoidal sinus floor.

Figure 2



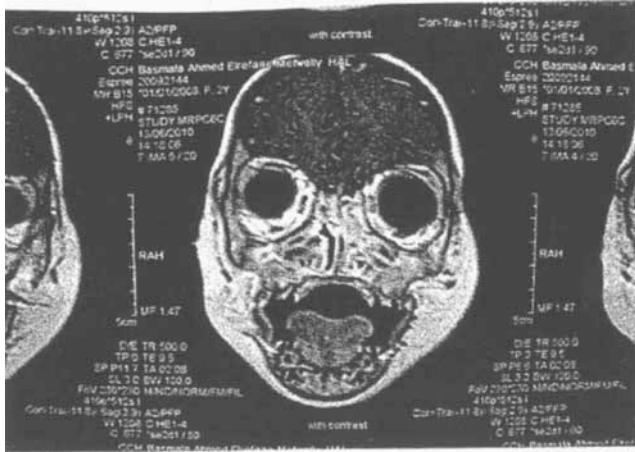
Computed tomographic paranasal sinuses axial cut of a 1-year-old patient with a right-side encephalocele.

Figure 3



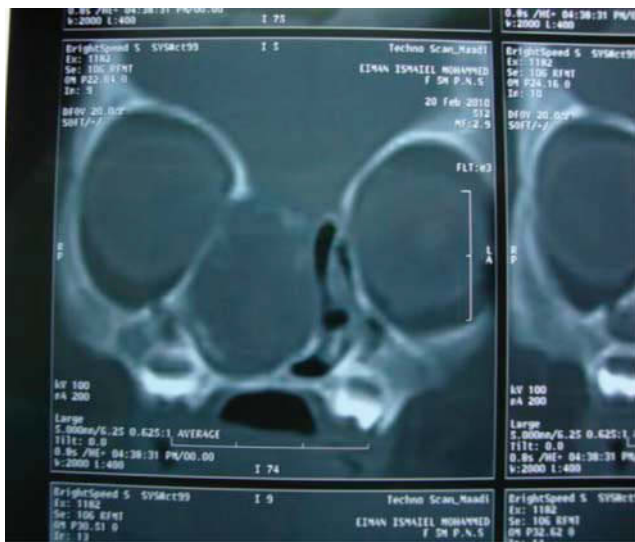MRI with contrast of a one and a half year old patient with a right-side encephalocele.

Figure 4



MRI coronal cut 6 months after surgery showing complete healing of the defect.

Figure 5



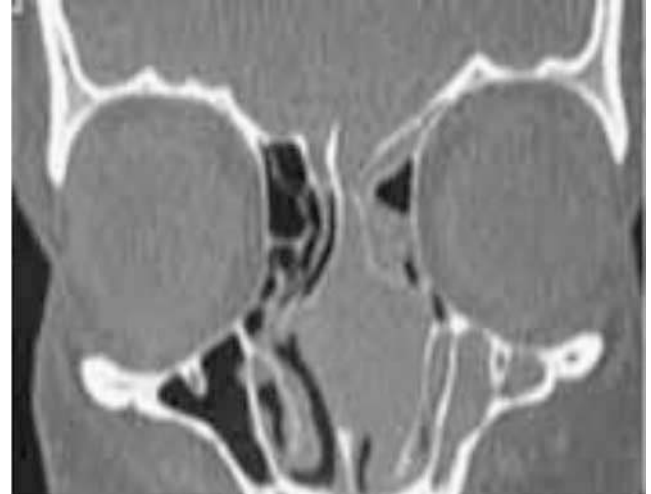Computed tomography paranasal sinuses of a 3-year-old patient's coronal cut showing germ cell tumour of the right side of the nose extended to the skull base.

The superior incision is extended with an incision that is immediately inferior to the sphenoid sinus ostium in the direction towards the sidewall of the nose. In this way, a narrow posterior pedicle is drawn containing the posterior septal artery. The rising of the flap of the mucoperichondrium and mucoperiosteum is initiated anteriorly with a Cottle elevator or another similar instrument. The elevation of the sphenoid anterior wall flap is carried through with the posterior-lateral preservation of the vascular pedicle.

Results

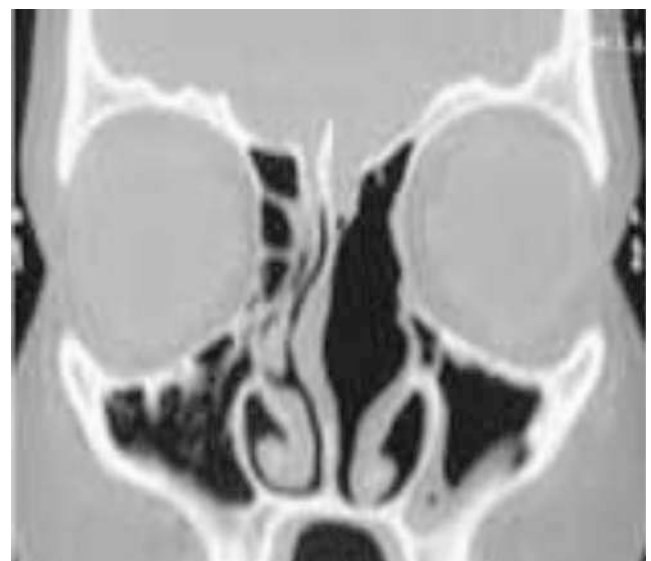All 10 patients with skull base defects because of different pathologies belonged to the paediatric age group (ranging in age from 1 to 15 years).

Figure 6



Computed tomography paranasal sinuses of a 5-year-old patient's coronal cut with a left skull base defect.

Figure 7

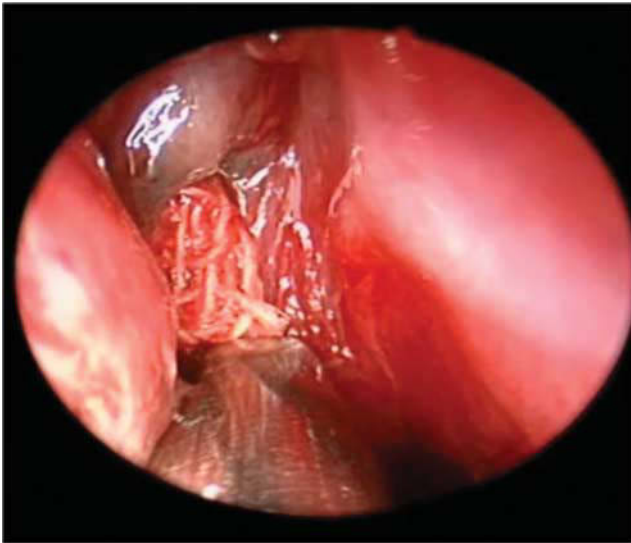


Computed tomography paranasal sinuses of a 5-year-old patient's coronal cut with a left skull base defect after reconstruction.

All patients were operated upon using the same standard technique and the same flap design for reconstruction by a nasal septal flap.

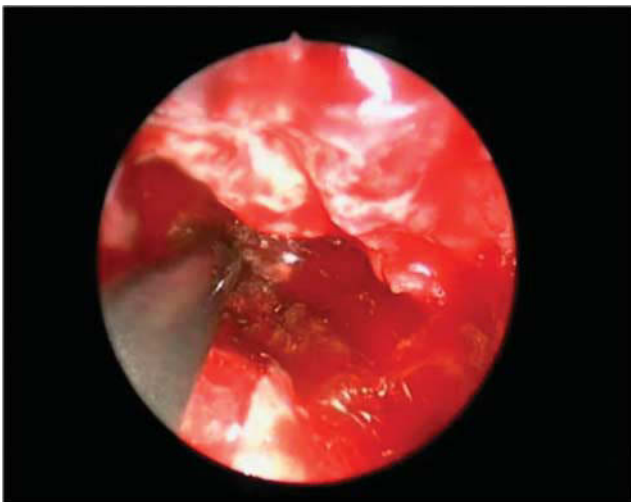
Our study included 10 paediatric patients with defects after skull base surgery because of different pathologies. All patients were prepared for surgery in the form of closure of the skull base defects using the nasoseptal flap (NSF) technique, which was standardized in all cases. The incidence of CSF leak after reconstructive endoscopic surgery by NSF was 10% (there was only one case with a large skull base defect because of a germ cell tumour). The defect was more than 5 cm and the leak occurred after removal of the pack. This patient with

Figure 8



Endoscopic photo image of a case of a congenital encephalocele.

Figure 9



Endoscopic photo of reconstruction of a skull base defect using a nasal septal flap.

a CSF leak was operated again and Duragen was used for complete sealing of the defect of skull base; follow-up was performed after surgery and no CSF leak was reported. All patients who underwent reconstruction by NSF were examined postoperatively and follow-up for 6 months, except two patients with a traumatic CSF leak, were missed on the long-term follow-up.

The data and the results of the 10 patients are reported in Tables 1 and 2.

Discussion

Endoscopic nasal surgery has evolved recently in the last decades with different techniques. Surgery of the

anterior skull base and infratemporal fossa has evolved over the past 40 years to incorporate a variety of open approaches and, more recently, endoscopic approaches. Endoscopic approaches for the anterior skull base lesions have been developed in the recent era [1]. Various endoscopic techniques have been described to separate the cranial cavity from the sinonasal cavity to prevent infections, pneumocephalus and CSF leak [4].

The closure of the skull base defects after skull base surgeries is a major problem. Previously, free grafts were used such as fat graft or fascia lata with the insertion of an ELD [5]. Recently, a nasal septal flap vascularized by the posterior septal branch of the sphenopalatine artery combined with a balloon catheter has been used without the insertion of the lumbar drain for large dural defects [6]. El-Sayed and Saleh [3] recommended the reconstructive technique using a NSF for closure of the skull base defects after skull base surgery.

In general, when a right-handed surgeon performs the surgery, the NSF is raised on the right side. The middle turbinate on the right side is resected along with the ethmoids and the posterior septum is then taken down to create a corridor that allows instruments to be passed on the left side and to create room for two surgeons to work together. A left-sided NSF is used when the right side of the NSF or its blood supply is threatened by tumour extension or preoperative embolization. Using this technique, 94% of NSF were harvested successfully whereas 6% of NSF were lost intraoperatively.

In the study of El-Sayed and Saleh [3], one NSF was split during harvest because of a large longitudinal septal spur. The septal spur was associated with thinning and friability of the flap mucosa. Several patients in his series had a history of previous septal nasal surgery and in this situation, elevation of NSF is more difficult. According to the results of his series, none of the patients had a postoperative CSF leak, supporting the initial literature indicating a CSF leak rate of 5%. Previous nasopharyngeal radiation was found to be a risk factor for NSF necrosis. Only 6% of flaps necrosed postoperatively and yet no CSF leak occurred in either case.

In our series, one of the problems during surgery is the technical difficulty because of a narrow field, especially in infants, but with the use of special instruments and meticulous techniques, all cases were harvested successfully.

A previous report of 43 patients who underwent closure of the NSF obtained a CSF leak rate of 5% [6]. In our series, none of the patients had risk factors such as large longitudinal septal spur, history of previous nasal surgery or previous nasopharyngeal radiation. According to El-Sayed and Saleh [3] the CSF leak rate increased when larger defects were approached; however, these data support the rate of NSF closure for smaller defects up to 4–5 cm in size. In these smaller defects, the CSF leak is less than that in open procedures. A few large dural defects up to 6.2 cm were also closed successfully,

Table 1 Patients with skull base defects because of different pathologies

	Case 1	Case 2	Case 3	Case 4	Case 5
Diagnosis	Right-side encephalocele Figs 1 and 2	Germ cell tumour Fig. 5	Left-side encephalocele	Right-side encephalocele after nasal surgery	Left-side CSF rhinorrhoea
Age (years)	1	3	4	13	14
Symptoms	Right nasal obstruction	Right nasal obstruction and discharge	Left nasal obstruction	Right nasal obstruction and discharge	Left-side nasal discharge after trauma
Signs	Right proptosis and right nasal mass	Right proptosis and right nasal fleshy mass	Left-side nasal mass	Right nasal mass and clear nasal discharge	Watery nasal discharge
Special modifications	No	CSF leak after removal of pack and Duragen used and complete sealing of the defect	No	No	No
Follow-up and complications	Complete healing with no complications	Complete healing with no complications	Complete healing with no complications	Complete healing with no complications	Complete healing with no complications

CSF, cerebrospinal fluid.

Table 2 Patients with skull base defects because of different pathologies

	Case 6	Case 7	Case 8	Case 9	Case 10
Diagnosis	Right-side encephalocele Figs 8 and 9	CSF rhinorrhoea post traumatic	CSF rhinorrhoea Figs 6 and 7	Right-side encephalocele Figs 3 and 4	CSF rhinorrhoea post-traumatic
Age (years)	3	1.5	5	1.5	12
Symptoms	Right nasal obstruction	Unilateral clear nasal discharge	Unilateral clear nasal discharge	Right nasal obstruction	Unilateral clear nasal discharge
Signs	Right proptosis and nasal mass	Unilateral watery nasal discharge	Unilateral watery nasal discharge	Right nasal mass	Unilateral watery nasal discharge
Special modifications	No	No	No	No	No
Follow-up and complications	Complete healing with no complications	Complete healing with no complications	Complete healing with no complications	Complete healing with no complications	Complete healing with no complications

CSF, cerebrospinal fluid.

indicating that the NSF is also useful for large defects of the skull base.

In the early postoperative period, many patients likely have a CSF leak as the wound is not closed in a watertight manner and the wound requires time to mucosalize. Further, most patients are noted to have nasal drainage while the merocel packs are in, even without CSF leak noted during surgery. However, no patients had detectable CSF rhinorrhoea at the time of merocel packing removal on postoperative day 10. Postoperative CSF leak in our series occurred in the patient with a germ cell tumour after removal of the nasal pack because of a large defect (5.5 cm) and the patient was operated again using Duragen with complete sealing of the defects without CSF leak.

One criticism of the NSF is that it may not cover the wound completely and that it may shrink by 20–40% over time. When fat was not used, the NSF was applied directly on the defect and covered it entirely. When fat was used, the fat covered the entire defect but the NSF did not always cover the entire fat graft. The NSF provides a base of healing mucosa that is expected to remucosalize over the nonvascularized graft 'fat' through epithelial cellular migration. Once a healthy base of mucosalized epithelium is established, it is unlikely that flap shrinkage would subsequently result in CSF leak. It seems likely that if a small CSF leak persisted after the first closure, a subsequent repair with a fat graft or free mucosa could be attempted. Flap shrinkage has been noted postoperatively when the pedicle is free-floating in the air, and it is recommended that the pedicle of the flap be lined on bone along its length to reduce shrinkage. The patient who required radiation after surgery for malignant lesions of paranasal sinuses usually started 6 weeks after surgery; NSF can be used to close the extracranial wounds without a CSF leak and if the NSF is considered, it must be raised at the beginning of the surgery to preserve it [8].

After open anterior craniofacial resection, some surgeons use rigid materials (such as bone, cartilage, synthetic materials) to support the anterior cranial fossa in conjunction with a pericranial flap to prevent brain herniation in large defects [10]. Synderman *et al.* [2] examined surgical skill acquisition and recommended a staged approach for learning endoscopic direction techniques.

Overall, although the NSF appears easy to harvest and manipulate, there are factors that may predict difficulty in raising the NSF including deviated septum, septal spur, an existing perforation and previous septal surgery. Other factors that should be considered in the patient's history include cocaine use, vasculitic diseases or those predisposed to poor wound healing such as chronic steroid therapy or hypothyroidism. Potential morbidity exists with the use of the NSF if the flap is taken too high along the skull base. Olfactory fibres can be injured, which may result in anosmia. In cases where the olfactory bulb is intact, if the flap is elevated on one side, patients still have functioning olfactory fibres on the contralateral

side. Nasal crusting is pronounced for several weeks after surgery and may persist indefinitely. However, all patients could be managed with home saline irrigations and infrequent debridement after the initial postoperative period.

One of the challenges of the endoscopic endonasal skull base approaches is reconstruction of large defects [9], which differs from the reconstruction of small defects after traditional pituitary surgery. Many reconstructive techniques have been proposed to prevent CSF leak after traditional trans-sphenoidal surgery [11]. Postoperative CSF leak occurred in 3.9% of patients after standard trans-sphenoidal surgery, according to the national surgery of USA [12]. Postoperative CSF leak occurred in 10% of patients after extended trans-sphenoidal approaches with ventral skull base lesions [13]. Skull base reconstructions of large dural defects after endonasal skull base approaches are generally divided into three groups at present. The first group involves reconstruction based on a vascularized graft, as in our series [3]. The second group involves reconstruction based on multilayer free grafts [14]. The third group involves suturing dural defects combined with the free graft [15].

In particular, the use of a vascularized graft is considered to make skull base reconstruction firmer than the free fat grafts [3]. Postoperative CSF leak occurred in 4.6% of patients who underwent reconstruction by a pedicled flap [6]. Whether or not ELD should be inserted remains debatable [16]. In the single-layer reconstruction using only fat grafts or the fascia lata, the insertion of ELD was considered to prevent or treat a CSF leak through large skull base defects [5]. However, it is not routinely considered to insert ELD postoperatively with reconstruction using a nasal septal flap in previous studies [17].

CSF leak could be prevented in all reconstructions using a nasal septal flap combined with fat grafts except in the reconstruction after resection of craniopharyngiomas, which involves the third ventricle. Craniopharyngiomas involving the third ventricle floor tend to cause CSF leak [9] because of the direct connection between the third ventricle and the suprasellar cistern after removal of the tumour. Excessive CSF pressure may be applied on the septal flap or the occult elevated intracranial pressure may be related to craniopharyngiomas involving the third ventricle [18]. Therefore, it is important to confirm the length of the nasal septal flap using CT scans in order to harvest a sufficiently large flap [19].

Conclusion

Various endoscopic techniques were used to close the anterior skull base defects such as multilayer free graft, suturing the dural defect combined with free graft and reconstruction based on a vascularized graft. The most recent technique used a vascularized nasal septal flap based on the posterior nasoseptal artery and it is considered the first line of treatment after transnasal endoscopic skull base resections not only because of the

easy technique but also because of the lower incidence of postoperative CSF leak.

Acknowledgements

Conflicts of interest

There are no conflicts of interest.

References

- 1 De Divitiis E, Cavallo LM, Cappabianca P, Esposito F. Extended endoscopic endonasal trans-sphenoidal approach for the removal of suprasellar tumours: part 2. *Neurosurgery* 2007; 60:46–58.
- 2 Snyderman CH, Kassam AB, Carrau R, Mintz A. Endoscopic reconstruction of cranial base defects following endonasal skull base surgery. *Skull Base* 2007; 17:73–78.
- 3 El-Sayed IH, Saleh H. *Neurosurgical complications in otolaryngology – head and neck surgery*. 2nd ed. Philadelphia, PA: Elsevier; 2008. pp. 110–132.
- 4 Kassam AB, Thomas A, Carrau RL, Snyderman CH, Vescan A, Prevedello D, et al. Endoscopic reconstruction of the cranial base using a pedicled nasoseptal flap. *Neurosurgery* 2008; 63:44–53.
- 5 Saeki N, Murai H, Hasegawa Y, Horiguchi K, Hanazawa T, Fukuda K. Endoscopic endonasal exrasellar tumors: case presentation and its future perspective (in Japanese). *No Shinkei Geka* 2009; 37:229–246.
- 6 Hadad G, Bassagasteguy L, Carrau RL, Mataza JC, Kassam A, Snyderman CH, Mintz A. A novel reconstructive technique after endoscopic expanded endonasal approaches: vascular pedicle nasoseptal flap. *Laryngoscope* 2006; 116:1882–1886.
- 7 Basu D, Haughey BH, Hartman JM. Determinants of success in endoscopic cerebrospinal fluid repair. *Otolaryngol Head Neck Surg* 2006; 135:769– 773.
- 8 Kassam A, Snyderman CH, Mintz A, Gardner P, Carrau RL. Expanded endonasal approach: the rostrocaudal axis. Part 1. Crista galli to sella turcica. *Neurosurg Focus* 2005; 19:E3.
- 9 Cavallo L M, Messina A, Espisto F, de Divitiis O, Dal Fabbo M. Skull base reconstruction in the external endoscopic trans-sphenoidal approach for suprasellar lesions. *J Neurosurg* 2007; 107:713–720.
- 10 Cantu G, Solero C L, Pizza N, Nardo L, Mattavelli F. Skull base reconstruction after anterior craniofacial resection. *J Craniomaxillofac Surg* 1999; 27:228–234.
- 11 Castevlnuovo PG, Delu G, Locatelli D, Padoan G, Bernardi FD, Bignami M. Endonasal endoscopic dura-plasty; our experience. *Skull Base* 2006; 16:19–24.
- 12 Ciric I, Regin A, Baumgarten C, Price D. Complications of trans-sphenoidal surgery: results of a national survey review of literature and personal experience. *Neurosurgery* 1997; 40:225–236.
- 13 Cook SW, Smith Z, Kelly DF. Endonasal trans-sphenoidal removal of tuberculum sellae meningiomas: technical note. *Neurosurgery* 2004; 155:239–244.
- 14 Leng LZ, Brown S, Anand VK, Schwartz TH. “Gasket-seal” watertight closure in minimal access endoscopic cranial base surgery. *Neurosurgery* 2008; 62 (Suppl 2): 342–343.
- 15 Kato TM, Sawamura Y, Abe H, Nagashima M. Transsphenoidal-transtuberculum selle approach for supradiaphragmatic tumors: technical note. *Acta Neurochir* 1998; 140:715–718, discussion 719.
- 16 Bien AG, Bowdino B, Moor G, Liebrock L. Utilization of preoperative cerebrospinal fluid drain in skull base surgery. *Skull Base* 2007; 17:133–139.
- 17 Harvey RJ, Nogueira JF, Schlosser RJ, Patel SJ, Stamm AC. Closure of large skull base defect after endoscopic transnasal craniotomy. *Neurosurgery* 2009; 111:371–379.
- 18 Carrau RL, Snyderman CH, Kassam AB. The management of cerebrospinal fluid leaks in patients at risk for high-pressure hydrocephalus. *Laryngoscope* 2005; 115:205–212.
- 19 Shah RN, Surowitz JB, Patel MR, Huang BY, Snyderman CH, Carrau RL, et al. Endoscopic pedicled nasoseptal flap reconstruction for pediatric skull base defects. *Laryngoscope* 2009; 119:1067–1075.