

# Endoscope-assisted surgery: a major adjunct in cholesteatoma surgery

Mohammed Badr-El-Dine, Yasser G. Shewel, Ahmad A. Ibrahim and Mohammed Khalifa

Department of Otolaryngology, Alexandria School of Medicine, University of Alexandria, Alexandria, Egypt

Correspondence to Yasser G. Shewel, MD, ENT Department, Alexandria School of Medicine, University of Alexandria, Rameh Station, Alexandria, Egypt  
Tel: +20 012 201 49937; e-mail: yshwel@yahoo.com

**Received** 1 November 2012  
**Accepted** 18 December 2012

**The Egyptian Journal of Otolaryngology**  
2013, 29:66–70

## Objective

The purpose of this study was to evaluate the role of middle-ear endoscopy in the effective control over cholesteatoma through visualizing hidden areas of the middle-ear cleft.

## Materials and methods

A total of 60 ears with retraction pocket cholesteatoma were operated upon. They were subdivided into 40 cases operated upon using the canal wall up technique and another 20 cases operated upon using transcanal atticotomy. Endoscopically guided ear surgery was incorporated complementary to the microscope as a principal part in the procedure.

## Results

The incidence of cholesteatoma in the facial recess that was visualized by the endoscope was 25% compared with 20% by the microscope, whereas the incidence of detection of cholesteatoma in the sinus tympani by the endoscope was 35% compared with 5% by the microscope. Cholesteatoma in the anterior epitympanic recess was detected by the endoscope in 10% of ears compared with 0% by the microscope. In this series, no morbidity or complication was encountered secondary to the use of endoscopes in the mastoid or the middle ear.

## Conclusion

Endoscope-assisted ear surgery has many benefits in cholesteatoma surgery as endoscopy helps explore hidden areas of the middle-ear cavity with a much lesser requirement for surgical exposure and the need to drill healthy bone; therefore, effective control over the disease can be achieved, thus establishing the concept of functional endoscopic ear surgery.

## Keywords:

cholesteatoma, endoscope-assisted ear surgery, sinus tympani

Egypt J Otolaryngol 29:66–70  
© 2013 The Egyptian Oto - Rhino - Laryngological Society  
1012-5574

## Introduction

Cholesteatoma is a cyst-like, expansile lesion of the temporal bone lined by a stratified squamous epithelium that contains desquamated keratin. It is classified into congenital and acquired cholesteatoma. The most common cholesteatoma seen clinically is the primary acquired or the retraction pocket type [1,2].

Surgical management of cholesteatoma remains controversial, with the main argument centering on the surgical handling of the posterior canal wall. The generally accepted advantages of canal wall up (CWU) surgery include preservation of the normal anatomy of the ear canal, thus eliminating cavity problems, and also a reduced healing time and better hearing results. However, limited exposure of the epitympanum and posterior mesotympanum often results in high residual rates; hence, a second-look operation is advised frequently. Canal wall down (CWD) mastoidectomy provides good surgical exposure for cholesteatoma removal and yields a significantly lower rate of residual cholesteatoma than

the CWU procedure, although it has a higher morbidity and a worse functional outcome [3,4].

Residual cholesteatoma is among the major causes of failure in the surgical treatment of cholesteatoma. It occurs as a consequence of the growth of a fragment of the matrix accidentally remaining in the middle ear at the time of cholesteatoma surgery. This happens even after meticulous removal of the matrix under the operating microscope, regardless of the surgical technique used [5].

The use of the surgical microscope brought advances into the field of otologic surgery because it expands the ability of surgeons to see the limited confines of the temporal bone. However, the particular complexity of middle-ear anatomy has prompted experienced otosurgeons to develop different techniques to explore areas that are difficult to visualize with the operating microscope. The straight-line view offered by the microscope results in certain blind spots during middle-ear surgery. These limitations can be overcome with the complementary

help of the endoscope, which allows 'looking around corners' [6,7].

The aim of the present study was to highlight the impact of using the endoscope in the management of retraction pocket cholesteatoma and to evaluate the role of middle-ear endoscopy in the effective control over the disease by visualizing hidden areas of the middle-ear cleft in comparison with the microscope.

## Materials and methods

This study was carried out on 60 ears with retraction pocket cholesteatoma between 2010 and 2012 in the Otolaryngology, Head and Neck Surgery Department of Alexandria University Hospital, Egypt.

All patients were subjected to history taking, physical examination, routine audiological assessment, and a multislice computed tomography scan of the petrous temporal bone.

In this study, these cases were operated upon using either CWU or transcanal atticotomy techniques. Endoscope-assisted surgery was incorporated complementary to the microscope in all cases. The choice of the approach depends on preoperative high-resolution computed tomography and endoscopic examination to evaluate mastoid involvement. Whenever the mastoid was involved, the disease was addressed with CWU tympanomastoidectomy. This approach gives us a wide access for removal of the cholesteatoma without damage to important structures, especially when dealing with cholesteatoma involving the anterior epitympanic recess.

The operation was performed using a Zeiss microscope (Carl Zeiss Group, Oberkochen, Germany) and standard microsurgical instruments under continuous suction irrigation. The optic equipments used consisted of 0°, 30°, and 45° rigid Hopkins rod telescopes with an outside diameter of 3 mm (Karl Storz GmbH & Co., Tuttlingen, Germany). A 3-CCD videocamera (Karl Storz GmbH & Co.) was used.

Endoscopy was used interchangeably with the microscopic work in looking for and removing remnant or residual epithelial matrix in hidden areas of the middle ear. These areas included the sinus tympani, the anterior epitympanic recess, and the facial recess.

Intraoperative parameters evaluated in the present study were the presence of scutum erosion, mastoid pathology, ossicular erosion, the incidence of detection of cholesteatoma by the operating microscope and by the endoscope, and assessment of the overall visibility of hidden spaces with the endoscope and the microscope.

## Results

The study included 60 patients with retraction pocket cholesteatoma operated upon between 2010 and 2012 in

which the endoscope was incorporated actively throughout the process of pathology eradication.

The age of the patients studied ranged from 18 to 50 years, with a mean age of 35 years. There were 26 (43.3%) male and 34 (56.7%) female patients, showing no significant difference.

CWU mastoidectomy was the standard technique and was used in 40 cases, whereas transcanal atticotomy was performed in 20 patients.

The incidence of scutum erosion was 40%, whereas the incidence of mastoid involvement by cholesteatoma was 65%. The incidence of ossicular erosion was 6.67%, 56.7%, and 20% for malleus, incus, and stapes, respectively.

### The overall visibility of hidden areas of the middle ear by the endoscope versus the microscope

One important parameter that was assessed in this study was the overall visibility of hidden areas of the middle ear (whether they were involved by cholesteatoma or not) by the endoscope versus a microscope. The facial recess was visualized by the endoscope in 100% of the ears compared with 90% by the microscope. This difference was statistically significant. The incidence of endoscopic visibility of the sinus tympani was 100% compared with 20% by the microscope, with a statistically significant difference ( $P > 0.001$ ). The anterior epitympanic recess in this study was visible by the endoscope in 66% of the cases (40 out of 60 patients), whereas it was not visible by the operating microscope because excessive drilling and removal of the scutum and cog is needed to visualize it. This difference was statistically significant ( $P > 0.001$ ) (Table 1, Figs 1 and 2).

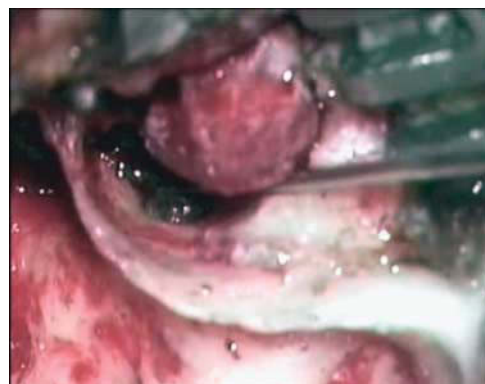**Table 1** Visibility of the hidden areas of the middle ear

	N (%)		Test of significance (FEp)
	Endoscope	Microscope	
Facial recess	60 (100)	54 (90)	0.027*
Sinus tympani	60 (100)	12 (20)	<0.001*
Anterior epitympanic recess	40 (66)	0 (0)	<0.00*

FEp,  $P$  value for Fisher's exact test.

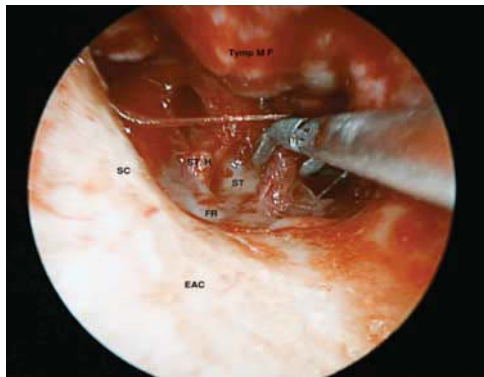
\*Statistically significant at  $P \leq 0.05$ .

**Figure 1**



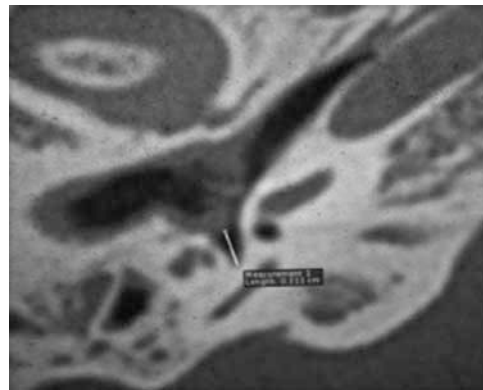
Microscopic view showing the very limited visualization of the sinus tympani. The attic could be visualized through the posterior atticotomy.

Figure 2



Right ear view using a 30° endoscope. Left-curved fine-cupped forceps removing granulation tissue from over the sinus tympani (ST). Stapes head (ST H) attached by the stapedius tendon; facial recess (FR); scutum (SC); external auditory canal (EAC); tympanomeatal flap (Tymp MF).

Figure 3



Multislice computed tomography scan showing the morphology of the sinus tympani and the retraction pocket cholesteatoma abutting into the orifice of the sinus tympani recess.

**Table 2 Comparison of the detection of cholesteatoma by the endoscope versus the microscope**

	N (%)		Test of significance
	Endoscope	Microscope	
Facial recess	15 (25)	12 (20)	$P=0.512$
Sinus tympani	21 (35)	3 (5)	$FEp < 0.001^*$
Anterior epitympanic recess	6 (10)	0 (0)	$FEp = 0.027^*$

FEp,  $P$  value for Fisher's exact test;  $P$ ,  $P$  value for  $\chi^2$  test.

\*Statistically significant at  $P \leq 0.05$ .

#### Incidence of detection of cholesteatoma in hidden areas of the middle ear by the endoscope versus the microscope

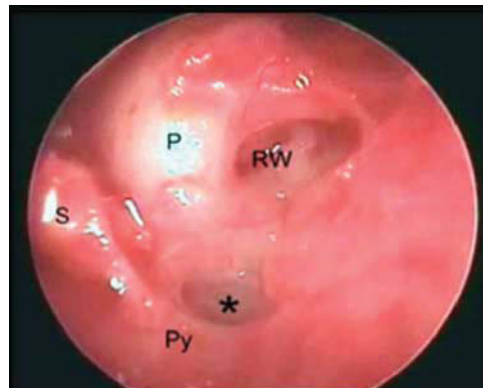
The incidence of cholesteatoma in the facial recess that was visualized by the endoscope was 25% compared with 20% by the microscope, whereas the incidence of cholesteatoma in the sinus tympani visualized by the endoscope was 35% compared with 5% by the microscope, with a statistically significance difference ( $P > 0.001$ ). Cholesteatoma in the anterior epitympanic recess was detected by the endoscope in 10% of ears compared with 0% by the microscope with a statistically significant difference as the operating microscope could not visualize cholesteatoma in the anterior epitympanic recess unless the sputum and cog were drilled out ( $P > 0.027$ ) (Table 2, Figs 3 and 4).

#### Postoperative follow-up

All patients were discharged 1 day after surgery without any complications. Patients were instructed about the importance of thorough postoperative follow-up. Follow-up was carried out by office-based clinical examination including otoscopic and endoscopic follow-up. The duration of follow-up ranged between 6 and 30 months. The mean duration of follow-up for the 60 patients was  $16.6 \pm 6.1$  months. All patients had a negative clinical follow-up with regard to recurrence of the disease.

In our series, there was no morbidity or complications secondary to the use of the endoscope in the mastoid or the middle ear.

Figure 4



Endoscopic view showing the retrotympanum after extirpation of the cholesteatoma under endoscopic control. RW, round window; P, promontory; S, stapes head; Py, pyramidal eminence. \*Sinus tympani clean from any pathology.

#### Discussion

Poor access is one of the major reasons for residual disease because with the operating microscope, the surgeon can visualize only structures directly ahead and is unable to see around objects. This straight-line view offered by the microscope results in certain blind pockets during middle-ear surgery [3]. These limitations could be overcome with the introduction of the endoscope, which allows 'looking around corners' [8].

In our study, we are emphasizing the value of ear endoscopy, which is incorporated complementary to the microscope in the management of retraction pocket cholesteatoma.

Endoscope-assisted surgery has become crucially complementary to the operating microscope for visualizing hidden areas of the middle-ear cleft, which are the anatomic regions that could be considered blind pockets when using only the operative microscope, thereby

allowing the discovery of any residual disease in areas such as the sinus tympani, the facial recess, and the anterior epitympanic recess.

In this study, the sinus tympani was the most common site that was involved by cholesteatoma in about 35% (21 out of 60 patients), whereas the facial recess was considered to be the second most common site and represents 25% (15 out of 60 patients); these results are similar to those reported by Magnan *et al.* [8] and Pratt [9].

Another important anatomical area that remains difficult to explore using the operative microscope is the anterior epitympanic space (AES). In our study, AES is a less commonly affected hidden space of the middle-ear cleft at about 10% (six out of 60 patients with residual disease) and this is different from the results of Migirov *et al.* [10], who found a relatively higher rate of cholesteatoma involvement in the AES in their study.

A comparison of the incidence of detection of cholesteatoma by the endoscope with that by the microscope proved a very important parameter that the use of the endoscope had a significant value in visualizing cholesteatoma in the sinus tympani and the anterior epitympanic recess in comparison with using only the microscope.

In this study, we found that visibility of the sinus tympani and the facial recess were 100% with the help of the endoscope, whereas they were less visible areas when the microscope was used alone (20% for the sinus tympani and 90% for the facial recess). The anterior epitympanic recess was visible in 65% of the cases while using the endoscope in contrast to using the microscope alone in which the anterior epitympanic recess could not be visualized unless drilling of the scutum was performed. This is similar to what was stated by Ayache *et al.* [11] in their study.

We found that difficult cases that previously required CWD are now operated using CWU with the help of the endoscope, which visualizes difficult-to-reach hidden spaces of the middle-ear cavity without drilling healthy bone as in CWD, therefore achieving more functional surgery. On the basis of the previous discussion, the use of the endoscope could be considered as an additional criterion that may affect decision making in cholesteatoma surgery, which is similar to that stated by El-Meselaty *et al.* [12] in their study.

In the present study, the 30° endoscope was most frequently used in all cases and gave the best overall exposure of the middle-ear recesses. Similarly, Bottrill and Poe [13], Yung [14], McKennan [15], Presutti *et al.* [5], and Youssef and Poe [16] preferred the 30° endoscope because of its better forward view capabilities that facilitate introduction into the wound.

There was neither morbidity nor complications secondary to the use of endoscopes in the current study. However, the risk of damage to the ossicular chain should not be underestimated. Thomassin *et al.* [17] reported two cases of total sensorineural hearing loss as a result of trauma to the intact stapes.

Endoscopic ear surgery has some limitations: first, the endoscopic approach depends on the experience and skills of the surgeon. In inexperienced hands, the endoscopic approach can be associated with complications caused by direct trauma from the tip of the endoscope to the facial nerve, the ossicular chain, and low-lying tegmen. Second, otosurgeons are accustomed to using both hands at surgery, whereas in the endoscopic ear surgery, one hand is occupied with the endoscope and the other performs the manipulations. Hence, assistance is often required with the operating microscope when there is a need for two-hand manipulations in the dissection of the cholesteatoma from the dehiscent facial nerve, ossicles, and stapes footplate, and in some cases, ossicular reconstruction is very difficult to perform with one hand. Third, the endoscopic surgeon watches the monitor in contrast to looking directly into the operated ear through the oculars of the microscope, and this can result in a loss of depth perception that is later compensated with experience. Fourth, fogging and smearing of the tip of the endoscope and the need for frequent cleaning and application of defogging agents affect the operative time. Finally, the cost of equipment involved is a disadvantage [18,19].

Although endoscopy cannot be viewed as a replacement for conventional mastoid surgery, it offers the surgeon a less invasive option. McKennan [15] and Youssef and Poe [16] restricted the use of the endoscope to only the second-look approach, introducing the optic through the mastoid cavity and exploring hidden recesses, whereas many authors, such as Badr-El-Dine [20], Thomassin *et al.* [17], Magnan *et al.* [8], and Pratt [9] preferred associated endoscopy to traditional CWU mastoidectomy. Tarabichi [21] preferred an exclusive endoscopic approach for limited attic cholesteatoma.

We conclude that introducing the endoscope into the surgical field is a step forward, especially in otosurgery, as the endoscope provides a wide field of vision with minimal exposure, exploring hidden areas of the middle-ear cavity with much lesser requirement for surgical exposure and the need to drill healthy bone, which is required by conventional techniques; therefore, effective control over the disease can be achieved, thus establishing the concept of 'functional endoscopic ear surgery.'

---

## Acknowledgements

### Conflicts of interest

There are no conflicts of interest.

---

## References

- 1 Sallatery WH. Pathology and clinical course of inflammatory diseases of the middle ear. In: Glasscock ME, Gulya AJ, editors. *Glasscock-Shambaugh surgery of the ear*. Hamilton, Ontario: BC Decker Inc.; 2003. pp. 429–432.
- 2 Young N, Chole R. Retraction pocket cholesteatoma. *Curr Opin Otolaryngol Head Neck Surg* 2002; 10:355–359.
- 3 Bauer M. Ossiculoplasty: autogenous bone grafts, 34 years experience. *Clin Otolaryngol Allied Sci* 2000; 25:257–263.
- 4 Tarabichi M. Endoscopic management of limited attic cholesteatoma. *Laryngoscope* 2004; 114:1157–1162.

- 5 Presutti L, Marchioni D, Mattioli F, Villari D, Alicandri-Ciufelli M. Endoscopic management of acquired cholesteatoma: our experience. *J Otolaryngol Head Neck Surg.* 37; 2008. pp. 481–487.
- 6 Yadav SPS, Aggarwal N, Julaha M, Goel A. Endoscope-assisted myringoplasty. *Singapore Med J* 2009; 50:510–512.
- 7 Tarabichi M. Endoscopic management of cholesteatoma: long-term results. *Otolaryngol Head Neck Surg* 2000; 122:874–881.
- 8 Magnan J, Chays A, Lepetre C, Pencroffi E, Locatelli P. Surgical perspectives of endoscopy of the cerebellopontine angle. *Am J Otol* 1994; 15:366–370.
- 9 Pratt LL. Complications associated with the surgical treatment of cholesteatoma. *Laryngoscope* 1983; 93:289–291.
- 10 Migirov L, Shapira Y, Horowitz Z, Wolf M. Exclusive endoscopic ear surgery for acquired cholesteatoma: preliminary results. *Otol Neurotol* 2011; 32:433–436.
- 11 Ayache S, Tramier B, Strunski V. Otoendoscopy in cholesteatoma surgery of the middle ear: what benefits can be expected? *Otol Neurotol* 2008; 29:1085–1090.
- 12 El-Meselaty K, Badr-El-Dine M, Mandour M, Mourad M, Darweesh R. Endoscope affects decision making in cholesteatoma surgery. *Otolaryngol Head Neck Surg* 2003; 129:490–496.
- 13 Bottrill ID, Poe DS. Endoscope-assisted ear surgery. *Am J Otol* 1995; 16:158–163.
- 14 Yung MW. The use of middle ear endoscopy: has residual cholesteatoma been eliminated? *J Laryngol Otol* 2001; 115:958–961.
- 15 McKennan KX. Endoscopic 'second look' mastoidoscopy to rule out residual epitympanic/mastoid cholesteatoma. *Laryngoscope* 1993; 103:810–814.
- 16 Youssef TF, Poe DS. Endoscope-assisted second-stage tympanomastoidectomy. *Laryngoscope* 1997; 107:1341–1344.
- 17 Thomassin JM, Korchia D, Doris JMD. Endoscopic-guided otosurgery in the prevention of residual cholesteatomas. *Laryngoscope* 1993; 103:939–943.
- 18 Tarabichi M. Endoscopic middle ear surgery. *Ann Otol Rhinol Laryngol* 1999; 108:39–46.
- 19 Tarabichi M. Endoscopic management of acquired cholesteatoma. *Am J Otol* 1997; 18:544–549.
- 20 Badr-El-Dine M. Value of ear endoscopy in cholesteatoma surgery. *Otol Neurotol* 2002; 23:631–635.
- 21 Tarabichi M. Transcanal endoscopic management of cholesteatoma. *Otol Neurotol* 2010; 31:580–588.