

# Endoscopic examination after adenoidectomy: is it necessary?

Nader Naguib<sup>a,b</sup>

<sup>a</sup>Department of Otolaryngology, Faculty of Medicine, BeniSuef University, BeniSuef, Egypt and  
<sup>b</sup>Otolaryngology Department, Dr Soliman Fakeeh Hospital (DSFH), Jeddah, Kingdom Saudi Arabia (KSA)

Correspondence to Nader Naguib, MD, Department of Otolaryngology, Faculty of Medicine, BeniSuef University, BeniSuef, Egypt  
Tel: +96 65 425 180 40/+20 10 056 580 40;  
fax: +08-0822336691;  
e-mail: naderelmohandiss@yahoo.com

**Received** 13 November 2012  
**Accepted** 24 December 2012

**The Egyptian Journal of Otolaryngology**  
2013, 29:76–79

Adenoidectomy is a safe and straightforward surgical procedure with clear indications. Traditionally, adenoidectomy is performed using a curette. The main disadvantage of this method is that it is a relatively blind technique. The aim of this study was to assess the efficacy of endoscopic nasopharyngeal examination at the end of curettage adenoidectomy in terms of both subjective and objective relief of nasal symptoms. A total of 110 patients were included in this study and divided randomly into two equal groups during the operation. Patients in group A underwent conventional curettage adenoidectomy and those in group B were further subjected to nasopharyngeal endoscopic examination at the end of the operation. After 18 months, 21.1% of patients in group A and 14% in group B complained of nasal obstruction. Moreover, on endoscopy, 13.4% of patients in group A and 8% in group B showed remaining adenoid tissue. Hence, nasopharyngeal endoscopic examination at the end of conventional curettage adenoidectomy is an easy method to detect and remove remnant adenoid tissue with minimal extra cost and operative time.

## Keywords:

adenoids, endoscopic examination, nasopharyngeal examination

Egypt J Otolaryngol 29:76–79  
© 2013 The Egyptian Oto - Rhino - Laryngological Society  
1012-5574

## Introduction

Adenoidectomy is among the most common operations performed in children worldwide. In 1999, in the UK, a total of 60 000 patients underwent tonsillectomy with or without adenoidectomy and another 9000 underwent adenoidectomy alone [1].

Adenoidectomy is a safe and straightforward surgical procedure with clear indications. It is commonly performed to treat snoring, nasal obstruction, obstructive sleep apnea, recurrent otitis media, otitis media with effusion, sinusitis, and adenotonsillar hypertrophy [2].

Traditionally, adenoidectomy is performed using a curette. The main disadvantages of this method are that it is a relatively blind technique that may lacerate the choanae and torus tubarius, the nasopharyngeal mucosa, or may leave behind obstructing tissue, particularly at the eustachian tube orifices, high in the nasopharynx, and at intranasal protrusions [3].

Dissatisfaction with the conventional technique in adequately and safely removing the adenoid tissue has led to the development of alternative methods. Since 1992, a number of authors have described visualization of the operating field during surgery using a laryngeal mirror [4] or a transoral [5] or transnasal [6] endoscope. These authors used curettes, suction coagulators [7], forceps [8], and transnasal [9] or transoral [3] microdebriders as surgical tools for removal of adenoids.

The aim of this study was to assess the efficacy of endoscopic nasopharyngeal examination at the end of curettage adenoidectomy in terms of both subjective and objective relief from nasal symptoms.

## Patients and methods

This prospective study was carried out on 110 pediatric patients who presented to a private hospital in Jeddah, KSA, with adenoid hypertrophy with or without tonsillar hypertrophy from September 2010 to June 2011.

The patients were aged between 4 and 11 years; 63 were boys (67.2%) and 47 were girls (42.7%). These patients had symptoms of nasal obstruction, mouth breathing, snoring, deafness, and recurrent sinusitis. Adenoid hypertrophy was the only cause for nasal obstruction in all patients. Patients with nasal septal deviation, a submucous cleft palate, craniofacial abnormalities, and bleeding disorders were excluded from the study. Patients who missed follow-up were also excluded.

Every patient in this study was subjected to the following:

- (1) Preoperative assessment
  - (a) Obtaining full history of otolaryngological symptoms and past history of operations and general diseases.
  - (b) Complete ear nose throat examination with endoscopic nasal examination in suspected patients.
  - (c) Lateral view radiographs of the nasopharynx for patients with adenoid hypertrophy.
- (2) Operative procedure
  - (a) The patients were divided randomly into two equal groups during the operation as follows:
    - (i) Group A: underwent conventional curettage adenoidectomy. The patient was made to lie in a supine position under general anesthesia

and intubated with a centrally placed Rae's tube of appropriate size. Thereafter, a Boyle-Davis mouth gag with an appropriately sized tongue depressor was placed. The enlarged adenoids and their connection with the surrounding structures were palpated. An appropriately sized St Clair Thompson curette was selected to remove the adenoid. Curettage of the adenoid was gently performed until all the adenoid tissue had been removed. Thereafter, the raw area was packed with gauze to secure hemostasis.

- (ii) Group B: patients of this group were subjected to the same operative steps as those in group A, except that after removal of the pack, nasopharyngeal examination was carried out using a rigid nasal endoscope (2.7 mm in diameter, 0 and 30°). If the nasal cavity was congested, a ribbon gauze soaked in 0.05% oxymetazoline solution was inserted for 5 min to shrink the nasal mucosa. The remaining adenoid tissues were localized and removed through both sides of the nose using the straight and angled nasal forceps under endoscopic guidance. All patients were operated upon by the same surgeon.

### (3) Postoperative follow-up

- (a) Patients of both the groups were advised to follow-up at the clinic 1 week, 6, 12, and 18 months postoperatively. During the follow-up visits, all patients were subjected to the following:

- (i) History taking for symptoms of nasal obstruction, snoring, and recurrent ear infection.
- (ii) Ear nose throat examination including nasopharyngoscopic examination, for patients with nasal obstruction, after application of a mixture of 4% lidocaine and 0.05% oxymetazoline hydrochloride for decongestion and anesthesia of the nasal cavity. On the basis of the method defined by Cassano *et al.* [10], the sizes of hypertrophied adenoid tissue were recorded endoscopically as (a) first grade: obstruction of the upper 25% or less of the choana; (b) second grade: obstruction of less than 50% of the choana; (c) third grade: obstruction of less than 75% of the choana; and (d) fourth grade: almost complete obstruction of the choana by the hypertrophied adenoid tissue.

Both the groups were compared on the basis of subjective and objective evaluations. Patients with recurrence of nasal symptoms and third or fourth degree choanal obstruction according to the scale developed by Cassano *et al.* [10] were diagnosed with recurrent obstructive adenoid hypertrophy.

## Results

A total of 110 patients were included in this study and were divided randomly into two equal groups during the operation. Patients in group A underwent conventional curettage adenoidectomy and those in group B were further subjected to nasopharyngeal endoscopic examination at the end of the operation. Nasopharyngeal examination revealed remaining adenoid tissues in the superomedial choana in 38 patients (69%), in the eustachian tube opening in 27 patients (49%), and in the nasopharyngeal roof in 33 patients (60%). Remnant adenoid tissues in the left-sided tubal and superior choanal regions are shown in Fig. 1. Figure 2 shows the right side after removal of the remaining adenoid tissue.

No postoperative complications were recorded in both the groups. Three patients in group A and five in group B missed follow-up and were excluded from the study. Patients and families of both the groups were asked about symptoms of nasal obstruction during the follow-up period and the results are summarized in the following schedule:

	After 6 months [n (%)]	After 12 months [n (%)]	After 18 months [n (%)]	Total [n (%)]
Nasal obstruction				
Group A (52)	6 (11.5)	3 (5.7)	2 (3.8)	11 (21.1)
Group B (50)	3 (6)	2 (4)	2 (4)	7 (14)
Total (102)	9 (8.8)	5 (4.9)	4 (3.9)	18 (17.6)

All patients complaining of nasal obstruction postoperatively were examined endoscopically for the presence of recurrent hypertrophied adenoid tissue, and those with third or fourth degree choanal obstruction in both the groups are shown in the next schedule:

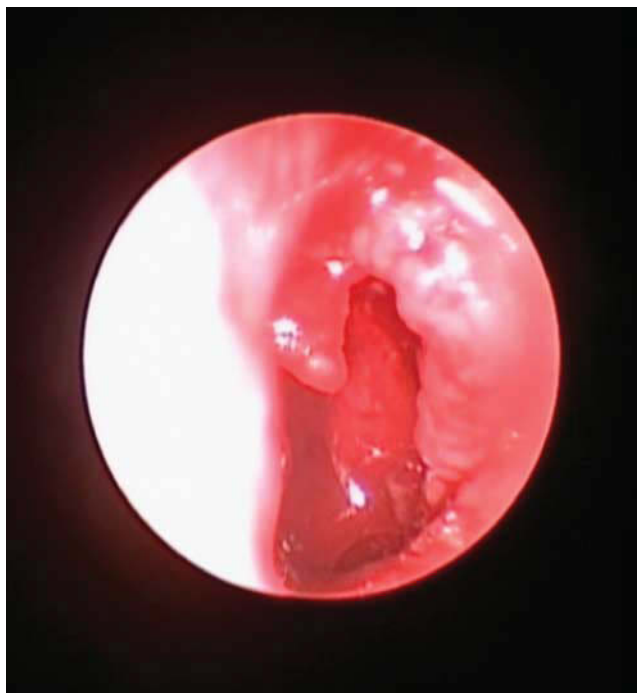
	After 6 months [n (%)]	After 12 months [n (%)]	After 18 months [n (%)]	Total [n (%)]
Choanal obstruction				
Group A (52)	4 (7.6)	2 (3.8)	1 (1.9)	7 (13.4)
Group B (50)	1 (2)	1 (2)	2 (4)	4 (8)
Total (102)	5 (4.9)	3 (2.9)	3 (2.9)	11 (10.7)

## Discussion

Adenoidal hypertrophy is a common condition in children and can cause symptoms such as mouth breathing, nasal discharge, snoring, sleep apnea, and hyponasal speech. It also contributes to the pathogenesis of rhinosinusitis, recurrent otitis media, and otitis media with effusion [11]. There are various techniques for performing an adenoidectomy. Conventional adenoidectomy is performed using an adenoid curette after digital palpation of the adenoid. Pearl and Manoukian removed the choanal adenoids under indirect visualization using a laryngeal mirror. Because of misting and limited view of the operative site, the complications that may occur include incomplete removal from the roof of the nasopharynx or torus tubarius and possible eustachian tube injury [12].

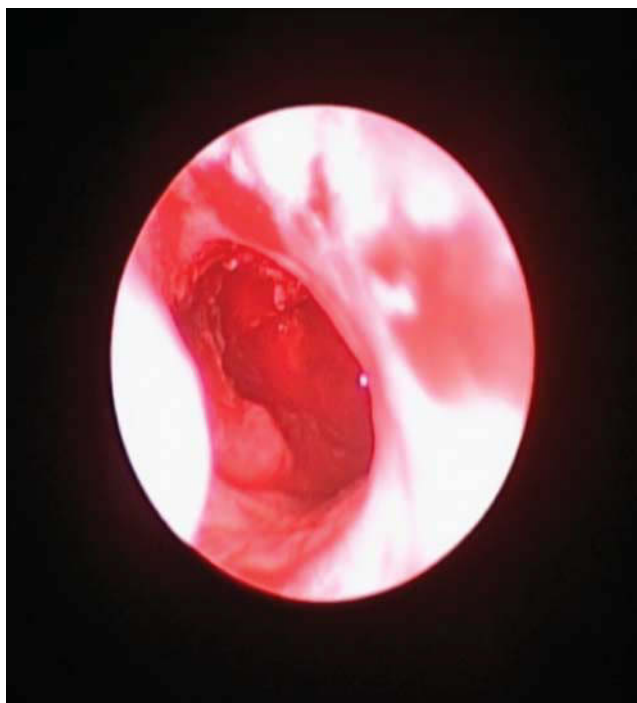In this study, nasal endoscopic examination at the end of conventional adenoidectomy was used to assess the

Figure 1



Left-sided adenoid tissue remaining.

Figure 2



The right side after removal of the remaining adenoid tissue.

remaining adenoid tissue. Subjective and objective evaluations after removing the remaining tissue were carried out, and comparisons were made with conventional adenoidectomy patients to study the efficacy of this technique.

Immediate postoperative examination revealed remaining adenoid tissues in the superomedial choanae in 69% of patients, in the eustachian tube opening in 27 (49%) patients, and in the nasopharyngeal roof in 33 (60%) patients. Regmi *et al.* [13] endoscopically evaluated the nasopharynx before and after adenoid curettage in 41 adenoidectomy patients and indicated that conventional curettage, used alone, failed to remove adenoid tissue completely from the superomedial choanae and anterior vault in all patients; incomplete removal was observed in other parts of the choanae in 67.2% of patients, in the eustachian tube opening in 63%, in the nasopharyngeal roof in 61.78%, and in the fossa of Rosenmuller in 61%. Abdel-Aziz [14] reported that residual adenoid tissues were detected and cauterized in 36 of 175 patients (20.5%) who underwent nasopharyngeal examination after conventional adenoidectomy.

Postoperative subjective assessment in this study showed a significant increase in recurrent symptoms of nasal obstruction and snoring in patients of group A, especially during the first 6 months. Wan *et al.* [15] studied nasal endoscope-guided curettage adenoidectomy in 13 patients, and all showed postoperative improvement in snoring and increased quality of sleep as reported by the parents and the patients. Another similar study, but with a larger number of patients, was carried out by El-Badrawy and Abdel-Aziz [11], in which only one patient of 300 developed recurrent obstructive nasal symptoms due to adenoid regrowth, and investigations revealed that the patient had a nasal allergy, which might be the cause of recurrence.

In this study, the recurrence of symptoms and adenoid tissue hypertrophy in both the groups postoperatively was parallel to each other, with an increase in the symptoms of snoring and nasal obstruction. This increase is because of the development of other causes of snoring such as tonsillar hypertrophy and/or allergic rhinitis. Recurrence of adenoid tissue was detected endoscopically in the sixth month postoperatively in four patients (7.6%) of group A and one (2%) of group B. After 18 months, the total number of recurrent cases reached seven (13.4%) in group A and four (8%) in group B, with a significant difference between both the groups. Jong and Gendeh [12] studied the transoral endoscope-guided adenoidectomy in comparison with conventional adenoidectomy with five patients in each group and reported that 3 months postoperatively all patients who had undergone transoral endoscopic adenoidectomy were asymptomatic; nasendoscopy revealed normal mucosa in the nasopharynx and a patent Eustachian tube. However, two patients who had undergone conventional adenoidectomy had recurrent symptoms, indicating recurrent adenoid hypertrophy. Nasendoscopy revealed residual adenoids in the superior part of the nasopharynx. Abdel-Aziz [14] reported in the previously mentioned study that, after a 2 year follow-up, recurrent adenoid tissue was seen in 6.6% of patients who had undergone conventional adenoidectomy and in 1.18% of the endoscopically examined patients at the end of adenoidectomy, which is comparable to the findings of this study.

---

## Conclusion

Nasopharyngeal endoscopic examination at the end of conventional curettage adenoidectomy is an easy method to detect and remove remnant adenoid tissue with minimal extra cost and operative time. It also results in better outcomes in the patients because of early detection of the remaining adenoid tissue. Therefore, we advocate this technique over conventional adenoidectomy owing to its added advantages.

---

## Acknowledgements

### Conflicts of interest

There are no conflicts of interest.

---

## References

- 1 Georgalas C, Thomas K, Owens C, Abramovich S, Lack G. Medical treatment for rhinosinusitis associated with adenoidal hypertrophy in children: an evaluation of clinical response and changes on magnetic resonance imaging. *Ann Otol Rhinol Laryngol* 2005; 114:638–644.
- 2 Cowan DL, Hibbert J. Tonsils and adenoids (Chapter 18). In: Kerr AG, Gleeson M, editors. *Scott Brown's otolaryngology, pediatric otolaryngology*. Vol. 6 6th ed. Oxford: Butterworth Heinemann; 1997. pp. 1–16.
- 3 Koltai PJ, Kalathia AS, Stanislaw P, Heras HA. Power-assisted adenoidectomy. *Arch Otolaryngol Head Neck Surg* 1997; 123:685–688.
- 4 Owens D, Jaramillo M, Saunders M. Suction diathermy adenoid ablation. *J Laryngol Otol* 2005; 119:34–35.
- 5 Costantini F, Salamanca F, Amaina T, Zibordi F. Videoendoscopic adenoidectomy with microdebrider. *Acta Otorhinolaryngol Ital* 2008; 28:26–29.
- 6 Shin JJ, Hartnick CJ. Pediatric endoscopic transnasal adenoid ablation. *Ann Otol Rhinol Laryngol* 2003; 112:511–514.
- 7 Durr DG. Endoscopic electro-surgical adenoidectomy: technique and outcomes. *J Otolaryngol* 2004; 33:82–87.
- 8 Cannon CR, Replogle WH, Schenk MP. Endoscopic-assisted adenoidectomy. *Otolaryngol Head Neck Surg* 1999; 121:740–744.
- 9 Yanagisawa E, Weaver EM. Endoscopic adenoidectomy with the microdebrider. *Ear Nose Throat J* 1997; 76:72–74.
- 10 Cassano P, Gelardi M, Cassano M, Fiorella ML, Fiorella R. Adenoid tissue rhinopharyngeal obstruction grading based on fiberendoscopic findings: a novel approach to therapeutic management. *Int J Pediatr Otorhinolaryngol* 2003; 67:1303–1309.
- 11 El-Badrawy A, Abdel-Aziz M. Transoral Endoscopic Adenoidectomy. *Int J Otolaryngol* 2009: 2009:949315 (article ID).
- 12 Jong YH, Gendeh BS. Transoral endoscopic adenoidectomy: initial experience. *Med J Malaysia* 2008; 63:81–83.
- 13 Regmi D, Mathur NN, Bhattarai M. Rigid endoscopic evaluation of conventional curettage adenoidectomy. *J Laryngol Otol* 2011; 125:53–58.
- 14 Abdel-Aziz M. Endoscopic nasopharyngeal exploration at the end of conventional curettage adenoidectomy. *Eur Arch Otorhinolaryngol* 2012; 269:1037–1040.
- 15 Wan YM, Wong KC, Ma KH. Endoscopic-guided adenoidectomy using a classic adenoid curette: a simple way to improve adenoidectomy. *Hong Kong Med J* 2005; 11:42–44.