

Practical approach to the management of dizzy patients

Ossama I. Mansour

Department of Otolaryngology, Ain Shams University, Cairo, Egypt

Correspondence to Ossama I. Mansour, MD, Department of Otolaryngology, Ain Shams University, 2 Fayoum St. Heliopolis, 11341 Cairo, Egypt
Tel/fax: +202 2418 9158;
e-mail: mansouroi@yahoo.com

Received 24 September 2012

Accepted 6 October 2012

The Egyptian Journal of Otolaryngology
2013, 29:49–55

Introduction

Dizziness is a common symptom that may be caused by diverse pathologies. It requires a multidisciplinary approach and comprehensive workup to diagnose and treat the cause. A practical and simplified approach is presented.

Objectives

After reading this article you should be able to: (1) Remember the basics of balance control; (2) Assess a dizzy patient in the office; (3) Be familiar with available vestibular tests and the clinical yield of each; (4) Plan a practical workup algorithm; (5) Differentiate between the common causes of dizziness; (6) Know the current management strategies; (7) Understand the concepts of vestibular rehab.

Keywords:

dizziness, dizziness/diagnosis, dizziness/therapy, vertigo, vertigo/diagnosis, vertigo/therapy

Egypt J Otolaryngol 29:49–55
© 2013 The Egyptian Oto - Rhino - Laryngological Society
1012-5574

Objectives: After reading this article you should be able to:

- (1) Remember the basics of balance control;
- (2) Assess a dizzy patient in the office;
- (3) Be familiar with available vestibular tests and the clinical yield of each;
- (4) Plan a practical workup algorithm;
- (5) Differentiate between the common causes of dizziness;
- (6) Know the current management strategies;
- (7) Understand the concepts of vestibular rehab.

dizziness is followed, aiming to answer the following questions:

- (1) Is it a genuine organic deficit? (to exclude malingerers)
- (2) What is the organ affected? (a single or multiorgan affection)
- (3) What is the possible etiology? (to initiate specific treatments)
- (4) What is the functional disability? (to plan a rehabilitation program for the patient)

Introduction

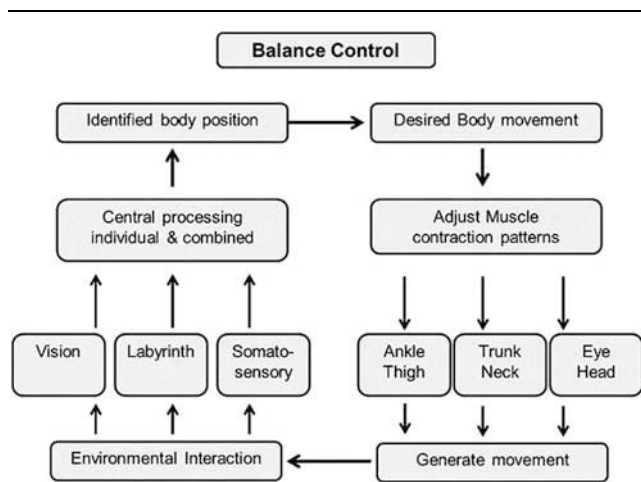
Dizziness is a common complaint, accounting for about 10% of visits to primary care physicians, which may increase to 50% in elderly patients. Most causes are usually benign and self-limiting, but loss of balance may cause serious injuries. Worry of falls usually affects the patient's everyday activities, with a negative impact on his/her quality of life. Patients with balance problems seek medical advice from multiple specialties and usually they will be referred to you, the otolaryngologist, as the balance expert. For the purpose of this article, we will focus on vestibular lesions.

In your busy clinic, a patient walks in complaining of dizziness. Now you are upset thinking of the long time you have to spend with him and the usual confusing history. This will not happen, if a systematic approach to

Functional anatomy

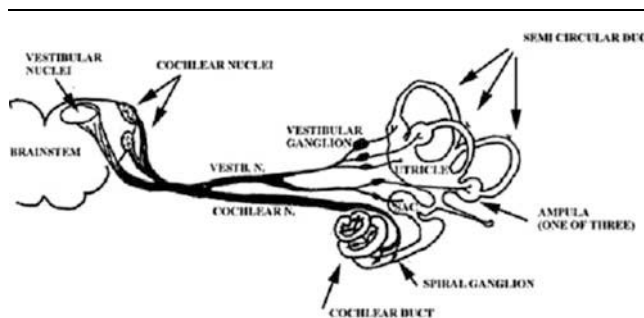
Our sense of balance is developed and maintained by the interaction of sensory inputs from the vestibular labyrinth, vision, and proprioception. The vestibular labyrinth comprises the utricle and the saccule, which sense linear movements and gravity, and three perpendicular semi-circular canals, which are bilaterally functionally paired, responding to angular movements. Processing of matched contributions occurs in vestibular nuclei with modulation in the cerebellum and higher centers (Figs 1 and 2). Maintenance of balance in stance and dynamically in moving requires effective reflexes, mainly the vestibulo-ocular reflex (VOR), to stabilize the visual field stability and vestibulospinal reflexes (VSRs), medial VSR to maintain head stability during body movement, and lateral VSR to maintain our center of gravity and limb position during body movement. Any mismatch in sensory input or processing will cause a sense of imbalance or

Figure 1



Organs involved in balance control.

Figure 2



Vestibular system.

dizziness. This could be because of various reasons such as inflammatory, metabolic, vascular, neoplastic, drugs, or specific diseases.

Pathophysiology

Acute disease, for example inflammation, affecting the vestibular system result in a 'vestibular crisis', manifested by a sudden sense of rotation that increases with motion, because it increases the mismatching responses between normal and abnormal sides, usually associated with nausea or vomiting and sometimes palpitations and sweating. Nystagmus is involuntary rhythmic repetitive eye movements, which occur to correct the drift in the visual field. Nystagmus may be conjugate, jerky (slow and fast phases), unidirectional horizontal, or Torsional, which increase by removal of visual fixation and by looking toward the direction of the fast phase. These criteria are consistent with peripheral vestibular lesions. Worth mentioning and a perplexing point is that lesions of vestibular sense organs, nerve or nuclei may give similar findings on testing; demonstrating that they are

physiologically considered as one entity. However, in the clinical context, lesions affecting vestibular nuclei are central lesions that occur in the brainstem.

Recovery commences by cerebellar clamping to inhibit vestibular inputs and results in amelioration of symptoms with neuronal repair or regeneration that continues to induce an asymptomatic state. Central compensation depends on CNS plasticity; thus, comorbidities such as diabetes or aging may delay recovery. Occasional decompensations may follow physical or mental stress that causes recurrent symptomatology, although milder, and confusing the clinical scenario.

Disease progress and compensation is an ongoing process. Natural history of some disease may show periods of remissions and exacerbations. You interview and examine the patient during a window of time during this interactive process. Close follow-up may reveal a diagnosis that was not evident before.

Understanding of the pathophysiology has changed the concept of treatment of vertiginous patients. The aim of treatment is to ameliorate the symptoms using vestibular suppressants in the acute stage and encouraging early ambulation and implementing a simple vestibular rehabilitation program to allow earlier compensation. Then a comprehensive work up should follow to diagnose the underlying pathology to initiate directed treatment. Prolonged use of vestibular suppressants has to be minimized in clinical practice as it disturbs the compensation. Persistent unsteadiness may require vestibular rehabilitation exercises to supplement compensation in some patients.

Diagnosis

The patient may present during the acute stage with evident signs as nystagmus or may present with chronic or recurrent symptoms of dizziness with no evident signs that require provocation of symptoms or targeted testing of balance.

When dealing with a patient with acute vertigo, the main aim is to exclude a life-threatening disease such as evolving cerebrovascular stroke or myocardial infarction. Any symptoms indicative of neurologic affection such as dysarthria, double vision, or ataxia should be detailed. Syncope or near fainting is not related to vestibular insults, but may be caused by neurologic, circulatory, or metabolic disorders.

Clinical assessment of balance is dependent mainly on thorough and skillful assessment of history. Use of questionnaires before the interview may be helpful in some patients. However, extensive practice is required to improve the approach to lay people and to carry out a reliable analysis of symptoms using targeted questions.

It is most important to define the nature of dizziness. A sense of rotation or spinning reflects a vestibular lesion. Unsteadiness may point to a neurological lesion. Drop attacks with full consciousness may be because of otolith

dysfunction, and should be differentiated from syncope, which requires circulatory and metabolic assessments. Some patients may complain of heavy or light headedness as dizziness, which may accompany rhinosinusitis or psychological stress. Saying that these are the common expectations, it should be kept in mind that patients with vestibular schwannoma may not present with vertigo, rather with unilateral audiologic symptoms and mild unsteadiness. This occurs because it is a slow-growing tumor with ongoing adaptation. Occasionally, some patients may present with sudden hearing loss and vertigo, which may be attributed to hemorrhage and a sudden increase in size.

After the identification of true vertiginous patients, a detailed analysis of the attack should be carried out such as onset, course, and timing, and its duration, aggravators, and associated symptoms, whether audiologic, neurologic, or visual. Assessment of history of drug intake history is very important as some therapeutic drugs exert detrimental effects on balance such as salicylates or gentamycin. Moreover, alcohol or drug abuse may affect balance. Past exposure to head trauma or a whiplash injury may lead to some vague presentations.

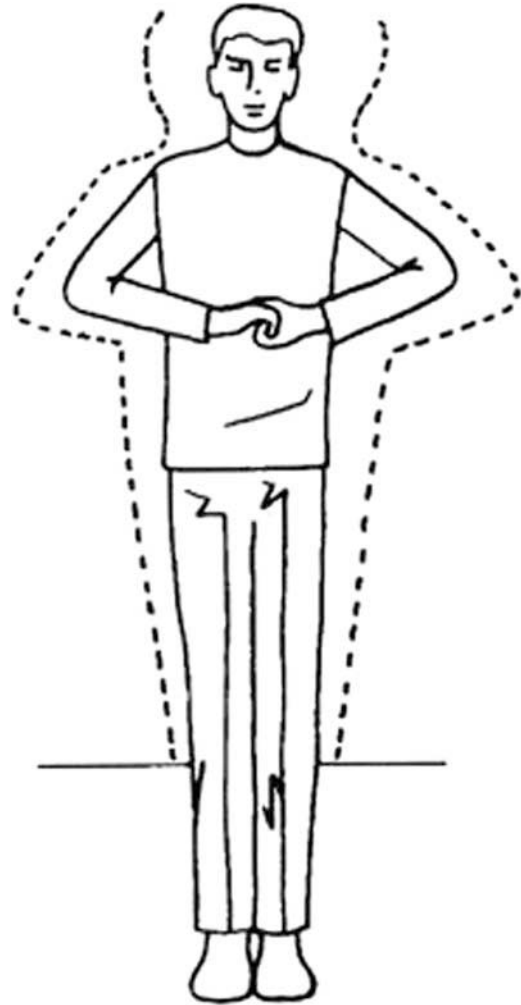
Peripheral lesions usually have an acute onset, severe symptoms, and a short duration of around 3 weeks compared with central lesions, which have a gradual onset, milder symptoms, and a prolonged course, usually for more than 3 months. There are many trials to classify every detail and differentiate symptoms accordingly. However, it is always better to categorize a specific disease on the basis of assessment of history. Principally, it should be kept in mind that this step may provide the only clue to an etiological diagnosis in many situations.

Physical examination should follow, focusing on the conscious state, pulse for arrhythmia, blood pressure for postural changes, a thorough ear examination to exclude a masked disease such as an attic erosion, and a careful examination of cranial nerves for any affection that may require a detailed neurologic evaluation.

Office tests of balance aim to assess the functional status, although with different sensitivity and specificity. They include stance and gait, limb coordination, nystagmus, positioning test, and dynamic vestibular testing.

The patient's stance should be noted in sharpened Romberg's position by making him/her clench his/her fingers (Fig. 3). If he/she sways with the eyes closed, he/she may have a vestibular lesion, whereas a sway with the eyes open may be because of a cerebellar disease or proprioceptive loss. The patient's gait should be observed while he/she enters the office, and it may show a shuffling or a high stepping gait, indicative of a neurologic disease. If the patient has a tandem (heel-to-toe) walk (Fig. 4) or deviates more than 30° in a stepping test (Fig. 5) for 30 s, a noncompensated lesion may be suspected, usually toward the side of the fall. Limb coordination examination should be carried out by successive rapid supination and pronation; inability to perform may be indicative of a cerebellar lesion. The finger-to-nose test may aid the

Figure 3



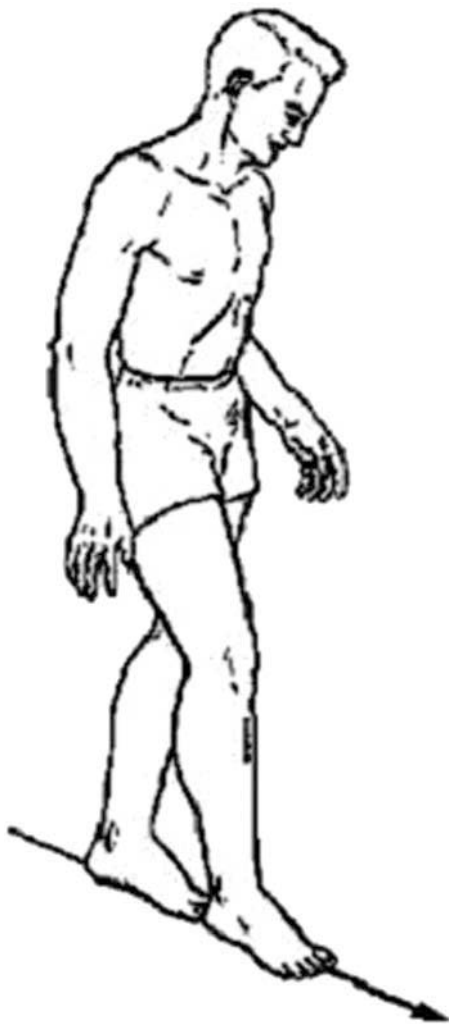Sharpened Romberg's test.

detection of tremors or dysmetria (hyper/hypo), suggesting cerebellar affection.

The patient's eyes should be examined for conjugate movement, paresis, or nystagmus in central and lateral gazes. If nystagmus is noted, it should be determined whether there is a typical pattern of a peripheral vestibular lesion or whether it is of central origin. The use of Frenzel's glasses is advantageous for this step as it eliminates visual fixation suppression, increasing minor nystagmus (Fig. 6).

If the patient's history is suggestive of benign paroxysmal positioning vertigo (BPPV), the Dix-Hallpike's positioning test should be carried out (Fig. 7) by rapidly moving the patient from sitting to 30° head hanging and 45° side looking to right and then repeat to the left side. A modified side-laying positioning test (Fig. 8) may be carried out in a small office or if the patient cannot hyperextend his/her neck. In either position, there should be a characteristic torsional nystagmus toward the downmost ear that occurs after a few seconds and lasts less than a minute, and becomes reversed on sitting and fatigued on repetition. If negative, the patients should be

Figure 4



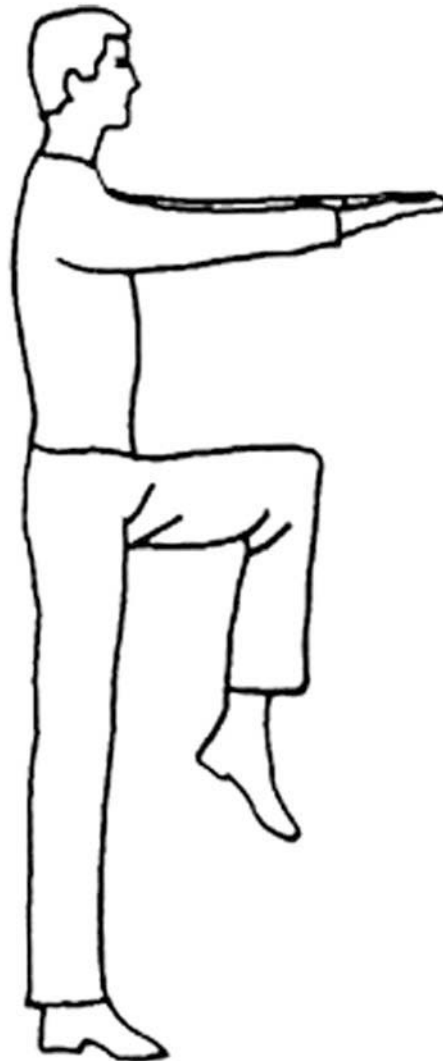Tandem walk.

examined for lateral canal BPPV by placing him/her in a supine position with the head tilted up 30° and turned to either side, to check for horizontal nystagmus.

Dynamic vestibular tests aim to show the asymmetric responses between normal and diseased sides, which may reflect subclinical uncompensation. Passively shake your patient's head with closed eyes for 30 seconds, then stop and on opening his/her eyes look for nystagmus, which reflects a vestibular lesion and its direction is usually to the side of the lesion. A more sensitive test is the head thrust test (Fig. 9); the patient's head should be briskly rotated from the center position to one side with his/her gaze fixed to the examiner's nose to check for eye stability. A corrective saccadic eye movement will occur on the diseased side. If a bilateral lesion is suspected, dynamic visual acuity should be tested, where the patient reads a Snellen's chart compared with his/her reading with a passive head shake; a decrease of more than two lines is usually abnormal.

A patient complaining of transient vertigo with a loud sound, nose blowing, or straining should be subjected to

Figure 5



Stepping test.

a fistula test using a pneumatic otoscope, which may indicate subtle nystagmus like in cases of a perilymph fistula or superior semicircular canal dehiscence; this should be followed by a high-definition computed tomography examination with special cuts in the direction of the superior canal.

If an anxiety reaction or a psychologic overlay is suspected, the patient should be asked to hyperventilate 20 deep breaths in rapid succession. Light headedness or tingling is experienced by anxious patients; however, if nystagmus is observed, it may be an indication of a lesion of the vestibular nerve toward the direction of the nystagmus.

Now, after completion of assessment of history and physical examination, answers may be available to the following questions:

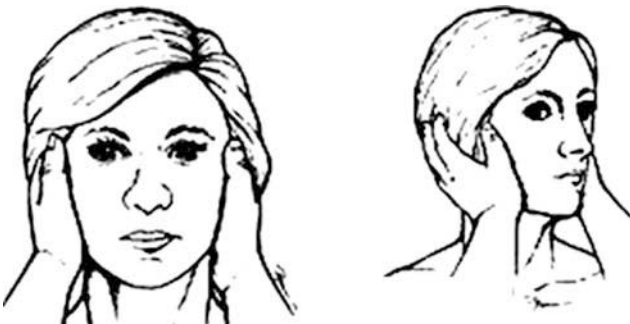- (1) Do I suspect a vestibular lesion? Peripheral or central?

Figure 6



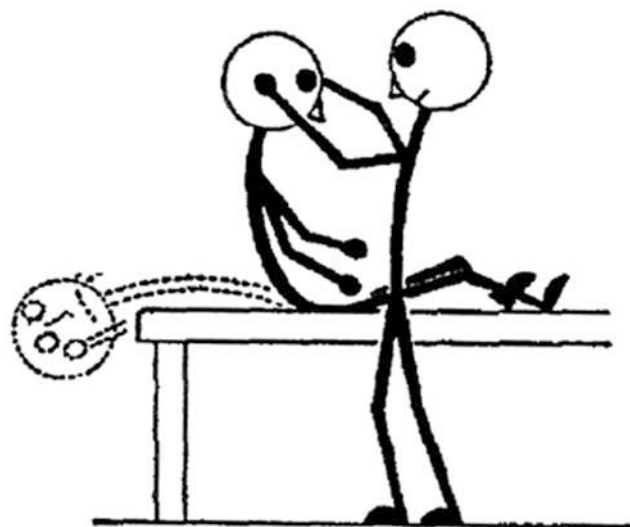Checking for nystagmus, which may be better with Frenzel's glasses.

Figure 7



Head thrust test.

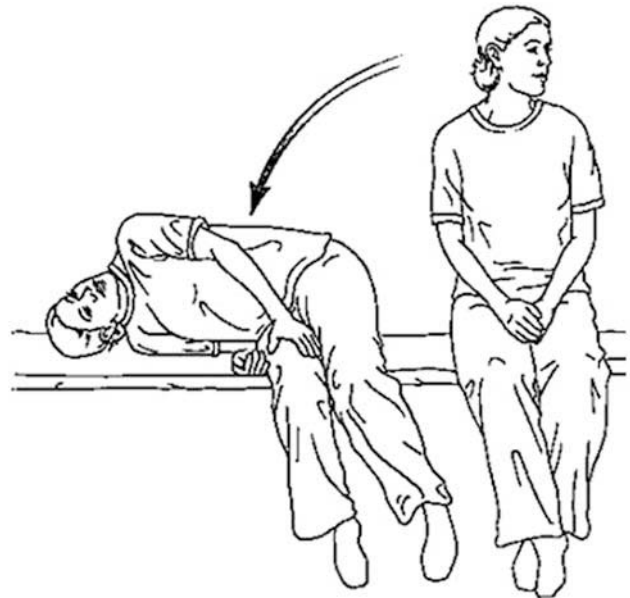Figure 8



Dix-Hallpike test.

- (2) Can I categorize a specific disease? BPPV, neuritis, Meniere's disease.
- (3) What is the functional state? Compensated/not, degree of disability.

Figure 9



Side-lying position.

Investigations

Sometimes, vague history and lack of findings necessitate further testing and investigations. General investigations, such as CBC, thyroid profile, etc, may be required according to the medical history. MRI is sometimes requested to exclude a life-threatening disease; however, its clinical yield is usually low. Nonetheless, it should be kept in mind that a diagnosis of Meniere's disease is made after excluding other causes. It is important to recall that the most cost-effective tests are audiologic evaluation and videonystagmography (VNG). They will help to supplement the assumptive diagnosis and will be used for monitoring progress.

Basic audiologic evaluation by pure tone and speech audiometry may aid identification of subtle hearing loss that may refer to a disease. Early sensorineural loss at low frequencies suggests Menier's disease. Poor speech discrimination may suggest a vestibular schwannoma. More advanced tests such as auditory brainstem response or electrocochleography are usually more of academic importance.

VNG using infrared goggles has replaced the electro-nystagmographic recordings. It incorporates a battery of tests. Oculomotor tracking (saccadic, pursuit, and optokinetic) should be performed, an abnormality of which may be indicative of a central lesion. Also, it helps detect spontaneous, gaze, or positional nystagmus, which may be indicative of a degree of uncompensated lesions. Most importantly, it includes bithermal caloric stimulation, which is still considered the keystone of vestibular assessment reflecting peripheral lesions; however, it has

some limitations as it tests only the horizontal canal, the superior vestibular nerve, and VOR.

In case of normal VNG results, vestibular evoked myogenic potential (VEMP) may be done. It may disclose the lesion as it tests another part of the vestibular system; namely saccule (otolith organ) and inferior vestibular nerve and medial VSR. Bilateral caloric weakness indicates the need for rotary chair testing as it shows the semicircular canal function at higher frequencies than the caloric stimulus. Computerized dynamic posturography tests the interaction between the various systems of balance control and is sometimes required to plan a customized rehabilitation program and follow-up of its success.

A clinical test of sensory interaction of balance, sometimes referred to as poor man posturography, may be helpful in the clinic. It involves four tests in Romberg's position with the patient standing on a hard floor or a thick foam pad to eliminate proprioception with the eyes open and closed.

When considering multiple tests of balance (Table 1), it should be kept in mind that each has its inherent limitations and its result should be interpreted in this context. These tests may suggest the disease system, but will not identify the underlying pathology or etiology.

Differential diagnosis

Vestibular neuronitis usually presents with an acute onset and a rapidly progressive vestibular crisis differing in severity according to the insult, and then follows a regressive course in a few days to complete resolution in 2–6 weeks. It is usually not associated with hearing loss; otherwise, a viral labyrinthitis would have been the diagnosis, and if associated with pain and facial palsy with blisters in the external ear canal or auricle, it may be Ramsey Hunt syndrome with its full picture. Also, it is important to exclude accompanying neurologic deficits such as diplopia, sensory loss, Horner's syndrome, or cerebellar ataxia; otherwise, cerebrovascular stroke is impending. Cerebellar infarcts may be mistaken for vestibular neuritis, but lack caloric weakness on VNG (Table 2).

Meniere's disease is characterized by recurrent attacks of rotary vertigo lasting minutes to hours (a typical attack should last at least 20 min), progressive sensorineural hearing loss, tinnitus, and a sense of ear fullness. Early during the course of the disease, the patient may be free of symptoms in between attacks that may last months, but with progressive deterioration. Treatment aims first to prevent attacks by salt restriction, lifestyle modifications and labyrinthine vasodilators as betahistine. The use of intratympanic steroids to revert the suspected autoimmune etiology may control attacks. While, intratympanic gentamycin may be used as a form of chemical labyrinthectomy aiming to turn a diseased ear to a nonfunctioning vestibular labyrinth allowing vestibular rehab program to be effective. Surgical treatments have

Table 1 Summary of tests to assess balance

Sensors	System	Clinical test	Quantitative test
Visual	Retino-ocular	Saccade Tracking Optokinetic	VNG
Vestibular	Vestibulo-ocular	Caloric Rotation	VNG RCT
Proprioception	Vestibulo-spinal Lateral Medial	Stance Stepping –	Craniocorpography VEMP
Interaction of all		CTSIB	CDP

CDP, computerized dynamic posturography; CTSIB, clinical test of sensory interaction of balance; RCT, rotary chair testing; VEMP, vestibular evoked myogenic potential; VNG, videonystagmography.

Table 2 Differential diagnosis of common vestibular lesions

Diseases	Tests	Findings
BPPV	Dix–Hallpike/ VNG	Torsional nystagmus
Vestibular neuritis	VNG Audiogram	Unilateral vestibular loss Normal hearing
Labyrinthitis	VNG Audiogram	Unilateral vestibular loss SNHL
Meniere's disease	VNG Audiogram	Unilateral vestibular loss SNHL (low frequency)
Ototoxicity	VNG/rotary chair Audiogram	Bilateral vestibular loss Bilateral SNHL
Vestibular schwannoma	Audiogram VNG MRI	Unilateral SNHL (poor speech discrimination) Unilateral vestibular loss Enhancing tumor

BPPV, benign paroxysmal positioning vertigo; SNHL, sensorineural hearing loss; VNG, videonystagmography.

markedly decreased with the use of intratympanic drugs. Migraine-associated vestibulopathy resembles Meniere's attacks, but lacks hearing loss or caloric weakness, and it is usually associated with characteristic headache.

BPPV has a characteristic scenario of episodic rotary vertigo that lasts a few seconds to less than a minute (average 30 s) that occurs in certain head positions such as looking at a top shelf or when rolling in bed. It is very common, especially in the elderly. The Dix–Hallpike test is diagnostic and treatment involves repositioning (Epley's) or liberatory (Semont's) maneuvers. BPPV is very common and it may be associated with other pathologies. Therefore, if the patient is cured of BPPV but still complains of unsteadiness, a concomitant pathology should be sought.

Vertebrobasilar insufficiency is characterized by episodic vertigo lasting a second that may occur with neck movements because of mechanical compromise of vertebral arteries. The Dix–Hallpike test may be negative, but positional nystagmus may be noted. Transcranial Doppler may be performed to document low blood flow, decreased flow during neck movement, or impaired vasoreactivity.

Orthostatic vertigo occurs for a few seconds with a sudden change in posture from lying down or sitting to standing. Near fainting is usually experienced by the patient. It may

occur in hypotensive patients or hypertensive patients with very tight control of blood pressure with drugs that do not allow for a vascular reserve to compensate. It is suspected if blood pressure differs from supine to erect 20 mmHg systolic and 10 mmHg diastolic. A tilting table test in the cardiology department may confirm postural hypotension or arrhythmias.

In the elderly, balance problems can result from combinations of subtle degenerative, infectious, or injury processes, none of which are clinically significant in isolation.

Treatment

Still, the aim of management should be to control symptoms and minimize disability. Therefore, in acute vertigo, antiemetics such as domperidol or vestibular suppressants such as dimenhydrinate, promethazine, and meclizine may be prescribed. In case of severe symptoms, treatment may be initiated with parenteral benzodiazepines, such as diazepam, which are very potent vestibular suppressants. If there are no medical contraindications, steroids may be used systemically in the acute stage if vestibular neuritis (analogous to sudden sensorineural hearing loss) or Meniere's disease (to control autoimmune etiology) is suspected.

Allowing earlier ambulation with simple indoor activities is advantageous to regain balance control earlier. The patient should be informed that balance control is more dependent on vision and proprioception; thus, he/she should be encouraged to move in light and avoid darkness. The patient should be instructed to simply hold nearby objects such as the stair railing during movement. A walking stick should be used according to

judgment, especially in elderly patients with multisystem affection.

Vestibular and balance rehab therapy is an exercise-based approach aiming at maximizing the use of residual vestibular and balance function to minimize the disabilities of dizzy patients. Some exercises are directed to augment the VOR, whereas others focus on VSR. Patients with stable peripheral lesions who have failed to achieve full compensation are good candidates for vestibular and balance rehab therapy. The importance of vestibular testing is stressed now in customization of programs for patients.

Conclusion

A dizzy patient must undergo systematic and multidisciplinary workup for the diagnosis and treatment of his/her disability. The final diagnosis should include interpretation of the clinical scenario and the collective results of the specific tests carried out. The patient should be advised during counseling that not all the findings become evident in the early stages of some diseases, and that time and close follow-up will eventually lead to the establishment of the diagnosis.

Acknowledgements

The author would like to express their gratitude for Professor Dr Mamoduh El-Gohary, Professor of Otolaryngology, Ain Shams University for his critical review of this article.

Conflicts of interest

There are no conflicts of interest.