

Audiovestibular manifestations in a radiologically confirmed enlarged vestibular aqueduct in congenital nonsyndromic sensorineural hearing loss in Egypt

Tarek Ghannoum^a, Sherif El-Minawi^a, Noha Hosni^a, Aml Aly^a and Amr Nassef^b

^aAudiology Unit, ENT Department, Cairo University and
^bRadiology Department, Cairo University, Cairo, Egypt

Correspondence to Sherif El-Minawi, Audiology Unit,
ENT Department, Cairo University, 11121 Cairo, Egypt
Tel: +00201001775611; e-mail: junghk@ewha.ac.kr

Received 30 June 2012

Accepted 11 October 2012

The Egyptian Journal of Otolaryngology
2013, 29:118–123

Background

Enlarged vestibular aqueduct (EVA), the most common radiological finding in children with sensorineural hearing loss, is associated with variable auditory and vestibular symptoms.

Aim of the work

The aim of this study was to determine vestibular findings in patients with EVA.

Patients and methods

Twenty patients diagnosed with sensorineural hearing loss and EVA were included in the study group and 20 healthy individuals matched for age and sex were included in the control group. Both groups were subjected to the following: complete history taking, general and neurological examination, full ENT examination, pure tone audiometry, tympanometry, high-resolution computed tomography, vestibular evoked myogenic potentials (VEMP), caloric test, and computerized dynamic posturography.

Results

EVA was bilateral in 14 patients and unilateral in six patients. The VEMP amplitude of wave p13–n23 was higher in ears with EVA and it correlated positively with its size. p13–n23 latencies did not differ significantly from the control group. The caloric test showed an absent response in four patients, unilateral weakness in six patients, and normal results in 10 patients. There was no statistically significant difference in the results of computerized dynamic posturography.

Conclusion

The results showed a larger VEMP amplitude, which is indicative of a third window lesion. Some patients showed abnormalities in the caloric test, which indicates a peripheral vestibular lesion. VEMP, caloric test, and computerized dynamic posturography testing were effective in the evaluation of patients with EVA.

Keywords:

caloric test, computerized dynamic posturography, enlarged vestibular aqueduct syndrome, enlarged vestibular aqueduct, nonsyndromic sensorineural hearing loss in children, vestibular aqueduct midpoint and operculum, vestibular evoked myogenic potentials

Egypt J Otolaryngol 29:118–123
© 2013 The Egyptian Oto - Rhino - Laryngological Society
1012-5574

Introduction

More than 200 years ago, temporal bone dissection by Carlo Mondini revealed wide vestibular aqueducts in patients with cochlear dysplasia (Mondini's dysplasia). In 1978, Valvassori and Clemis [1] were the first to use imaging and to find an association between enlargement of the vestibular aqueduct and sensorineural hearing loss (SNHL). The association of this anatomic anomaly with SNHL led them to coin the term 'large vestibular aqueduct syndrome' [2].

The vestibular aqueduct (VA) is a bony canal in the posterior temporal bone that runs from the vestibule to the posterior cranial fossa, and contains the endolymphatic duct that continues until it ends at the endolymphatic sac and the vestibular aqueduct vein [3].

The clinical presentation of enlarged vestibular aqueduct (EVA) varies markedly [4,5]. Hearing loss is not always present at birth; it is usually diagnosed in childhood. Hearing loss is usually sensorineural, but it could be conductive or mixed. It is usually progressive, but it may be sudden and fluctuating. It could be unilateral or bilateral [3].

Vestibular symptoms also varies. Its incidence has been reported to be 4–48%. It may be precipitated by minor head trauma or vigorous physical activity [6]. The characteristics of hearing affection have been studied extensively in patients with EVA, but not much information exists on vestibular affection in these patients.

Al Attia *et al.* [5] reported an 18-year-old Egyptian man with Pendred syndrome.

The aim of this study was to detect vestibular findings in patients with EVA.

Participants and methods

This study was carried out in the Audiology Outpatient Clinic, Kasr El-Aini Hospital, in the period between May 2009 and December 2010. The study was carried out on two groups: the study group included 20 children with nonsyndromic SNHL and diagnosed with EVA by high-resolution computed tomography (HRCT). The control group included healthy volunteers matched for age and sex.

Both groups were subjected to the following:

- (1) Full history taking to determine the onset of symptoms.
- (2) General and neurological examination.
- (3) Full ENT examination with a careful otoscopic examination.
- (4) Audiological evaluation.

All patients included in this study were subjected to the following:

Pure tone audiometry

Pure tone audiometry was performed using a two-channel clinical audiometer, orbiter 922, calibrated according to ISO standards.

- (1) Air conduction in the frequency range of 250–8000 Hz.
- (2) Bone conduction in the frequency range of 500–4000 Hz.

Speech audiometry

- (1) The speech reception threshold was determined using Arabic spondic words.
- (2) The word discrimination score was determined using Arabic phonetically balanced words.

Immittancemetry

Immittancemetry were performed using GSI 33 version II (GrasonStadler Middle Ear Analyzer; AudiometricsMN, South Tremont Street, Oceanside), calibrated according to ISO standards. Single-component, single-frequency tympanometry with a probe tone of 226 Hz was performed to exclude middle ear abnormalities. Testing of acoustic reflex threshold was carried out for the ipsilateral and contralateral elicited reflexes using pure tones at frequencies of 500, 1000, 2000, and 4000 Hz.

Radiological evaluation

Radiological evaluation was performed using the GE Light Speed Plus Multislice Machine (General Electric Managed Medical Imaging, Cooper City, Florida) (four slices); the slice thickness was 1.25 mm, with an interslice gap of 0 mm, and a bone window setting with a bone filter (edge enhancement + reconstruction). A

noncontrast computerized tomography (CT) scan of the petrous temporal bone in axial and coronal planes was performed in all patients included in the study. The radiological dimensions of the VA were measured at both the operculum and the midpoint on the right and the left side. CT scans were also checked as a whole for any other congenital anomalies or pathologies.

Vestibular testing

- (1) Vestibular evoked myogenic potentials (VEMP) testing was performed using AURIS Synapsys (Technopôle Chateau Gombert, Marseille, France) calibrated according to ISO standards. Patients were placed in the supine position on a gurney. They were instructed to turn and hold their heads as far as possible toward the side contralateral to the stimulated ear. Surface electromyograph activity was recorded by Ag/AgCl electrodes. The active electrode was placed over the middle portion of the ipsilateral sternocleidomastoid muscle. The reference and the ground electrodes were placed over the upper sternum and on the midline forehead, respectively. Auditory stimuli consisted of clicks presented to the ear ipsilateral to the contracted sternocleidomastoid muscle. The intensity was 100 dB nHL. Electromyograph responses from each side were amplified, bandpass filtered (20 Hz–2 kHz), and averaged using a Neuropack evoked potential recorder. Analysis time was 100 ms. The responses of 250 sound presentations were averaged. Thereafter, the mean peak latency (in ms) and peak-to-peak amplitude (in mV) of each peak (p13 and n23) were measured. The potentials (p13–n23) were known to be of vestibular origin [7].
- (2) Computerized dynamic posturography testing was carried out using Neurocom Smart Equi Test Balance Master (NeuroCom International Inc.; Clackamas, Oregon, USA) calibrated according to ISO standards. The sensory organization test (SOT) procedure requires patients to stand on a pressure-sensitive, dynamic tilted force plate facing a sway-referenced visual surround, instructed and strapped into a safety harness to prevent injury in the event of a loss of balance. The SOT comprises of three trials for each of six conditions representing different aspects of balance: SOT 1, eyes open, fixed surface and visual surrounds; SOT 2, eyes closed, fixed surface; SOT 3, eyes open, fixed surface, sway-referenced visual surround; SOT 4, eyes open, sway-referenced surface, fixed visual surround; SOT 5, eyes closed, sway-referenced surface; and SOT 6, eyes open, sway-referenced surface and visual surroundings [8].

Statistical analysis

Statistical analysis was carried out using SAS software, version 6.0 (SAS Institute, Cary, North Carolina, USA). The Fisher exact test was used to compare percentages and 95% CIs were calculated. All *P*-values less than 0.05 were considered to be statistically significant.

Results

The study group included 20 patients, 12 males (60%) and eight females (40%), with nonsyndromic SNHL since childhood with an EVA, which was diagnosed by HRCT. Their ages ranged from 6 to 28 years, mean age 13.20 ± 6.07 years.

The control group included 20 individuals, 10 males (50%) and 10 females (50%), with normal auditory function and normal radiological dimensions of the vestibular aqueduct. Their ages ranged from 10 to 27 years, mean age 15.70 ± 5.03 years. There was no statistically significant difference between the age of the patient and the control group ($P = 0.210$).

Audiological findings

All the patients in the study group had SNHL. They had normal tympanometry results reflecting normal middle ear function. The severity of hearing loss as determined by pure tone averages is presented in (Table 1).

Radiographic findings

The 20 patients with a vestibular aqueduct abnormality were diagnosed by an HRCT scan. The EVA was bilateral in 14 (70%) and unilateral in six (30%) patients. Therefore, the number of ears with EVA was 34 and the number of unaffected ears was six. HRCT did not indicate any associated congenital anomalies.

The range of the dimensions of the vestibular aqueduct at the midpoint and the operculum in ears with EVA, unaffected ears, and the control group is presented in (Table 2). There was a high statistically significant difference between the ears with EVA and the control group in the mean of vestibular aqueduct dimensions at the midpoint and operculum ($P = 0.000$), which were larger in the ears with EVA than the control group (Tables 3 and 4, respectively; Fig. 1).

Vestibular findings

In the 20 patients included in the study, six (30%) patients reported vestibular symptoms represented by frequent episodes of vertigo and nausea, mainly related to physical hyperactivity in four (20%) patients, and the other two (10%) patients had imbalance.

Vestibular evoked myogenic potentials findings

p13–n23 latencies and VEMP amplitude were recorded. There was a statistically significant difference between the ears with EVA and the control group in the mean of the VEMP amplitude, which was larger in ears with EVA. There was no statistically significant difference in the p13–n23 latencies between ears with EVA and the control group ($P = 1.000$ and 0.095 , respectively) (Fig. 2 and Table 4).

On comparing the VEMP parameters between ears with EVA and unaffected ears in patients with EVA, there was a highly statistically significant difference in the VEMP amplitude, which was higher in ears with EVA. There was no statistical significance of p13–n23 latencies (Table 5).

Computerized dynamic posturography testing

On comparing the SOT of computerized dynamic posturography between the patient and the control group, there was no statistically significant difference (Table 6).

There was a significant positive correlation between vestibular aqueduct diameter at the midpoint and operculum and the amplitude of VEMP ($r = 0.461$, $P = 0.041$ and $r = 0.588$, $P = 0.006$, respectively). There was no correlation between the size of the VA and the latency of p13–n23, degree of hearing loss, caloric test results, and the results of computerized dynamic posturography.

Discussion

EVA is a distinct entity in the spectrum of congenital inner ear anomalies and is known to be associated with hearing loss and vestibular symptoms in the pediatric population [9]. The aim of this study was to determine vestibular findings in patients with EVA.

In this study, we investigated 20 patients diagnosed with SNHL and EVA. The number of males (12) were greater than the number of females (eight). Some studies have found female preponderance, but others have reported the opposite [10]. Our study was in favor with the study group that comprised 16 patients (32 ears) suffering from nonsyndromic SNHL since childhood. The study group was divided according to the VA size into three groups: groups A, B, and C. Group A included six ears (four patients) with EVA, group B included 11 ears (seven patients) with borderline EVA, and group C included 15 ears (nine patients) with a normal VA size [4]. Similarly, there were no statistically significant differences between the three groups in laterality, degree of hearing loss, and audiometric configuration. There was no correlation between the VA midpoint and operculum and different variables (age and average pure tone thresholds). However, a significant correlation was found between the VA midpoint and operculum. EVA was diagnosed in six of 32 ears (18.75%) in the study sample. EVA size was not related to the degree of hearing loss or configuration [4,11,12].

In our patients, the severity of hearing loss ranged from slight to total, with 11.76% slight, 5.88% mild, 29.41% moderate, 23.54% moderately severe, and 29.41% total SNHL (Table 1). Arjmand and Webber [13–15] found that the hearing threshold level in patients with EVA

Table 1 Number of ears included in each degree of hearing loss in patients with enlarged vestibular aqueduct

Degree of SNHL	Slight	Mild	Moderate	MS	THL	Total
N (%)	4 (11.76%)	2 (5.88%)	10 (29.41%)	8 (23.54%)	10 (29.41%)	34 (100%)

MS, moderately severe; SNHL, sensorineural hearing loss; THL, total hearing loss.

Table 2 Test results of the dimensions of the vestibular aqueduct at both the midpoint and the operculum in mm between the ears with vestibular aqueduct of the patient group and the control group mean

	Ears with EVA (N=12)		Unaffected (N=6)		Control (N=40)	
	Min	Max	Min	Max	Min	Max
VA MP (mm)	0.50	3.80	0.70	0.70	0.40	0.90
VA OP (mm)	1.50	6.00	0.90	1.30	0.80	1.30

EVA, enlarged vestibular aqueduct; MP, midpoint; OP, operculum; VA, vestibular aqueduct.

Table 3 t-Test results of the dimensions of the vestibular aqueduct at both the midpoint and the operculum in mm between the ears with vestibular aqueduct of the patient group and the control group

	Ears with EVA (N=34 ears)		Control group (N=40 ears)		P-value
	Mean	SD	Mean	SD	
MP (mm)	1.49	0.93	0.63	0.15	0.000*
OP (mm)	2.42	1.33	1.01	0.17	0.000*

EVA, enlarged vestibular aqueduct; MP, midpoint; OP, operculum. *P-value highly significant (<0.01).

Table 4 t-Test results of p13, n23 latencies, and vestibular evoked myogenic potential amplitude between the ears with enlarged vestibular aqueduct and the control group

	Ears with EVA (N=34)		Control group (N=40)		P-value
	Mean	SD	Mean	SD	
p13 latency (ms)	12.57	2.34	13.17	1.66	1.000
n23 latency (ms)	18.99	3.19	21.00	2.25	0.095
Amplitude (µV)	72.12	48.67	29.85	9.98	0.020*

EVA, enlarged vestibular aqueduct. *P-value statistically significant (<0.05).

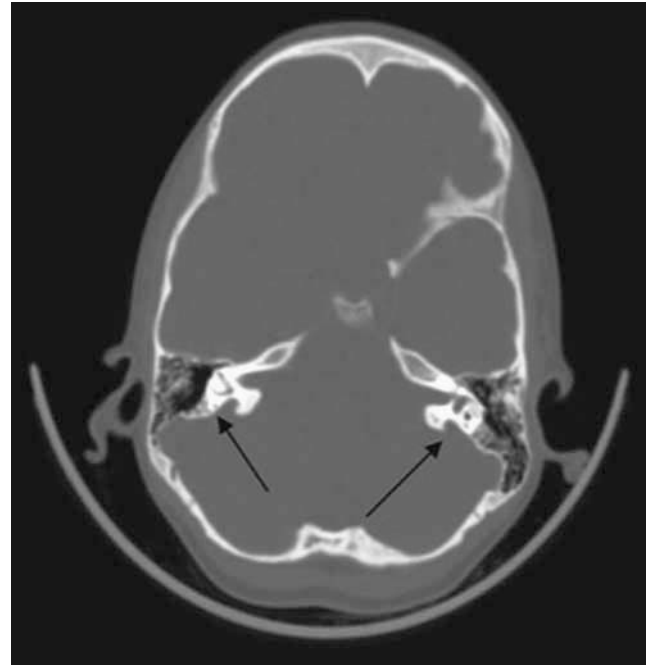
ranged from none to profound, with 65% of ears having mild or moderate hearing impairment. The mechanism of hearing loss is a breach in homeostasis of inner ear electrolytes and the transmission of cerebrospinal fluid pressure fluctuations through the patent VA [16].

The patients in our study were evaluated by axial and coronal HRCT. Dimopoulos *et al.* [17] found that the axial transverse view was sufficient for visualization of the VA. In contrast, Murray *et al.* [18] reported that coronal CTs allowed better visualization and it yielded a consistent measurement of the VA.

The definition of EVA is controversial; authors have defined VA enlargement as a diameter greater than or equal to 1.4, 1.5, 2.0, or 4.0 mm [17–19]. The place at which the VA is measured is also variable, from midway between the common crus and external aperture to the external pore [20,21]. Other authors have defined the EVA by comparing it with the posterior semicircular canals [22] or the diameter of the facial nerve [23,24].

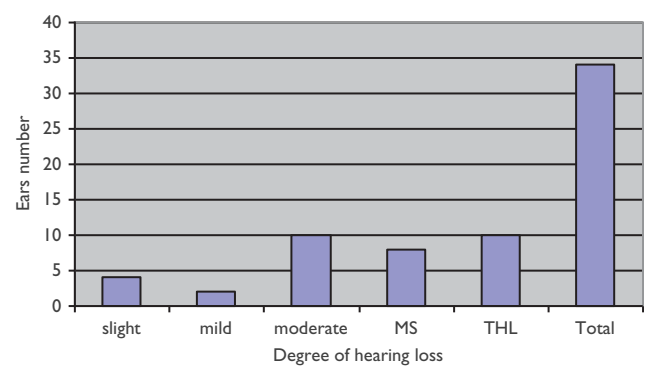
In this study, EVA was bilateral in 14 (70%) patients and unilateral in six (30%) patients. Studies have shown that

Figure 1



Computed tomography scan of a female child aged 10 years with bilateral enlarged vestibular aqueduct (arrows). Right vestibular aqueduct (VA) operculum=6.0 mm and midpoint=3.8 mm. Left VA operculum=5.2 mm and midpoint=3.8 mm.

Figure 2



The number of ears included in each degree of hearing loss. MS, moderately severe; THL, total hearing loss.

Table 5 t-Test results between ears with enlarged vestibular aqueduct and unaffected ears in patients with enlarged vestibular aqueduct

	Ears with EVA (N=34)		Unaffected ears (N=6)		P-value
	Mean	SD	Mean	SD	
p13 latency (ms)	12.57	2.34	12.76	1.80	0.821
n23 latency (ms)	18.99	3.19	18.20	2.48	0.508
Amplitude (µV)	17.12	48.67	34.33	8.45	0.000**

EVA, enlarged vestibular aqueduct. **P-value highly significant (<0.00).

Table 6 t-Test results of computerized dynamic posturography between the patient and the control group.

	Cases group (N=20)		Control group (N=20)		P-value
	Mean	SD	Mean	SD	
SOT 1	92.93	2.01	94.18	3.23	0.161
SOT 2	91.40	2.99	92.59	4.07	0.272
SOT 3	89.22	3.56	91.94	3.57	0.172
SOT 4	83.77	4.62	84.97	5.18	0.596
SOT 5	67.37	10.82	74.27	12.49	0.088
SOT 6	64.61	10.95	68.44	11.01	0.570
CS	78.50	4.73	81.20	4.24	0.323

CS, composite score; SOT, sensory organization test.
P-value significant (<0.05).

the most frequent finding is bilateral EVA. In different studies, the incidence of bilateral EVA has ranged from 55 to 94% [2,3,13,25]. This was also in agreement with the study of Abou-Elew *et al.* [4], who reported bilateral SNHL of variable degrees ranging from slight SNHL to total hearing loss. EVA was found in HRCT of four patients. Of the four patients, two patients had bilateral EVA and two patients had unilateral EVA. Seven patients had borderline EVA, four of them had bilateral borderline EVA, and the remaining three patients had unilateral borderline EVA. Nine patients had vestibular aqueduct dimensions that were within normal, six of them had bilateral normal VA, and the other three had unilateral normal VA.

In the current study, six (30%) patients had vestibular symptoms in the form of vertigo and nausea in four (20%) patients and imbalance in two (10%) patients. Many authors found that vestibular symptoms ranged from 12 to 46.9%; the complaints were vertigo, imbalance, and motor delay [5,26,27]. Yetiser *et al.* [12] found only two patients with Meniere-like vertigo [28]. Faye *et al.* [28] found that one patient complained of positional vertigo and in one patient, vertigo increased on coughing and sneezing. Vestibular complaints such as vertigo and imbalance may be caused by an underdeveloped vestibular [12,28].

In our patients, VEMP findings were larger VEMP amplitude in ears with EVA (34 ears) when compared with either the control group (40 ears) or unaffected ears (six ears) (Table 6). There was no statistically significant difference between ears with EVA when compared with the control group in p13–n23 latencies (Table 6).

Zhou and Gopen [9] found that ears with EVA had a higher VEMP amplitude, with no difference in p13–n23 latencies between ears with EVA and ears without EVA. Sheykholeslami *et al.* [10] and Merchant *et al.* [29] found VEMP abnormalities in patients with EVA, indicating possible saccular dysfunction. In addition, Sheykholeslami *et al.* [7] found a lower VEMP threshold in patients with EVA.

Sheykholeslami *et al.* [7] and Merchant *et al.* [29] found that VEMP findings were an indication of a third window lesion that causes the air-conducted sounds to be shunted away from cochlea to the vestibule, causing a larger deflection of the vestibular sensors within the

membranous labyrinth, which makes peripheral vestibular organs more sensitive to sound/pressure changes.

Many authors found this pattern of VEMP outcome in other third window lesions to indicate superior semicircular dehiscence syndrome, which involves a high VEMP amplitude [29–32].

In the patient group, 14 (70%) patients had bilateral EVA; four (20%) of them had an absent caloric response and the other 10 (50%) patients showed a caloric response that was within normal. The other six patients (30%) with unilateral EVA had unilateral weakness in the affected side.

Berrettini [11] examined 17 patients with EVA; 15 had bilateral EVA, two had unilateral EVA, and 13 patients (86%) had hypofunction or areflexia as a response to caloric testing. Emmet *et al.* [33] 30 found that nine (53%) of 17 patients with EVA had unilateral or bilateral weakness on electronystagmography testing.

The mechanism of vestibular abnormalities is believed to be because of the degeneration of vestibular hair cells as a result of osmotic changes or injury caused by chemical imbalance [34]. Yetiser *et al.* [12] postulated that vestibular dysfunction in all patients with EVA may be because of vestibular end-organ pathology.

On comparing the computerized dynamic posturography of SOT parameters between the study group and the control group, there was no statistically significant difference between the two groups. Unfortunately, these results obtained could not be compared with others because of the scarcity of researches at this point [35].

In this study, there was a significant positive correlation between the size of EVA and VEMP amplitude, but there was no correlation between the size of EVA and the degree of SNHL, VEMP latencies, caloric test results, and computerized dynamic posturography. Antonelli *et al.* [23] have reported a significant correlation between VA size and severity of hearing impairment in patients with EVA and cochlear dysplasia. Several other reports have failed to show a relationship between VA size and the degree of SNHL [12,36].

Conclusion

VEMP showed a larger VEMP amplitude, which is indicative of a third window lesion. Some patients showed abnormalities in the caloric test, which indicates a peripheral vestibular lesion. VEMP, caloric test, and computerized dynamic posturography testing were effective for the evaluation of patients with EVA.

Acknowledgements

Conflicts of interest

There are no conflicts of interest.

References

- 1 Valvassori GE, Clemis JD. The large vestibular aqueduct syndrome. *Laryngoscope* 1978; 88:723–728.
- 2 Zhou G, Gopen Q, Kenna MA. Delineating the hearing loss in children with enlarged vestibular aqueduct. *Laryngoscope* 2008; 118:2062–2066.
- 3 Santos S, Sgambatti L, Bueno A, Albi G, Suárez A, Dominguez MJ. Enlarged vestibular aqueduct syndrome: a review of 55 paediatric patients. *Acta Otorrinolaringol Esp* 2010; 61:338–344.
- 4 Abou-Elew M, El-Khousht M, El-Minawi MS, Selim M, Kamel AI. Enlarged vestibular aqueduct in congenital non-syndromic sensorineural hearing loss in Egypt. 2011;1–7.
- 5 Al Attia HM, El-Hag IA, Habab NH, Kazim S. Pendred's syndrome. *Emirates Med J* 1986; 4:140–142.
- 6 Schessel DA, Nedzelski JM. Presentation of large vestibular aqueduct syndrome to a dizziness unit. *J Otolaryngol* 1992; 21:265–269.
- 7 Arcand P, Desrosiers M, Dube J, Abela A. The large vestibular aqueduct syndrome and sensorineural hearing loss in the pediatric population. *J Otolaryngol* 1991; 20:247–250.
- 8 Oh AK, Ishiyama A, Baloh RW. Vertigo and the enlarged vestibular aqueduct syndrome. *J Neurol* 2001; 248:971–974.
- 9 Zhou G, Gopen Q. Characteristics of vestibular evoked myogenic potentials in children with enlarged vestibular aqueduct. *Laryngoscope* 2011; 121:220–225.
- 10 Sheykholeslami K, Schmerber S, Kermany MH, Kaga K. Vestibular-evoked myogenic potentials in three patients with large vestibular aqueduct. *Hear Res* 2004; 190 (1–2): 161–168.
- 11 Berrettini S, Forli F, Bogazzi F, Neri E, Salvatori L, Casani AP, Franceschini SS. Large vestibular aqueduct syndrome: audiological, radiological, clinical, and genetic features. *Am J Otolaryngol* 2005; 26:363–371.
- 12 Yetiser S, Kertmen M, Özkaptan Y. Vestibular disturbance in patients with large vestibular aqueduct syndrome (LVAS). *Acta Otolaryngol* 1999; 119:641–646.
- 13 Arjmand EM, Webber A. Audiometric findings in children with a large vestibular aqueduct. *Arch Otolaryngol Head Neck Surg* 2004; 130:1169–1174.
- 14 Boston M, Halsted M, Meinzen-Derr J, Bean J, Vijayasekaran S, Arjmand E, *et al.* The large vestibular aqueduct: a new definition based on audiological and computed tomography correlation. *Otolaryngol Head Neck Surg* 2007; 136:972–977.
- 15 Zalzal GH, Tomaski SM, Vezina LG, Bjornsti P, Grundfast KM. Enlarged vestibular aqueduct and sensorineural hearing loss in childhood. *Arch Otolaryngol Head Neck Surg* 1995; 121:23–28.
- 16 Owen Black F. What can posturography tell us about vestibular function? *Ann NY Acad Sci* 2001; 942:446–464.
- 17 Dimopoulos PA, Smedby Ö, Wilbrand HF. Anatomical variations of the human vestibular aqueduct: Part II. A radioanatomical study. *Acta Radiol Suppl* 1996; 37:33–41.
- 18 Murray LN, Tanaka GJ, Cameron DS, Gianoli GJ. Coronal computed tomography of the normal vestibular aqueduct in children and young adults. *Arch Otolaryngol Head Neck Surg* 2000; 126:1351–1357.
- 19 Bamiou DE, Phelps P, Sirimanna T. Temporal bone computed tomography findings in bilateral sensorineural hearing loss. *Arch Dis Child* 2000; 82:257–260.
- 20 Benton C, Bellet PS. Imaging of congenital anomalies of the temporal bone. *Neuroimaging Clin N Am* 2000; 10:35–53.
- 21 Levenson MJ, Parisier SC, Jacobs M, Edelstein DR. The large vestibular aqueduct syndrome in children: a review of 12 cases and the description of a new clinical entity. *Arch Otolaryngol Head Neck Surg* 1989; 115:54–58.
- 22 Okumura T, Takahashi H, Honjo I, Takagi A, Mitamura K, Jackler RK. Sensorineural hearing loss in patients with large vestibular aqueduct. *Laryngoscope* 1995; 105 (3 l): 289–294.
- 23 Antonelli PJ, Nail AV, Lemmerling MM, Mancuso AA, Kubilis PS. Hearing loss with cochlear modiolar defects and large vestibular aqueducts. *Am J Otol* 1998; 19:306–312.
- 24 Jackler RK, De La Cruz A. The large vestibular aqueduct syndrome. *Laryngoscope* 1989; 99:1238–1243.
- 25 Pollock A, Curtin H, Towbin R. Methods of examination: radiologic aspects. In: Bluestone CD, Stool SE, Kenna MA, editors. *Pediatric Otolaryngology*. Vol. 1 4th ed. Philadelphia, PA: WB Saunders Co.; 2003. pp. 230–271.
- 26 Antonelli PJ, Varela AE, Mancuso AA. Diagnostic yield of high-resolution computed tomography for pediatric sensorineural hearing loss. *Laryngoscope* 1999; 109:1642–1647.
- 27 Grimmer JF, Hedlund G. Vestibular symptoms in children with enlarged vestibular aqueduct anomaly. *Int J Pediatr Otorhinolaryngol* 2007; 71: 275–282.
- 28 Faye MB, Bertholon P, Tringali S, Merzougui N, Chardon-Roy S, Pouget J, Martin C. Vertigo revealing unilateral enlarged vestibular aqueduct in two adults. *Fr ORL* 2005; 87:71–74.
- 29 Merchant SN, Nakajima HH, Halpin C, Nadol JB Jr, Lee DJ, Innis WP, *et al.* Clinical investigation and mechanism of air-bone gaps in large vestibular aqueduct syndrome. *Ann Otol Rhinol Laryngol* 2007; 116:532–541.
- 30 Okumura T, Takahashi H, Honjo I, Naito Y, Takagi A, Tuji J, Ito J. Vestibular function in patients with a large vestibular aqueduct. *Acta Otolaryngol Suppl* 1995; 520:323–326.
- 31 Zhou G, Gopen Q, Poe DS. Clinical and diagnostic characterization of canal dehiscence syndrome: a great otologic mimicker. *Otol Neurotol* 2007; 28:920–926.
- 32 Mikulec AA, McKenna MJ, Ramsey MJ, Rosowski JJ, Herrmann BS, Rauch SD, *et al.* Superior semicircular canal dehiscence presenting as conductive hearing loss without vertigo. *Otol Neurotol* 2004; 25:121–129.
- 33 Emmett JR. The large vestibular aqueduct syndrome. *Am J Otol* 1985; 6:387–415.
- 34 Minor LB. Clinical manifestations of superior semicircular canal dehiscence. *Laryngoscope* 2005; 115 (10 l): 1717–1727.
- 35 Ma H, Han P, Liang B, Tian Z-L, Lei Z-Q, Kong W-J, Feng G-S. Multislice spiral computed tomography imaging in congenital inner ear malformations. *J Comput Assist Tomogr* 2008; 32:146–150.
- 36 Streubel S-O, Cremer PD, Carey JP, Weg N, Minor LB. Vestibular-evoked myogenic potentials in the diagnosis of superior canal dehiscence syndrome. *Acta Otolaryngol Suppl* 2001; 545:41–49.