

Vogt–Koyanagi–Harada syndrome (review of case reports)

Sameer AlBahkaly, Arwa AlKhunaizi and Ziad Algamdi

Department of Surgery, King Abdulaziz Medical City, King Fahad National Guard Hospital, Riyadh, Kingdom of Saudi Arabia

Correspondence to Arwa Alkhunaizi, MD, ENT intern, Department of surgery, King Abdulaziz Medical City, King Fahad National Guard Hospital, P.O. Box 46863, Riyadh 11442, Kingdom of Saudi Arabia
Tel: +966 125 2008 x14119;
e-mail: arwa.alkhunaizi@hotmail.com

Received 3 April 2012
Accepted 24 June 2012

The Egyptian Journal of Otolaryngology
2012, 28:275–277

Vogt–Koyanagi–Harada (VKH) disease, also known as uveomeningitic syndrome, is a multisystem autoimmune disorder directed against any melanocyte-containing organ, including the eye, central nervous system, auditory, and integumentary system. We present a case of an African woman with total deafness and blindness of VKH, and discuss the histological characteristics, and review the classification and the management of VKH. The most important factor for prognosis is the immediate treatment. The rarity of this syndrome makes its diagnosis a challenge and the presence of deafness, tinnitus, and vertigo must be considered in its diagnosis.

Keywords:

human leukocyte antigen, immunomodulatory therapy, Vogt–Koyanagi–Harada

Egypt J Otolaryngol 28:275–277
© 2012 The Egyptian Oto - Rhino - Laryngological Society
1012-5574

Introduction

Vogt–Koyanagi–Harada (VKH) disease is a multisystem disorder characterized by granulomatous panuveitis with exudative retinal detachments that is often associated with neurologic, cutaneous manifestations, and involve membranes, mucosa, and the inner ear. VKH disease occurs more commonly in patients with a genetic predisposition to the disease, including Asian, Middle Eastern, Hispanic, and Native American populations. Several human leukocyte antigen (HLA) associations have been found in patients with VKH disease, including HLA-DR4, HLA-DR53, and HLA-DQ.

Patients with bilateral anterior uveitis with vitiligo, poliosis, alopecia, and dysacusia were first described by Vogt in 1906 and then by Koyanagi in 1929 [1,2]. Harada [3] described a case of posterior uveitis with exudative retinal detachment and pleocytosis of cerebrospinal fluid, in 1926. Since these reports, it has become clear that these features are all present in a single systemic inflammatory condition, which has become known as VKH disease.

With such a wide spectrum of disease, typical cases of VKH disease are uncommon. To help clarify the diagnostic characteristics of VKH disease, an International Committee on Nomenclature established revised criteria for the diagnosis of VKH disease. The revised criteria defined three categories of disease complete VKH, incomplete VKH, and probable VKH. Common to all forms of VKH disease are the requirements that (a) patients have no previous history of ocular trauma or surgery, (b) patients have no evidence of another ocular disease on the basis of clinical or laboratory evidence, and (c) patients have bilateral ocular involvement.

The otolaryngology's aspects occur at the uveitic stage. Hearing loss is sensorineural bilateral and rapidly progressive, and may be associated with tinnitus. The vestibular component is less affected by vertigo, nystagmus, and abnormal vestibular reflex. The otolaryngology's

manifestations do not influence the recurrences or complications and they also have a good prognosis with an established treatment. The diagnosis of this syndrome is made on the basis of clinical criteria, but audiological tests may be useful. The therapy is corticosteroid-based.

Case report

A 32-year-old Somalian woman presented with a history of progressively decreasing vision and mild tinnitus diagnosed primarily as cataract. After 2 months, she developed partial loss of hearing, throbbing headache, and occasional dizziness. Our primary impression was that headache, hearing loss, and blindness may have been because of viral or immune-mediated disease. Unfortunately, later, the patient developed sudden complete deafness and blindness. The impression was either VKH syndrome or neurological lesion such as multiple sclerosis.

Hearing assessment of the patient was carried out. Audiogram showed profound total hearing loss; otoacoustic emissions were absent bilaterally and tympanogram was normal bilaterally. Eye examination shows some surgical changes in the left pupil and cataract on the right eye. MRI showed hypodense thalamus. Brucella was negative. Complete blood count, liver function test, renal function test, erythrocyte sedimentation rate, and anti-nuclear antibody were normal. Patient refused to undergo lumbar puncture.

The patient was started on steroid tablets, but there was no improvement at all; she was then given steroid. The patient is now stable and much better than before. She can only see very near objects and otherwise her sister guides her. This patient was sent for cochlear implantation.

Discussion

VKH evolves in phases, classified as prodromal, uveitic, convalescent, and chronic/recurrent.

In the prodromal phase, patients develop nonspecific systemic symptoms such as fever, headache, nausea, meningismus, vertigo, and dysacusis. Rarely, focal neurologic signs such as cranial nerve palsies and optic neuritis can occur. Spinal tapping, for the collection of cerebrospinal fluid, typically shows an increase in inflammatory cells (pleocytosis), with a predominance of lymphocytes.

Ocular symptoms will develop in acute ocular phase (uveitic phase), which occur 3–5 days after the prodromal phase, these symptoms include: blurred vision, photophobia, and ocular pain. Bilateral granulomatous uveitis, and particularly choroiditis, is common. The optic nerve may be swollen and hyperemic in up to 87% of patients [4]. The ocular manifestations are clinically, histologically, and angiographically similar to those of sympathetic ophthalmia [5].

In the convalescent stage, after the appropriate treatment, the exudative detachments gradually subside and the uveitis abates. The convalescent stage can persist for months.

In the chronic/recurrent phase, VKH uveitis can be prolonged or can recur. Most vision-threatening complications occur in the chronic recurrent phase. Long-term ocular complications of the disease and treatment also include cataracts, typically, posterior subcapsular and secondary angle closure [6].

Systemic disease is a major characteristic of VKH. The most commonly involved sites are the meninges, skin, and inner ears. The involvement of the ear has been shown to be present in almost 30% of patients early in the course of the disease, and any hearing loss is usually associated with the ocular signs and is most normally retrocochlear [7]. The hearing loss may be sudden in onset and is frequently associated with tinnitus and vertigo. In addition, deafness is normally cochlear in type. In addition, VKH syndrome has been linked to cranial nerve palsies [8]. Neurologic symptoms can occur during the prodromal state. Meningeal involvement typically presents with headache and stiff neck. Spinal tapping shows pleocytosis 1–2 weeks before ocular findings. Encephalitis may occur with cranial nerve palsies, aphasia, personality changes, loss of consciousness, and seizures. Auditory symptoms are common and include tinnitus, high-frequency hearing loss, and vertigo. The convalescent stage can result in skin involvement. Vitiligo of the face, hands, shoulder, breast, and back is common. Alopecia and poliosis can also occur.

Other conditions have been associated with VKH. A series of three patients with an onset of VKH and Guillain–Barre syndrome within weeks has been reported [9]. A few autoimmune disorders involve both the eyes and the ears (e.g. Cogan's syndrome).

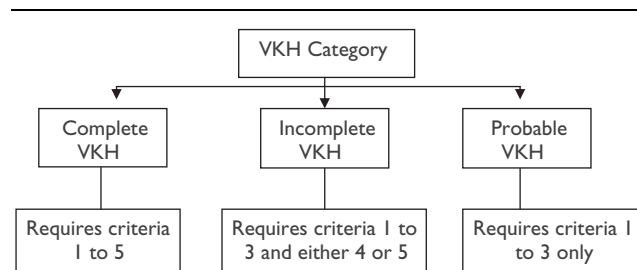
VKH occurs most commonly in pigmented individuals such as Asians, Hispanics, Native Americans, Asian Indians, and Middle Easterners. It is rare in whites, but, interestingly, also rare in Africans. Women are affected slightly more often than men. VKH most commonly occurs between the ages of 20 and 50 years, but has been reported in a child as young as 4 years of age [10].

It seems to have a genetic predisposition. It has been established that VKH disease is highly related to HLADRB1* 0405 in individuals of Japanese and Asian descent [11,12]. The results of a study showed that the majority of pathogenic antigens may be presented to the T cells with the HLADRB1* 0405 molecule [13].

The tyrosinase family proteins are the enzymes for melanin formation and are expressed specifically in melanocytes, which indicates that tyrosinase family proteins are the target antigens of immune reactions induced by VKH disease. In addition, this supports the hypothesis that T cells autoreactive against tyrosinase family proteins probably play a pathogenic role in the induction and development of VKH disease [14].

Diagnostic criteria were initially proposed and have been subsequently revised [15]. The revised criteria subdivide definite VKH into complete, incomplete, and probable categories on the basis of the manifestations observed (Fig. 1, Table 1).

Figure 1



Diagnostic revised criteria for VKH base on its category. VKH, Vogt–Koyanagi–Harada.

Table 1 Revised diagnostic criteria for Vogt–Koyanagi–Harada

- (1) No history of penetrating ocular trauma
- (2) No evidence of other ocular or systemic disease
- (3) Bilateral ocular disease – either (a) or (b)
 - (a) Early manifestations of disease
 - (i) Diffuse choroiditis manifested as either
 - (1) Focal areas of subretinal fluid or
 - (2) Bullous serous retinal detachments
 - (ii) If equivocal fundus findings then both of below
 - (1) FA showing focal delayed choroidal perfusion, pinpoint leakage, pooling within subretinal fluid, and optic nerve staining
 - (2) Ultrasound showing diffuse choroidal thickening without posterior scleritis.
 - (b) Late manifestations of disease
 - (i) History suggestive of above, or both ii and iii, or multiple from iii
 - (ii) Ocular depigmentation
 - (1) Sunset glow fundus, or
 - (2) Sugiura sign
 - (iii) Other ocular signs
 - (1) Nummular chorioretinal depigmented scars, or
 - (2) RPE clumping, or
 - (3) Recurrent or chronic anterior uveitis
- (4) Neurologic/auditory findings
 - (a) Meningismus
 - (b) Tinnitus
 - (c) CSF pleocytosis
- (5) Integumentary findings
 - (a) Alopecia
 - (b) Poliosis
 - (c) Vitiligo

CSF, cerebrospinal fluid; FA, fluorescein angiography; RPE, retinal pigment epithelium.

The use of the terms 'typical' and 'atypical' VKH and also of the term 'Harada disease' when describing cases of isolated posterior pole findings has been discouraged [15].

The standard initial therapy for VKH is with prompt, aggressive corticosteroids. Early therapy with a slow taper has been shown to improve the prognosis by reducing the length of disease, the incidence of a convalescent phase, and by decreasing extraocular manifestations of VKH [16]. Some investigators argue for initial therapy with pulse high-dose intravenous corticosteroids in all patients [17].

However, a review study for VKH patients carried out in 2006 that reviewed 24 patients from 1981 to 1997 found that one patient experienced progressive hearing loss over the 2-year treatment course of his illness that could be reversed partially with steroids. No patients developed sensorineural hearing loss requiring amplification.

It is unknown whether steroid use halts the progression of SNHL, but longitudinally performed audiograms in one patient in this series suggest that the loss may be partially reversible after steroid treatment.

Conclusion

Despite appropriate treatment with steroid therapy, many patients develop recurrences and associated complications. Therefore, nonsteroidal immunomodulatory therapy has become essential in the treatment of VKH [18–20]. From a review of the literature, we recommend absolutely without any hesitation that nonsteroidal immunomodulatory therapy should be considered as a first-line therapy for VKH.

Acknowledgements

Conflicts of interest

There are no conflicts of interest.

References

- 1 Koyanagi Y. Dysakusis, Alopecia und Poliosis bei schwerer Uveitis nicht traumatischen Ursprungs. *Klin Monatsbl Augenheilkd* 1929; 82:194–211.
- 2 Vogt A. Early graying of cilia and remarks about the genaten sudden Eintreitt of this change. *Klin Monatsbl Augenheilkd* 1906; 44:228–242.
- 3 Harada E. Acute diffuse choroiditis. *Acta Soc Ophthalmol Jpn* 1926; 30:356–378.
- 4 Ohno S, Minakawa R, Matsuda H. Clinical studies of Vogt-Koyanagi-Harada's disease. *Jpn J Ophthalmol* 1988; 32:334–343.
- 5 Rao NA. Mechanisms of inflammatory response in sympathetic ophthalmia and VKH syndrome. *Eye (Lond)* 1997; 11 (Pt 2): 213–216.
- 6 Read RW, Rechodouni A, Butani N, Johnston R, LaBree LD, Smith RE, Rao NA. Complications and prognostic factors in Vogt-Koyanagi-Harada disease. *Am J Ophthalmol* 2001; 131:599–606.
- 7 Rao N, Blackman H, Franklin R, Meislar D, Sheppard J, Chalmers B, et al. *VKH Syndrome, Panuveitis, Basic and Clinical Science Course, Sec 9*. San Francisco: American Academy of Ophthalmology; 1998. pp. 130–133.
- 8 Hiraki Y, Kuwasaki N, Shoji H, Kaji M, Kuboshiro T. VKH syndrome with multiple cranial nerve palsies. *Rinsho Shinkeigaku* 1981; 29:54–58.
- 9 Najman-Vainer J, Levinson RD, Graves MC, Nguyen B-T, Engstrom RE Jr., Holland GN. An association between Vogt-Koyanagi-Harada disease and Guillain-Barré syndrome. *Am J Ophthalmol* 2001; 131:615–619.
- 10 Gruich MJ, Evans OB, Storey JM, Bradley ST, Chen CJ. Vogt-Koyanagi-Harada syndrome in a 4-year-old child. *Pediatr Neurol* 1995; 13:50–51.
- 11 Shindo Y, Inoko H, Yamamoto T, Ohno S. HLA-DRB1 typing of Vogt-Koyanagi-Harada's disease by PCR-RFLP and the strong association with DRB1(*0405 and DRB1(*0410. *Br J Ophthalmol* 1994; 78:223–226.
- 12 Islam SMM, Numaga J, Fujino Y, Hirata R, Matsuki K, Maeda H, Masuda K. HLA class II genes in Vogt-Koyanagi-Harada disease. *Invest Ophthalmol Vis Sci* 1994; 35:3890–3896.
- 13 Yamaki K, Gocho K, Hayakawa K, Kondo I, Sakuragi S. Tyrosinase family proteins are antigens specific to Vogt-Koyanagi-Harada disease. *J Immunol* 2000; 165:7323–7329.
- 14 Yamaki K, Gocho K, Sakuragi S. Pathogenesis of Vogt-Koyanagi-Harada disease. *Int Ophthalmol Clin* 2002; 42:13–23.
- 15 Read RW, Holland GN, Rao NA, Tabbara KF, Ohno S, Arellanes-Garcia L, et al. Revised diagnostic criteria for Vogt-Koyanagi-Harada disease: report of an international committee on nomenclature. *Am J Ophthalmol* 2001; 131:647–652.
- 16 Rubsamen PE, Gass JDM. Vogt-Koyanagi-Harada syndrome: clinical course, therapy, and long-term visual outcome. *Arch Ophthalmol* 1991; 109: 682–687.
- 17 Sasamoto Y, Ohno S, Matsuda H. Studies on corticosteroid therapy in Vogt-Koyanagi-Harada disease. *Ophthalmologica* 1990; 201:162–167.
- 18 Jabs DA, Rosenbaum JT, Foster CS, Holland GN, Jaffe GJ, Louie JS, et al. Guidelines for the use of immunosuppressive drugs in patients with ocular inflammatory disorders: recommendations of an expert panel. *Am J Ophthalmol* 2000; 130:492–513.
- 19 Rao NA. Management of intraocular inflammation. In: Ryan SJ, editor. *Retina*. Vol. 2, 3rd ed. Philadelphia: Mosby; 2001.
- 20 Paredes I, Ahmed M, Foster CS. Immunomodulatory therapy for Vogt-Koyanagi-Harada patients as first-line therapy. *Ocul Immunol Inflamm* 2006; 14:87–90.