

# Infralabyrinthine approach as a conservative management of petrositis, our clinical experience in five patients

Mohammad Saad Hasaballah and Tamer Abdel Wahab Abo El Ezz

Department of Otolaryngology, Ain Shams University, Cairo, Egypt

Correspondence to Tamer Abdel Wahab Abo El Ezz, Department of ENT, Faculty of Medicine, Ain Shams University, 11421 Cairo, Egypt  
Fax: +00 224 312 775;

**Received** 11 November 2011

**Accepted** 26 February 2012

**The Egyptian Journal of Otolaryngology**  
2012, 28:104–107

## Introduction

Although apical petrositis has been typically managed with aggressive surgical intervention, the advent of antibiotics facilitated the conservative management of selected cases, however some resistant cases may still need conservative surgical intervention.

## Objective

To present our experience with apical petrositis successfully treated via an infralabyrinthine approach with the preservation of both middle and the inner ear after failure of aggressive medical treatment.

## Methods

A retrospective study done by collecting the data of five patients with Gradenigo's syndrome who underwent surgical drainage by the authors via an infralabyrinthine approach. The aim of this approach was to preserve the cochleovestibular function instead of translabyrinthine approach as the five patients had variable degrees of pure conductive deafness without any evidence of labyrinthine affection.

## Results

All patients started showing an improvement immediately after surgery, with the disappearance of diplopia and the lateral rectus palsy being the first outcome to be noted. In our series, only one patient developed mild vertigo and vomiting that lasted for 3 days, and was treated with sedation and antiemetics.

## Conclusion

Infralabyrinthine approach is a safe and direct way to drain inflammatory exudates from petrous apex.

## Keywords:

Gradenigo's, infralabyrinthine, petrositis

Egypt J Otolaryngol 28:104–107  
© 2012 The Egyptian Oto - Rhino - Laryngological Society  
1012-5574

## Introduction

The petrous apex represents one of the most surgically inaccessible areas of the skull base. The diagnosis and management of lesions in this area are particularly challenging [1]. In 1904, Gradenigo [2] described a syndrome characterized by a triad of the sixth nerve palsy, pain in the distribution of the fifth nerve, and otitis media that came to be known as Gradenigo syndrome. Apical petrositis was a common complication of acute mastoiditis before the widespread use of antibiotics. The trigeminal ganglion and the sixth cranial nerve are separated from the bony petrous apex only by the dura mater, that's why they are vulnerable to inflammatory processes occurring within this region [3]. The involvement of the sixth cranial nerve is caused by the spread of inflammation through the Dorello's canal under the petroclinoid ligament [4]. The absence of abducent palsy, however, does not automatically exclude apical petrositis from the findings [5].

The petrous apex is a pyramidal projection of bone that comprises the most medial portion of the temporal bone. The lateral base of this pyramid is defined by the inner

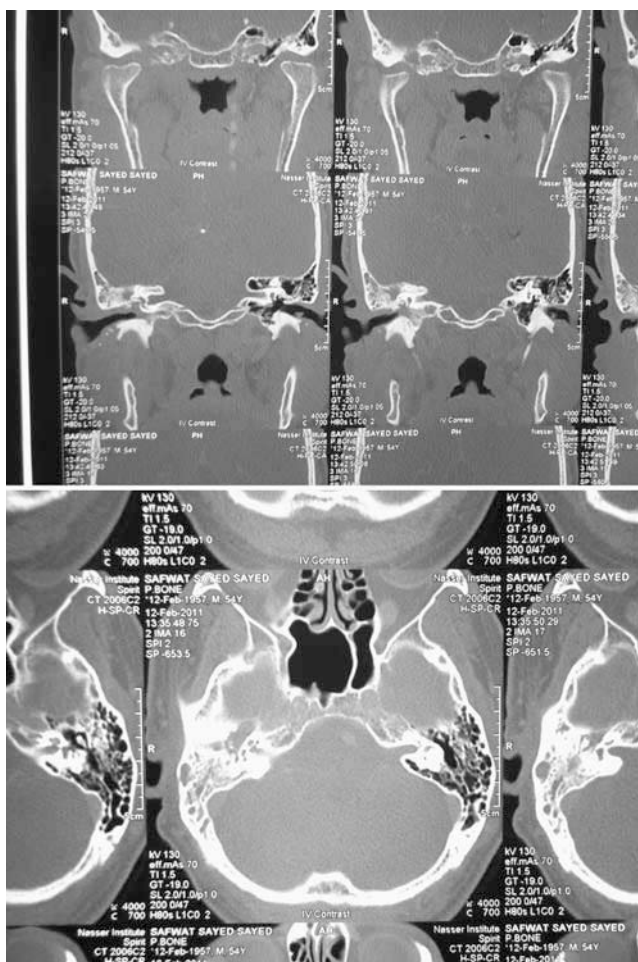
ear, the eustachian tube, and the intratemporal carotid artery [6].

Computed tomography (CT) and MRI are useful in the diagnosis and management of Gradenigo's syndrome [7]. The interpretation of imaging studies of the petrous apex, however, is complicated by normal anatomical variations and the degree of pneumatization in this region. Although 80% of the temporal bones are pneumatized, air cells extending to the petrous apex occur in only 30% of cases [8]. There are two main groups of apical cells: those around the semicircular canals and those around the cochlea. The bony labyrinth forms a natural barrier to the free drainage of mucus or pus from these cells [9].

Although the disease has been typically managed with aggressive surgical intervention, the advent of antibiotics has facilitated the conservative management of selected cases and it appears that the issue of optimal treatment of the disease is yet to be settled [10].

Here, we report five patients with apical petrositis presenting with the typical Gradenigo's triad who were

Figure 1



Coronal and axial cuts in a 55-year-old man showing right-sided petrositis.

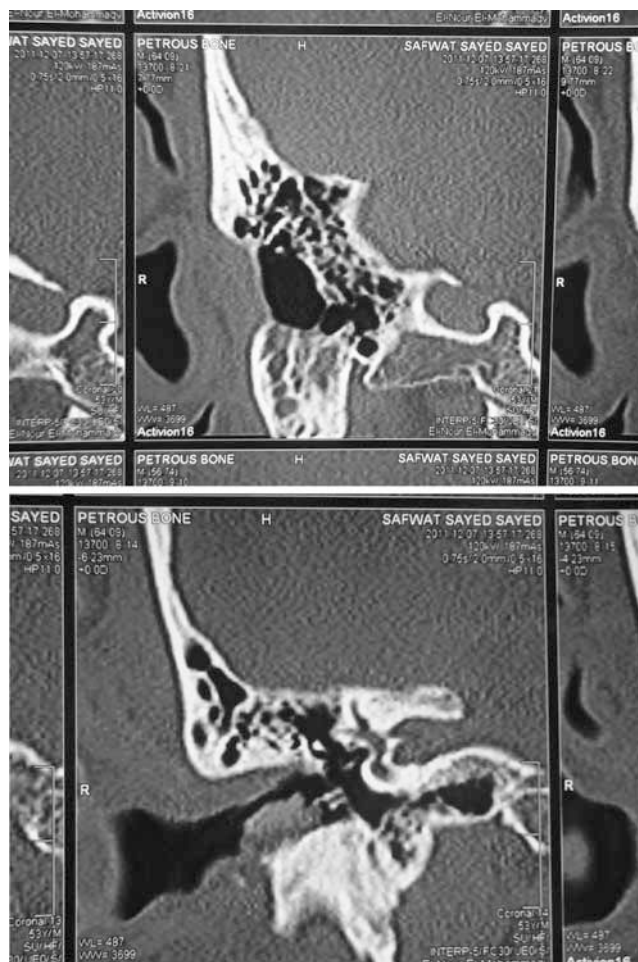
successfully treated using an infralabyrinthine approach with the preservation of both the middle and the inner ear after failure of aggressive medical treatment.

**Methodology and results**

This is a retrospective study carried out by collecting the data of five patients with Gradenigo’s syndrome who underwent surgical drainage carried out by the authors during the period from April 2009 till April 2011. The study was carried out at Ain Shams University Hospitals following institutional review board approval; the nature of the procedure was explained to the patients and an informed consent was signed before the operation.

The study included five patients ranging in age from 19 to 55 years, two women and three men. These five patients with clinical presentations indicating Gradenigo’s syndrome presented to our clinic with a history of ear discharge and deafness together with ear pain associated with visual problems. The discharge was purulent and profuse. Gradenigo’s syndrome was initially considered; full otorhinolaryngological examination and ophthalmological examination confirmed the diagnosis of otitis media

Figure 2



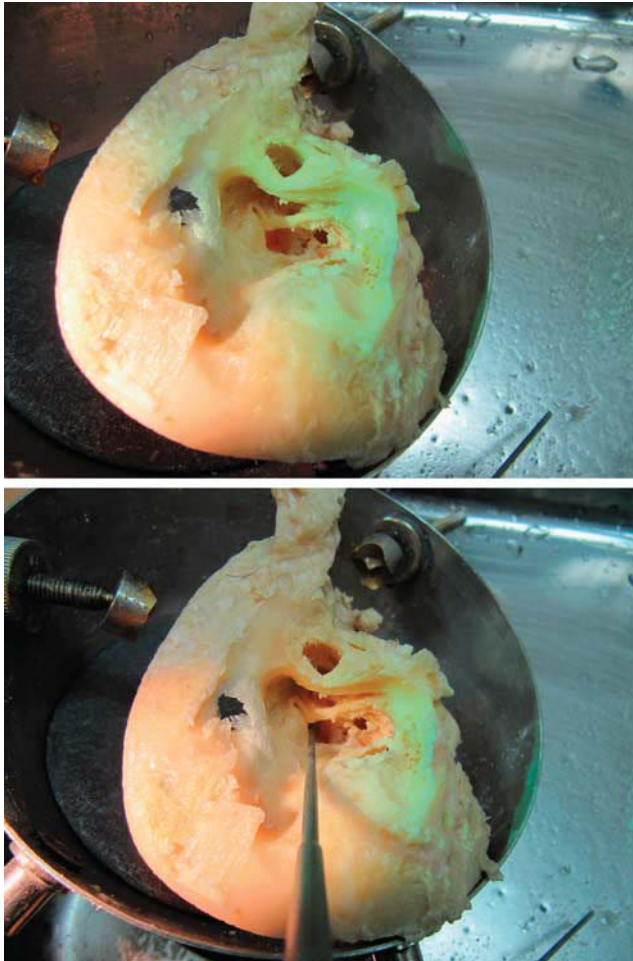
Coronal cuts showing the track to the petrous apex.

together with paralysis of lateral rectus muscle (abducent nerve palsy). This clinical diagnosis was confirmed by a high-resolution CT of their temporal bones, which showed the spread of the inflammatory process to the pneumatized petrous apex. After the failure of a short course of aggressive medical therapy for 48 h, our patients were scheduled for an emergency transmastoid infralabyrinthine approach.

The aim of this approach was to preserve the cochleoves-tibular function instead of the translabyrinthine approach as the five patients had variable degrees of pure conductive deafness without any evidence of labyrinthine deterioration of nerve function (Fig. 1).

Complete mastoidectomy was performed for all patients under general anesthesia for identification, without exposure of the sigmoid sinus jugular bulb, lateral, and posterior semicircular canals and blue lining of the posterior aspect of the mastoid segment of the facial nerve. Drilling was extended inferiorly and medially following the sigmoid sinus in order to expose the jugular bulb. These structures (mastoid segment of VII, posterior semicircular canal, and jugular bulb) corresponded to the anterior, superior, and inferior margins of our triangle,

Figure 3



Cadaveric dissection showing the borders of the infralabyrinthine approach.

where the mouth of the track led to the petrous apex. A fine bony curette was used to excentrate the air cells, creating a tract directed along the long axis of the petrous bone in the direction of the petrous apex (Figs. 2 and 3).

The air cells along the tract were stuffed with purulent exudates in three of our patients. Two of the five cases showed no excaudate at all, although the patients had the same clinical picture and showed the same improvement after surgery. Repeated irrigation with normal saline with suction of the purulent discharge was performed. Following the operation, all patients received ceftriaxone 1 g/24 h for 5 successive days together with diclofenac potassium 50 ml oral tablets every 12 h for 5 days. A postoperative CT scan carried out after surgery showed the successful infralabyrinthine path to the petrous apex. The mean follow-up period was 3 months (ranging from 1 to 6 months). All patients started showing an improvement immediately after surgery, with the disappearance of diplopia and the lateral rectus palsy being the first outcome to be noted.

In our series, only one patient developed mild vertigo and vomiting that lasted for 3 days, and was treated with

sedation and antiemetics. Otherwise, there were no intra-operative or postoperative complications such as facial nerve palsy or cerebrospinal fluid leak.

## Discussion

The petrous apex is anatomically defined as the portion of the temporal bone lying anteromedial to the inner ear, between the sphenoid bone anteriorly and the occipital bone posteriorly, with the extreme apex terminating at the foramen lacerum. Because the petrous apex is not amenable to direct clinical inspection, imaging studies are a valuable addition to the workup of petrous apex disease. Apical petrositis has been associated with severe and life-threatening complications, such as meningitis, brain abscess, lateral sinus thrombosis, or even cavernous sinus thrombosis, unless the area has been surgically decompressed and drained. Freckner described an approach through the superior semicircular canal. Meanwhile, Eagleton described a middle fossa approach, whereas Dearmin and Farrior described an approach between the posterior semicircular canal and the jugular bulb. These latter approaches attempted to preserve hearing [11].

The use of proper antibiotic treatment markedly changed the incidence of the disease and its dramatic course, but surgical drainage of the petrous apex was still needed in resistant cases. The technique that we adopted is much easier to perform and is applicable for all ages. Our aforementioned technique offers a safe and direct approach to the petrous apex, which maintains permanent pneumatization and drainage to the petrous apex with much less incidence of complications and an easier approach to decrease the operative time and to ensure preservation of the audio vestibular function of the targeted ear, and providing a better alternative to the older destructive approaches. However, our technique is not suitable for drainage of other petrous apex space-occupying lesions as it is not a straight approach and it is still narrow in comparison with the translabrynthine approach. The use of otoendoscopes may improve the visualization and add more advantages to the technique.

We recommend this approach as the second-line therapy in the management of apical petrositis after a trial of aggressive antibiotic and steroid therapy for no longer than 48 h.

## Conclusion

The infralabyrinthine approach is a safe and direct way to drain inflammatory exudates from the petrous apex but cannot provide an alternative approach to the translabrynthine one to exenterate a mass lesion in this area.

In our series, petrositis secondary to otitis media could be safely and effectively managed by draining the petrous apex using an infralabyrinthine approach with preservation of the middle and inner ear function.

The symptoms gradually disappear starting with the diplopia, which usually improves on the same day as the surgery.

---

## Acknowledgements

### Conflicts of interest

There are no conflicts of interest.

---

## References

- 1 Lempert J. Complete apicectomy (mastoidotympanoapicectomy), new technique for complete apical exenteration of apical carotid portion of petrous pyramid. *Arch Otolaryngol* 1937; 25:144–177.
- 2 Gradenigo G. Paralysis of abducent nerve due to otitis media. *Arch Ohrenheilk* 1907; 774:149–187.
- 3 Goldstein NA, Casselbrant ML, Bluestone CD, Kurs Lasky M. Intratemporal complications of acute otitis media in infants and children. *Otolaryngol Head Neck Surg* 1998; 119:444–454.
- 4 Al Ammar AY. Recurrent temporal petrositis. *J Laryngol Otol* 2001; 115:316–318.
- 5 Chole RA, Donald PJ. Petrous apicitis. Clinical considerations. *Ann Otol Rhinol Laryngol* 1983; 92 (6 l): 544–551.
- 6 Burston BJ, Pretorius PM, Ramsden JD. Gradenigo's syndrome: successful conservative treatment in adult and paediatric patients. *J Laryngol Otol* 2005; 119:325–329.
- 7 Gillanders DA. Gradenigo's syndrome revisited. *J Otolaryngol* 1983; 12:169–174.
- 8 Kepetzky SJ, Almour R. Suppuration of petrous pyramid: symptomatology, pathology and surgical treatment. *Ann Otol Rhinol Laryngol* 1931; 40: 396–414.
- 9 Ramadier J. Les ostéites profondes du rocher (Petrosite-Rochente). *Bull Loc Franc ORL* 1933; 46:1–18.
- 10 Murakami T, Tsubaki J, Tahara Y, Nagashima T. Gradenigo's syndrome: CT and MRI findings. *Pediatr Radiol* 1996; 26:684–685.
- 11 Minotti AM, Kountakis SE. Management of abducens palsy in patients with petrositis. *Ann Otol Rhinol Laryngol* 1999; 108 (9 l): 897–902.