

Endoscopic-assisted sublabial enucleation of nasolabial cysts

Tamer AboEl-Ezz

Department of Otorhinolaryngology, Ain Shams University Hospitals, Ain Shams University, Cairo, Egypt

Correspondence to Tamer AboEl-Ezz, MD, ENT Department, Ain Shams Abbasia, Cairo, Egypt
Tel: +20 121 038 969; fax: +00 224 312 775; e-mail: Tamerezz02@hotmail.com

Received 25 January 2012

Accepted 3 March 2012

The Egyptian Journal of Otolaryngology
2012, 28:85–88

Background

Nasolabial cysts are rare lesions present in the soft tissues beneath the ala nasi. Excision of the cyst through the sublabial incision is the most well-known treatment modality, with a low recurrence rate.

Objective

In this study, we discuss, through a literature review, the diagnosis, differential diagnosis, and a modified combined endoscopic and sublabial surgical technique for the treatment of this disorder.

Patients and methods

Ten patients with a confirmed diagnosis of nasolabial cysts underwent combined endoscopic and sublabial enucleation of the cysts, and were followed up with a clinical examination and endoscopic assessment.

Results

No recurrence was recorded during a follow-up period ranging from 3 to 12 months.

Conclusion

Nasolabial cysts can be enucleated with the use of a nasal endoscope to ensure complete excision.

Keywords:

endoscopic, nasolabial cysts, outcomes, recurrence, sublabial enucleation

Egypt J Otolaryngol 28:85–88
© 2012 The Egyptian Oto - Rhino - Laryngological Society
1012-5574

Introduction

Nasolabial cysts are rare lesions, whose incidence is 0.7% of all maxillofacial cysts [1]; it is present behind the ala nasi, extending backwards into the inferior nasal meatus and forward into the labiogingival sulcus. The pathogenesis of nasolabial cyst is unclear [2]; usually, the cysts are seen in the fourth to fifth decade of life but exposure to trauma accelerates its formation [3]. They are usually diagnosed early because of disfigurement and nasal obstruction; pain can occur if the cyst becomes infected [4].

There are different treatment modalities including sublabial surgical excision, injection of sclerosing materials into the cyst, or endoscopic marsupialization, with no standard surgical protocol for its excision [5].

Sublabial excision is the most well-known treatment modality for cosmetic reasons, with a low recurrence rate; in addition, transnasal marsupialization alone can be carried out successfully through nasal endoscopes [6].

Our objective was to present our experience in the diagnosis of 10 patients with sublabial cysts and to discuss our technique of combining both endoscopic and sublabial incision to treat them.

Ethical considerations

An informed consent was signed by all patients or their legal representatives before surgery; this informed consent was set by the authorities in Ain Shams University

Hospitals and included all the information and regulations that the patients needed to be aware of in terms of their rights and any possible complications.

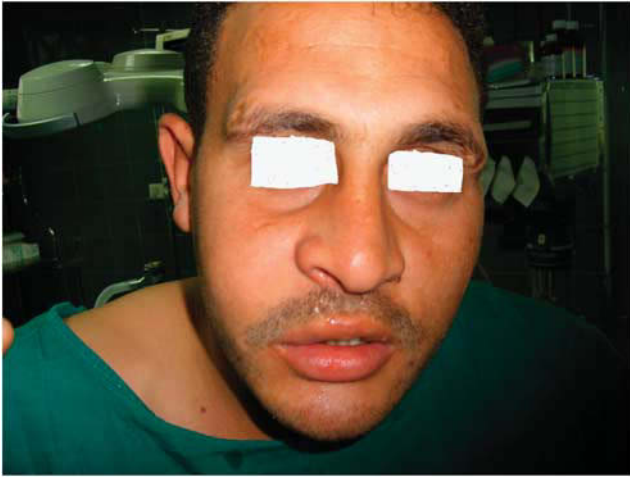Study design

Prospective study on 10 patients with a confirmed diagnosis of nasolabial cysts.

Patients and methods

Our study was carried out in the period from January 2009 to September 2010, at the Department of Otolaryngology-Head and Neck Surgery, Ain Shams University (Cairo, Egypt). A total of 10 cases of nasolabial cysts were studied. Each patient was subjected to a detailed history taking, including the main presenting symptoms and its duration, a thorough clinical examination to determine the size and location of cysts, followed by a radiological examination by computed tomography (CT). All patients (Figs 1 and 2) were prepared for surgical excision under general anesthesia through a sublabial approach assisted by a rigid nasal endoscope 30° both sublabially and transnasally to dissect and excise the entire lining of the cyst with the removal of the entire bony wall between the cyst and the nasal cavity to ensure wide drainage and ventilation of the cavity to prevent recurrence; introduction of the scope from the nasal side of the cyst ensured wide communication between the cyst cavity and the nasal fossa (i.e. endoscopic-assisted enucleation) (Figs 3 and 4).

Figure 1



The most common presenting symptom was painless facial swelling.

Postoperatively, all patients received an injection of ceftriaxon 1 g every 24 h for 5 days along with diclofenac sodium 50 mg as an analgesic and anti-inflammatory, in addition to saline nasal douches three times daily.

Histopathological examination of the excised cyst walls was carried out for a definitive diagnosis. All patients were monitored through outpatient clinic visits with clinical examination and a follow-up endoscopic evaluation; the duration of follow-up ranged from 3 to 12 months.

Results

Out of 10 patients, five (50%) were women and five (50%) were men, aged from 17 to 53 years (35 ± 1 years). The most common presenting symptom was a facial swelling in the nasolabial region, followed by nasal obstruction and pain. The interval between the onset of symptoms and the first visit to the ENT clinic ranged from 1 month to 3 years (mean 9 ± 0.5 months).

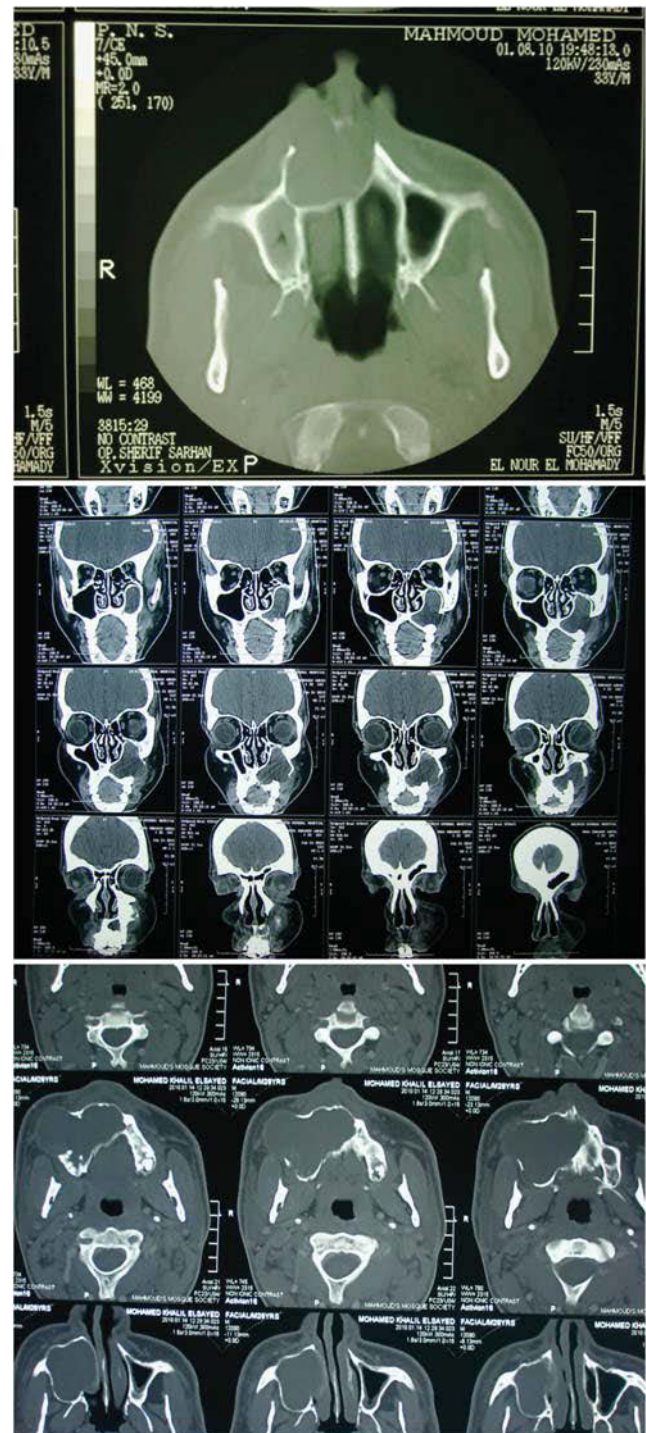
Radiological assessment showed that the size of the cysts ranged from 1 to 5 cm (mean 3.7 ± 0.2 cm). They were located on the left side in six patients and on the right side in three patients and one bilateral but right side was much larger.

During the follow-up visits, the endoscopic examination showed the opening, which was smoothly healed in all cases within 1 month, with no evidence of recurrence in any patient during the follow-up period of 3 to 12 months (mean 5.5 ± 0.3 months).

Histopathological examination of all cases showed pseudo-stratified columnar epithelium-lined cysts with no evidence of neoplastic changes.

One of our patients was a 35-year-old man with bilateral nasolabial cysts. After many years of misdiagnosis, he was finally referred to our clinic with a right-sided facial swelling of unknown origin. CT scan showed two cysts,

Figure 2



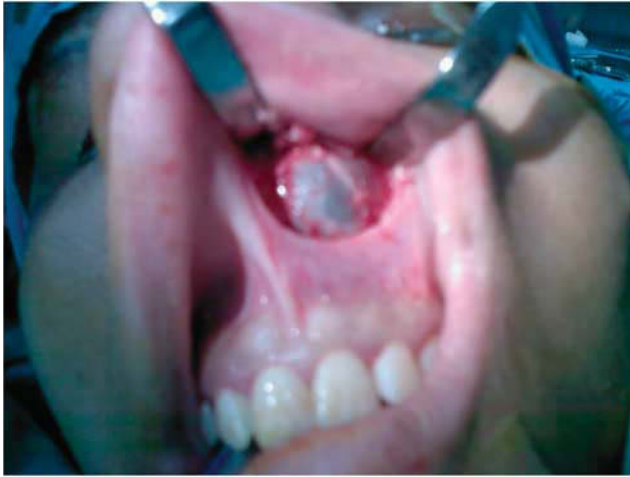Different extensions of nasolabial cysts.

with the right one being much larger than the left. Both cysts were enucleated during the same session (Fig. 5).

Discussion

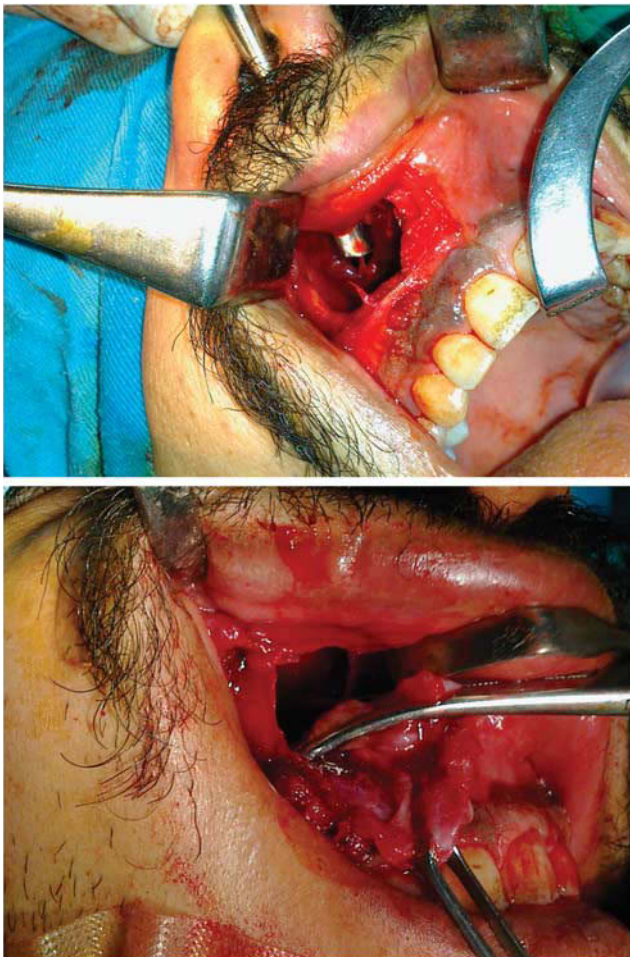
Nasolabial cysts are quite rare; they are usually unilateral and represent $\sim 0.7\%$ of all maxillofacial cysts [7]. Bilateral cysts are even rarer ($\sim 10\%$) [8]. In our case series, we found only one bilateral case over the last few years (10%) of the total number of our cases.

Figure 3



Sublabial exposure.

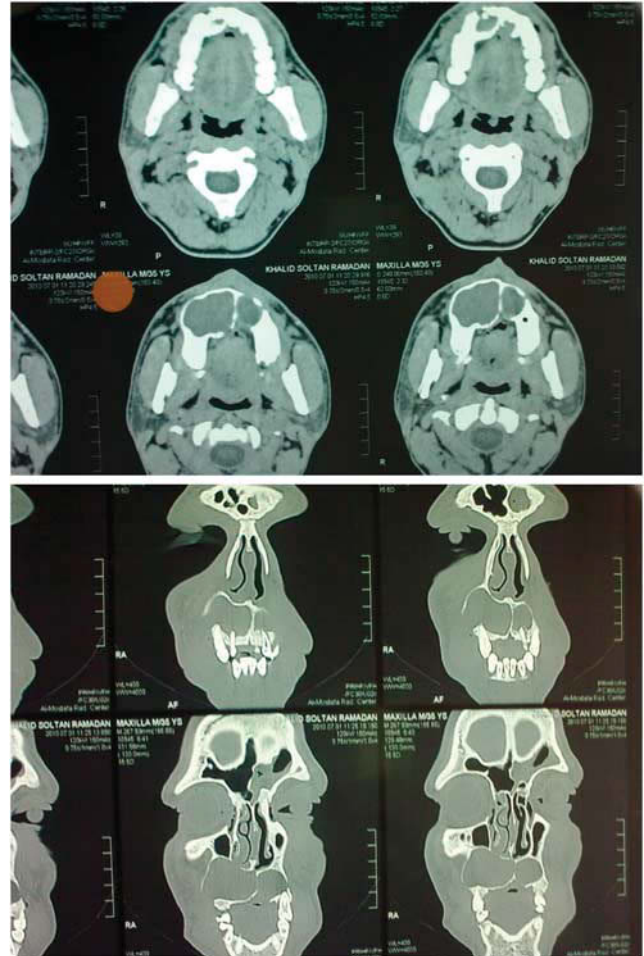
Figure 4



Wide communication to the nasal cavity with the removal of the cyst lining.

Some authors suggest that it might be a more common phenomenon, especially among certain ethnic groups [9]. They are usually asymptomatic lesions, and because of their rarity, they are often misdiagnosed and not treated

Figure 5



Bilateral nasolabial cysts in a 35-year-old man.

properly. The demographic data in this study correspond well with those in the previous literature; that is, 50% of the patients were women and 50% were men [10].

The vast majority of our patients presented with a history of a swelling or fullness in the nasolabial region; the swelling was soft, movable, pale, round, and localized. Its submucosal location at the anterior nasal floor is characteristic and was described by Bull *et al.* [11] as almost pathognomonic. Despite the fact that it is usually asymptomatic, it can sometimes produce a sensation of pressure or discomfort and, when infected, may even cause pain [10]. In advanced cases, when the cyst has enlarged and encroached upon the nasal cavity, the main complaint is unilateral nasal obstruction. The variation in size could be explained by the observation that it can spontaneously drain into the nose or the mouth, especially when it is infected, in ~50% of cases [9,12].

The gold standard investigation is the CT scan of the paranasal sinus along both axial and coronal cuts. In most cases, a CT will help establish the diagnosis and determine the size of the cyst [13]. In our series, it was necessary to confirm the diagnosis and to differentiate it from other dental and palatal cysts in this region and

determine the size of the cyst; however, a conclusive diagnosis can only be achieved through a histological examination. CT scan was performed in all patients, and a well-outlined cystic lesion with bone remodeling was found in some cases (mostly with huge cysts).

The most relevant differential diagnosis is a dental abscess from the canine space, which can easily be excluded by vitality testing of the affected tooth [14,15]. Other possible differential diagnoses include sebaceous cysts or implanted epidermal inclusion cysts, which resemble the nasolabial cyst clinically and histologically [11].

Several treatment modalities have been described for the management of this lesion, including sublabial surgical excision, endoscopic marsupialization, aspiration, incision and drainage, and injection of sclerotic agents [9]. Except for complete surgical excision and endoscopic marsupialization, all other treatments are associated in the literature with a high recurrence rate. Many reports have described endoscopic marsupialization to be a simple and effective alternative. It has been shown that after successful marsupialization, the nasolabial cyst is converted into an air-containing paranasal sinus [16].

Although we did not find any article on the use of a microscope in our literature review, it is clear that it would facilitate precise excision of the lining mucosa with better magnification and illumination.

Therefore, we performed complete surgical excision using a sublabial approach using a 30° angled nasal endoscope to completely excise the lining mucosa of the cyst cavity and to establish a wide communication between the cyst and the nasal cavity; this technique was adopted to combine the benefits of both wide exposure of the cyst without a visible facial scar and the meticulous extirpation of all the lining mucosa of the cyst wall, and to convert the bony cavity that results after removal of the cyst lining into a well-drained pouch after removal of the wall between it and the nasal cavity. The angulations of the scope offer a wider view of the entire cavity and allow its inspection from the nasal side. We did not attempt to differentiate between the nasal mucosa and the cyst mucosa as both were removed with the bony partition between the nasal fosse and the cyst cavity. During the follow-up visits, it was quite easy to inspect the opening of the cavity by introducing the office endoscope without local anesthesia in most of the cases. Only a light hypoesthesia was evident in the right upper lip. It has been shown that after successful enucleation, the nasolabial cyst is converted into an air-containing nasal sinus, with no recurrence in our 10-case series.

All symptoms completely disappeared in our patients, with no evidence of recurrence during a mean follow-up of ~6 months, which was attributed to the complete surgical excision with a wide communication between the cyst cavity and the nasal cavity.

Conclusion

A complete surgical excision is recommended using a sublabial approach with the use of a 30° endoscope to completely excise the lining mucosa of the cyst cavity and to establish a wide communication between the cyst cavity and the nasal cavity.

Acknowledgements

Conflicts of interest

There are no conflicts of interest.

References

- Patil K, Mahima VG, Divya A. Klestadt's cyst: a rarity. *Indian J Dent Res* 2007; 18:23–26.
- Roed Petersen B. Nasolabial cysts. A presentation of five patients with a review of the literature. *Br J Oral Surg* 1969; 7:84–95.
- Klestadt W. Nasolabial cyst: presentation of five case with a review of the literature 1913; 50:1683–1685.
- Bruggemann A. Nasolabial cyst management. *Arch Laryngol Rhinol* 1920; 33:01–05.
- Wesley RK, Scannell T, Nathan LE. Nasolabial cyst: presentation of a case with a review of the literature. *J Oral Maxillofac Surg* 1984; 42: 188–192.
- Zahirrudin Z, Gendeh B, Tan G, Marina M. Nasolabial cyst: presentation and management. *Internet J Otorhinolaryngol* 2009; 9:2.
- Jin HC, Jae HC, Hee JK, Sung WC, Sang HL, Soon JH, et al. Nasolabial cyst: a retrospective analysis of 18 cases. *Ear Nose Throat J* 2002; 81: 94–96.
- Vasconcelos RF, Alencar Souza PE, Mesquita RA. Retrospective analysis of 15 cases of nasolabial cyst. *Quintessence Int* 1999; 30:629–632.
- Yuen HW, Julian CYL, Samuel CLY. Nasolabial cysts: clinical features, diagnosis and treatment. *Br J Oral Maxillofac Surg* 2007; 45:293–297.
- Holtmann S, Martin F, Permanetter W. Dysontogenetic median maxillary cysts. *Laryngol Rhinol Otol (Stuttg)* 1985; 64:331–334.
- Bull TR, McNeill KA, Milner G, Murray SM. Naso-alveolar cysts. *J Laryngol Otol* 1967; 81:37–44.
- Kuriloff DB. The nasolabial cyst-nasal hamartoma. *Otolaryngol Head Neck Surg* 1987; 96:268–272.
- Talpos S, Urtila F, Valeanu A. Giant maxillary sinus cyst with nasal fossae, ethmoid, frontal sinus and orbital extension. *J Craniomaxillofac Surg* 2006; 34:121.
- Zimmer WM, Rogers RS, III, Reeve CM, Sheridan PJ. Orofacial manifestations of Melkersson-Rosenthal syndrome. A study of 42 patients and review of 220 cases from the literature. *Oral Surg Oral Med Oral Pathol* 1992; 74:610–619.
- Mylonas AI, Tzerbos FH, Mihalaki M, Rologis D, Boutsikakis I. Cerebral abscess of odontogenic origin. Based on a paper presented at the 5th European Congress of Oto-Rhino-Laryngology Head and Neck Surgery, 11-16 September 2004, Rodos-Kos, Hellas. *J Craniomaxillofac Surg* 2007; 35: 63–67.
- Su CY, Huang HT, Liu HY, Huang CC, Chien CY. Scanning electron microscopic study of the nasolabial cyst: its clinical and embryological implications. *Laryngoscope* 2006; 116:307–311.