

Septorhinoplasty for the Arabic nose: simple endonasal techniques

Mamdouh Salah A. Mottaleb^a and Baher Badreldin Ashour^b

^aDepartment of Plastic Surgery Unit, Mataria Teaching Hospital, and ^bDepartment of ENT, Cairo University, Cairo, Egypt

Correspondence to Baher Badreldin Ashour, Department of ENT, Cairo University, Cairo, Egypt
e-mail: drbaherashour@elajgroup.ae.

Received 23 January 2012
Accepted 12 February 2012

The Egyptian Journal of Otolaryngology
2012, 28:98–103

Introduction

Individuals from the Middle East or of Middle Eastern origins are increasingly seeking cosmetic nasal surgery as their traditional societies gradually become more exposed to the media. This is especially evident in the tribal communities of the Gulf, where financial issues are less of a concern. The Gulf States have also witnessed a rapid influx of foreign migrants over the last 30 years or so. This has resulted in a more racially and ethnically diverse population. The concept of ethnic rhinoplasty is gaining popularity. This entails resculpturing the nose to make it more acceptable within the patient's own ethnicity and not to overcorrect or alter its characteristics to that of another ethnicity. The characteristic features of the Arabic nose, when exaggerated, are a good example where ethnic rhinoplasty techniques may be of value.

Aim

The aim of this study was to identify patients with exaggerated features of the characteristic Arabic nose, which are a long nose with a dorsal hump and a pendant tip. Subjective as well as objective measures including the clinical nasal index and the projection index were used to identify and quantify these anomalies. We will review some simple endonasal techniques for the correction of these perceived abnormalities for the best cosmetic as well as functional results.

Patients and methods

Sixty four patients with typical Arabic nasal features underwent septorhinoplasty using simple endonasal techniques.

Results

The majority of patients were very satisfied with their appearance after surgery. There were few minor complications with the techniques used.

Conclusion

Exaggerated features of the Arabic nose can be adequately corrected using a few simple endonasal techniques.

Keywords:

Arabic nose, ethnic rhinoplasty, rhinoplasty

Egypt J Otolaryngol 28:98–103
© 2012 The Egyptian Oto - Rhino - Laryngological Society
1012-5574

Introduction

The Caucasian race is basically a way of defining people of European origin. Strictly speaking, the term can extend to groups from North Africa, the Middle East and areas of South and Central Asia. In essence, Caucasians are known as the 'white' race.

The German scientist and classical anthropologist Johann Friedrich Blumenbach proposed the concept of a Caucasian race around 1800. He wrote:

'I have taken the name of this variety from Mount Caucasus, both because its neighborhood, and especially its southern slope, produces the most beautiful race of men, I mean the Georgian; and because all physiological reasons converge to this, that in that region, if anywhere, it seems we ought with the greatest probability to place the autochthones (birth place) of mankind'.

However, Da Vinci was one of the first anatomists to define the nasal proportions. He divided the face into three equal horizontal sections, the nose occupying the middle third. It must be mentioned that this was a western renaissance view of beauty and over the ages and within different cultures, this has not been a static perception.

Nowadays, it is established that race and ethnicity have no scientific or anthropologic validity. We must reconsider our use of anthropometric measurements in nasal plastic surgery [1–3].

Irrespective of their origin or descent, the different types of noses will always be unique to the person and can only really be defined by their characteristics.

Whether a less pronounced anomaly is to be considered an abnormality or a variation may be more difficult to decide. This is often a matter of taste. We should keep in mind that several of the variations to be described are

race-dependent to a certain extent and therefore have to be considered as normal ethnic variations of the human nose [1].

The Middle Eastern face and nose are very different from the Caucasian one. The rhinoplasty surgeon should be aware of this and should attempt to preserve some ethnic character when performing the operation.

A recently deceased mega pop star represents proof of this kind of transformation. However, the patient's wishes and desires must always be kept in mind. It is known that it is the patient who decides whether the nose is abnormal or not. Although understandable, this way of thinking may also be dangerous. It is necessary to warn against surgery that is intended to make a normal nose look more beautiful.

The typical Caucasian nose is described as leptorrhine, meaning long and narrow. It has been theorized that life in colder parts of the planet has led to Caucasians adapting to cold and sun-deprived conditions, leading to their characteristic nasal configuration. The most common problem faced by Caucasians is a larger-sized nose. This makes procedures relatively simpler than working on other ethnic groups where enhancement, narrowing and inserts are required.

The Middle Eastern or Arabic nose is characterized by being long, slightly humped and having a pendant tip with a small nasolabial angle and occasionally a hanging columella [2]. The tip is more caudal than normal and occasionally underprojected at the same time.

It has been proposed that these characteristics are due to genetic, endocrine as well as environmental factors. Dusty hot climates especially in the Gulf region lead to an increased incidence of allergic rhinitis. In an attempt to widen the internal nasal valve, excessive use of the lower nasal muscles especially during development may lead to the above-mentioned characteristic features.

The Arabic nose is often of little concern to men unless the features are markedly exaggerated. In women, it poses more of a problem and may cause psychological disturbances among teenagers.

Psychological counselling is very important in many cases. The patient must have a clear understanding of what the surgery entails and realistic expectations. It may be very helpful to show the patient 'before and after' pictures of other patients with similar appearances. The importance of obtaining informed consent cannot be over-emphasized.

Keeping in mind the vast variations in nasal shape and conceptions regarding beauty, the characteristics of the Arabic nose can generally be corrected by simple endonasal techniques.

To achieve the best possible results and patient satisfaction, both functional and aesthetic aspects of nasal surgery should be kept in mind.

Patients and methods

This study included 64 patients operated upon between 2002 and 2008, with an average follow-up period of 2 years. All patients were of Middle Eastern ethnicity and the male to female ratio was 1:3. The ages ranged from 18 to 37 years, with a mean age of 27 years.

Only patients who had the characteristic Arabic nasal features were included. Those with a twisted nose due to trauma were excluded because in these patients, the complaint is deviation and not an exaggerated Arabic nasal configuration. We avoided operating on patients with excessively thick seborrhoeic skin due to excessive postoperative swelling, scarring and poor cosmetic results.

We used a digital caliper to measure the clinical nasal index and the projection index before surgery. These indices are useful to determine how much nasal length or hump resection is required. In general, patients with a clinical nasal index below 55% have excessively long noses, whereas a projection index above 65% represents a significant nasal hump. During the last preoperative counselling session, photographs were taken. These are useful for the comparison of preoperative and postoperative results, to avoid litigation and for research purposes. Because of religious and cultural beliefs in the Middle East, photographs, especially those of women, are particularly difficult to obtain. Preoperative routine labs were requested with a focus on the coagulation profile.

All procedures were carried out under general anaesthesia with prophylactic antibiotic coverage in the form of a single intravenous injection of 1g ceftriaxone during induction. Hypotensive anaesthesia was not encouraged. No local vasoconstriction or local anaesthesia was injected as we found that it did not help significantly reduce intraoperative bleeding as well as to avoid the rebound bleeding that may occur occasionally after vasoconstriction. Postoperative pain was managed easily with parenteral and oral nonsteroidal anti-inflammatory agents. 4-0 Vicryl (Vicryl, Ethicon Inc., Somerville, New Jersey, USA) was used for all intranasal sutures.

Before beginning the rhinoplasty procedure, any other intranasal problems were addressed. A symptomatic markedly deviated nasal septum was found in 12 cases and was corrected using standard septoplasty techniques. It is important to note that the nasal septum is the main cause of functional complaints as well as many aesthetic problems. Therefore, the nasal septum must be addressed first and adequately mobilized for successful rhinoplasty. Any excised cartilage was preserved in saline. Although preserved cartilage is an excellent material for use as grafts and struts, its use has declined due to fears of prion transmission.

Enlarged allergic inferior turbinates were found in five cases and were reduced using submucosal coblation turbinoplasty.

Silastic nasal septal splints were used in all cases and a 6mm Meroceol (Meroceol, Medtronic, Minneapolis, Minnesota, USA) tampon was inserted into both nasal

cavities. The tampon was removed the next day, whereas the silastic splint was left in place for 1 week. Externally, an aluminium dorsal nasal splint was used to support and protect the bony pyramid and was left in place for 7 to 10 days.

Common problems encountered in the Arabic nose and management techniques

Long nose

In certain cases, the nose may appear longer than normal in relation to the face. This may be due to a hanging columella, a depressed tip, a large dorsal hump or obliteration of the frontonasal angle.

Excision of a wedge from the caudal part of the septum will correct the depressed tip along with the hanging columella, resulting in a shorter appearance of the nose. This wedge is in the form of a triangle with the apex directed inferiorly and the base directed anteriorly (Fig. 1). The length of the base correlates with the intended degree of shortening required. Cartilage should be measured and excised precisely to avoid columellar show, which is unacceptable to the patient. A small piece of septal mucosa of the same shape is removed from the upper edge of the transfixion incision on both sides to elevate a hanging columella. This helps to shorten the nose, decrease columellar show, open the nasolabial angle and allow cephalad rotation and correction of a plunging nasal tip (Fig. 2). Rasping is usually sufficient to correct an obliterated frontonasal angle.

An important point is to avoid connecting transfixion and intercartilagenous incisions to avoid jeopardizing the blood supply of the nasal tip.

Hanging (pendant, drooping) tip

A pendant low tip is also a standard feature of the long, slightly humped Arabic nose. The tip is more caudal than normal and underprojected at the same time. The nasolabial angle is abnormally small. A pendant tip is often seen in elderly individuals, combined with a long nose.

If the previous measures were not sufficient to correct a depressed tip, occasionally, we managed this problem by inserting a cartilaginous strut harvested from the septum or the helix (Fig. 3). In cases with a broad tip, a domal suture was performed to elevate and narrow it.

Dorsal hump

A mild hump was simply rasped ensuring preservation of the roof of the nasal pyramid (Fig. 4). In more severe cases, osteotomies were performed to prevent open roof deformities. Cartilage grafts are very useful to camouflage irregularities of the dorsum.

In most cases, a combination of the above techniques was required to achieve the desired result.

The intranasal Merocel pack was removed on the first postoperative day immediately before discharging the patient from hospital. The external nasal splint was changed on the second postoperative day in order to

check for any nasal deflections or deviations. The new splint was then removed a week later.

Oral acetaminophen was prescribed for postoperative pain, and swelling and bruising were managed with warm and cold compresses. The use of gauze-wrapped tea bags as warm compresses is particularly helpful to reduce postoperative swelling owing to the astringent properties of tannic acid.

The complications encountered were uncommon and minor; bleeding was controlled by nasal packing and rarely bipolar cautery. No postoperative infections or adhesions were noted. One patient had a small asymptomatic septal perforation due to the excessive use of diathermy to control troublesome bleeding from Little's area.

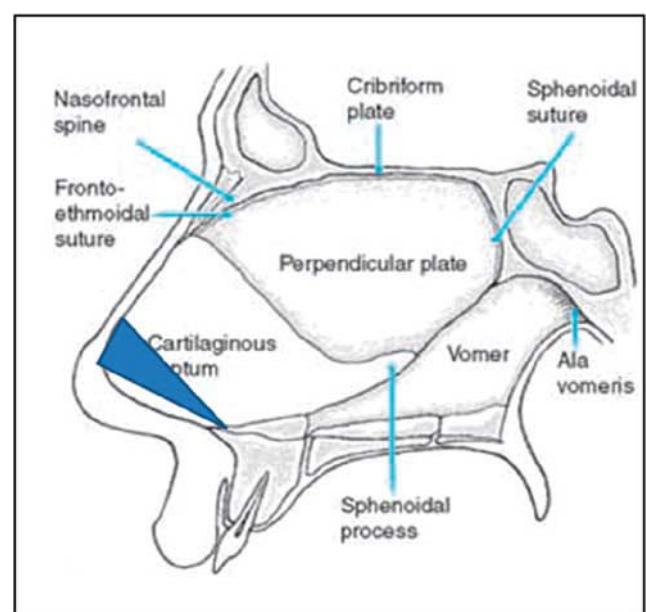
Results

The majority of patients were satisfied with the balanced natural look of the nose and absence of the operated look or any postrhinoplasty stigmata such as polybeak deformity, saddle nose, pinched or pig-like appearance.

A difference between the preoperative and the postoperative appearance was appreciated and the identity of the Arabic nose was preserved (Figures 5 and 6).

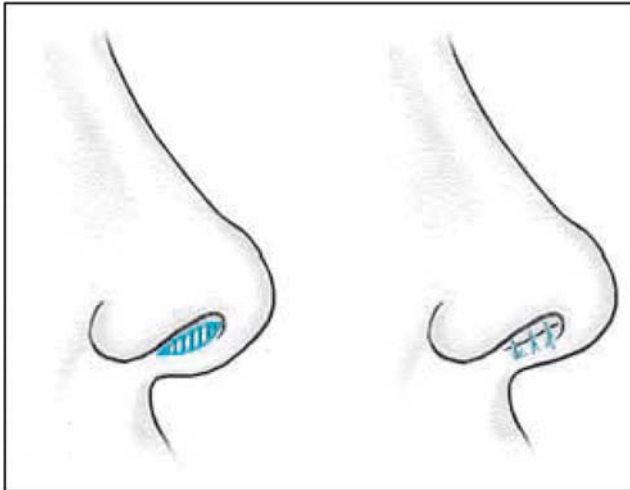
Five patients were not satisfied with the postoperative results and refinement surgery was carried out 3–6 months later. These patients complained of inadequate tip projection, inadequate reduction of length or an excessively broad nose. The same techniques mentioned above were used to help improve the appearance.

Figure 1



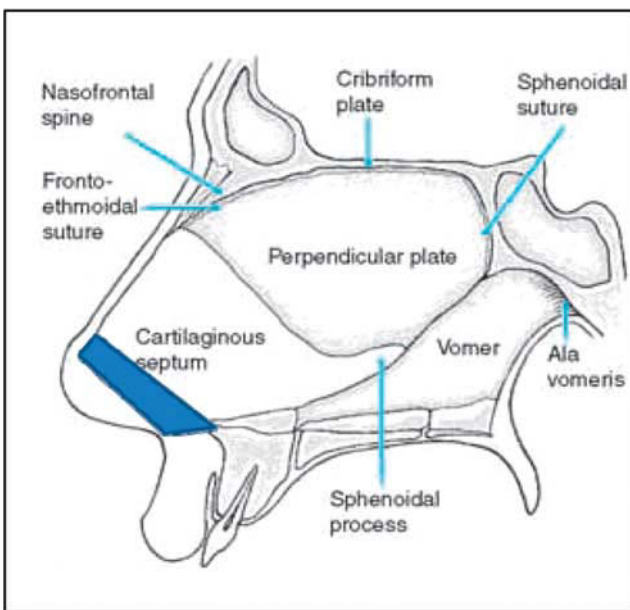
Wedge resection of the caudal septum.

Figure 2



Excision of septal mucosa.

Figure 3

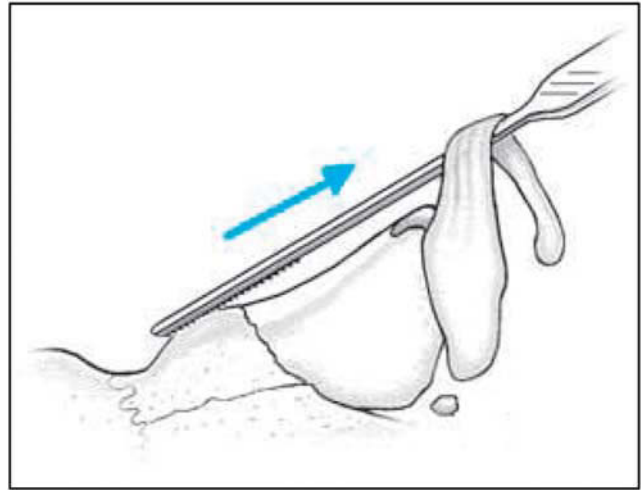


Columellar strut.

Discussion

Certain standard features characterize the Arabic or the Middle Eastern nose. In most cases, these features can easily be corrected by a few simple endonasal procedures. The principle of ethnic rhinoplasty is to correct perceived abnormalities without altering the ethnicity of the nose. The traditional European view of the perfect nose with a slender dorsum and a slightly upturned tip would only look peculiar on a clearly Arabic face. It is vital to be flexible and not to adhere strictly to the known standards of what is considered the perfect nose in the traditional literature. This balance can only be achieved with practice and by resisting the tendency to overcorrect.

Figure 4



Rasping of Dorsal Hump.

Religious implications and sensitivities regarding rhinoplasty must be respected in the Middle East, especially with Muslim patients. Many Muslims believe that aesthetic surgery of the face and rhinoplasty in particular is against their religious beliefs. It is therefore essential not to produce a radical change in appearance and identity but only to reduce exaggerated features such as a dorsal hump, a hooked tip or an excessively long nose.

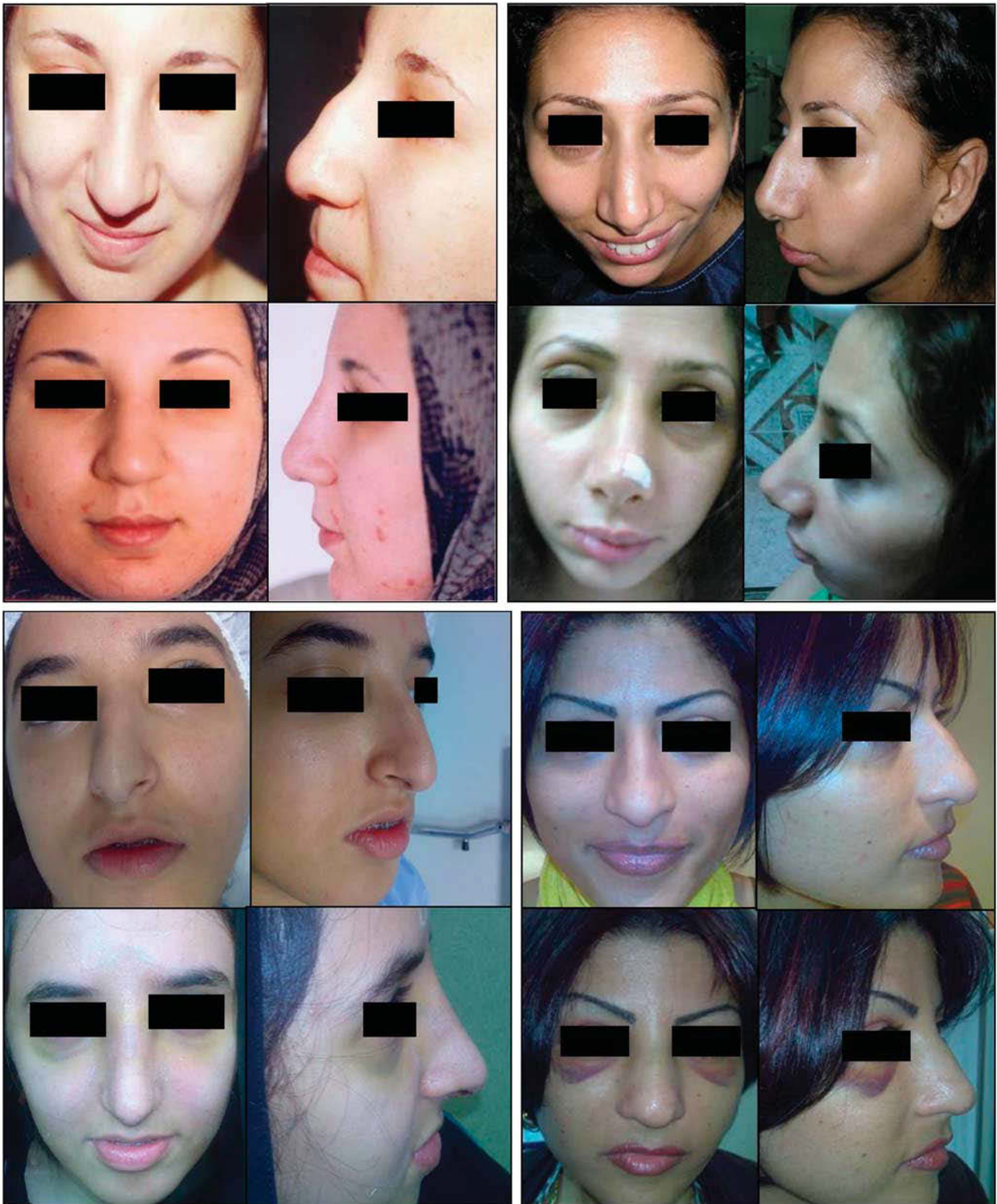
Preoperative counselling is vital to provide the patient with sufficient information regarding the procedure and its possible complications. The patient's expectations as well as psychological status should be carefully gauged during this period. Always strive to fulfill the patient's criteria, not your own. Each patient's wishes should be interpreted and respected carefully. It is also important to inform the patient about the average period of convalescence and when packs and casts will be removed. The final results of rhinoplasty should not be appraised before a few months postoperatively.

We found the open approach to be unnecessary in these patients. As many patients in our series had thick, pigmented skin, complications such as a visible scar and keloid formation were thus avoided with the use of the endonasal approach. Technically, a tailored approach for each patient should be used, avoiding excessive rigidity. The final aim should be a satisfied patient and not necessarily a beautiful nose. This makes ethnic rhinoplasty a true challenge that requires the plastic surgeon to have analytical capabilities, logic, manual skills and aesthetic sensitivity [4]. The aim and the ultimate challenge of rhinoplasty on Arab patients is to achieve balanced aesthetic refinement, while avoiding surgical westernization [5].

The authors' findings with regard to the surgical techniques correspond to those of Daniel [6] who stated the following critical techniques:

- Reduce the specific component of the dorsal deformity.
- Use a balanced approach of augmentation and reduction.

Figure 5

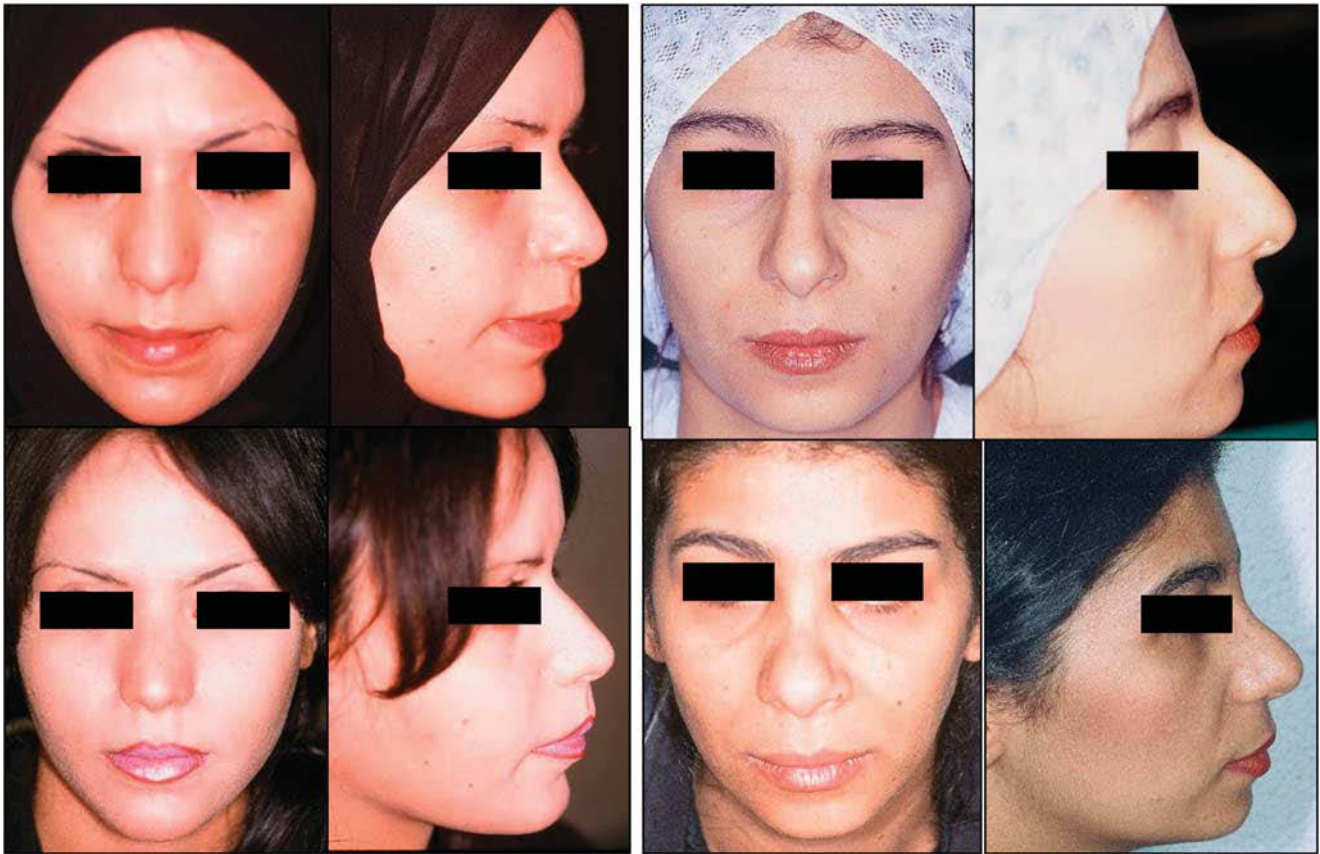

Preoperative (above) and postoperative (below) results.

The nasal surgeon should be aware of the limits of surgery. If a person's nose is considered 'normal' with respect to their ethnic origin, sex and age, changing its features may run counter to medical ethics.

The primary objective of nasal surgery must be to restore function. The aim of functional improvement must always be given priority over that of enhancing beauty [7].

Figure 6



Preoperative (above) and postoperative (below) results.

A final point is our strong support of close cooperation between the plastic and ENT surgeons during septorhinoplasty. This is especially important in patients who also complain of intranasal symptoms. Thus, both aesthetic and functional problems can be dealt with a single anaesthetic administration. This reduces risks to the patient as well as costs of surgery. This combined expertise will yield the best possible outcome for the patient.

Acknowledgements

Conflicts of interest

There are no conflicts of interest.

References

- 1 Rohrich RJ, Bolden K. Ethnic rhinoplasty. *Clin Plast Surg* 2010; 37: 353–370.
- 2 Boccieri A. The surgical approach to the mediterranean nose. *Fac Plast Surg* 2010; 26:119–130.
- 3 Leong SC, Eccles R. Race and ethnicity in nasal plastic surgery: a need for science. *Fac Plast Surg* 2010; 26:63–68.
- 4 Palma P, Bignami M, Delù G, De Bernardi F, Castelnuovo P. Rhinoplasty for the Mediterranean nose. *Fac Plast Surg* 2003; 19:279–294.
- 5 Azizzadeh B, Mashkevich G. Middle Eastern rhinoplasty. *Fac Plast Surg Clin North Am* 2010; 18:201–206.
- 6 Daniel RK. Middle Eastern rhinoplasty: anatomy, aesthetics and surgical planning. *Fac Plast Surg* 2010; 26:110–118.
- 7 Huizing B, de Groot J. *Functional reconstructive nasal surgery*. 1st ed. Stuttgart, Germany: Thieme; 2003.