

Bronchoscopy for foreign body removal: how I do it

Aly Gamal Zohny^{a,b} and Saud M. AlAjmi^b

^aDepartment of Otorhinolaryngology, Ain Shams University, Cairo, Egypt and ^bENT Unit, Ahmadi Hospital, Ahmadi, Kuwait

Correspondence to Aly Gamal Zohny, MD, ENT Unit, PO Box 9758, Ahmadi 61008, Kuwait
Tel: +965 238 62425; fax: +965 239 87362;
e-mail: alyzohny@hotmail.com

Received 4 February 2012

Accepted 5 February 2012

Egypt J Otolaryngol 28:149–155
© 2012 The Egyptian Oto - Rhino - Laryngological Society
1012-5574

Introduction

Proper supervised training and advances in equipment have made bronchoscopy a relatively safe procedure.

Execution of a safe and successful procedure starts with proper diagnosis. A history of aspiration may be lacking, and patients may present days to weeks after the event. A positive history must never be ignored, whereas a negative history may be misleading. Persistence of pneumonia or atelectasis symptoms beyond 1 week raises the possibility of a retained foreign body. Plain radiographs of anteroposterior and lateral projections including that of the anteroposterior neck in full inspiration and expiration are taken.

Obtaining two views of the foreign body helps to determine its location and excludes the presence of superimposed multiple foreign bodies. Left and right lateral decubitus positions in infants are considered because of difficulty in obtaining expiratory and inspiratory films. In decubitus films, the dependent lung should collapse but will remain inflated if there is a foreign body. Radiopaque foreign bodies are easily seen on a radiograph. Radiolucent foreign bodies (80%) may cause obliteration of the bronchial air column, atelectasis, mediastinal shifts, or air trapping in the affected lung. The lung may show signs of a subglottic opacity or swelling from airway inflammation on posteroanterior and lateral neck radiographs. Hence, radiographic findings in cases of suspected foreign body aspiration include the following (Figs 1–13):

- (1) normal findings (25%);
- (2) signs of air trapping (Fig. 1);
- (3) mediastinal shift;
- (4) atelectasis;
- (5) pneumonia (acute or recurrent);
- (6) lobar collapse; and
- (7) radiopaque foreign body.

Differences exist in radiological findings between adults and children. In adults, lobar or segmental collapse may occur, and atelectasis or consolidation is often not detected for at least 24 h. Children commonly present with overaeration of the lung distal to the site of obstruction because of collateral air drift.

If foreign body aspiration is suspected, a diagnosis is not overruled even on a normal-appearing chest radiograph.

Foreign bodies that obstruct mainly on expiration generate a check-valve effect, resulting in hyperinflation of the affected side and mediastinal shift to the opposite side. This is a typical early finding.

A ball-valve effect is produced later when foreign bodies obstruct on inspiration and disengage on expiration, producing atelectasis on the affected side and a mediastinal shift toward the affected side. When the object completely obstructs the bronchus, a stop-valve effect occurs, leading to consolidation of the lobe involved.

Computed tomography scan of the chest is resorted to in atypical cases but not as a routine.

The procedure of rigid bronchoscopy for foreign body removal is as follows.

Rigid bronchoscopy is not attempted as a direct emergency technique unless there is total airway obstruction at any level. Usually this occurs if obstruction is at a high level but may also occur with the rare situation of having double bronchial foreign bodies.

Another emergency situation is the inhalation of a small alkaline battery that may cause severe tissue reaction and has to be removed as early as possible.

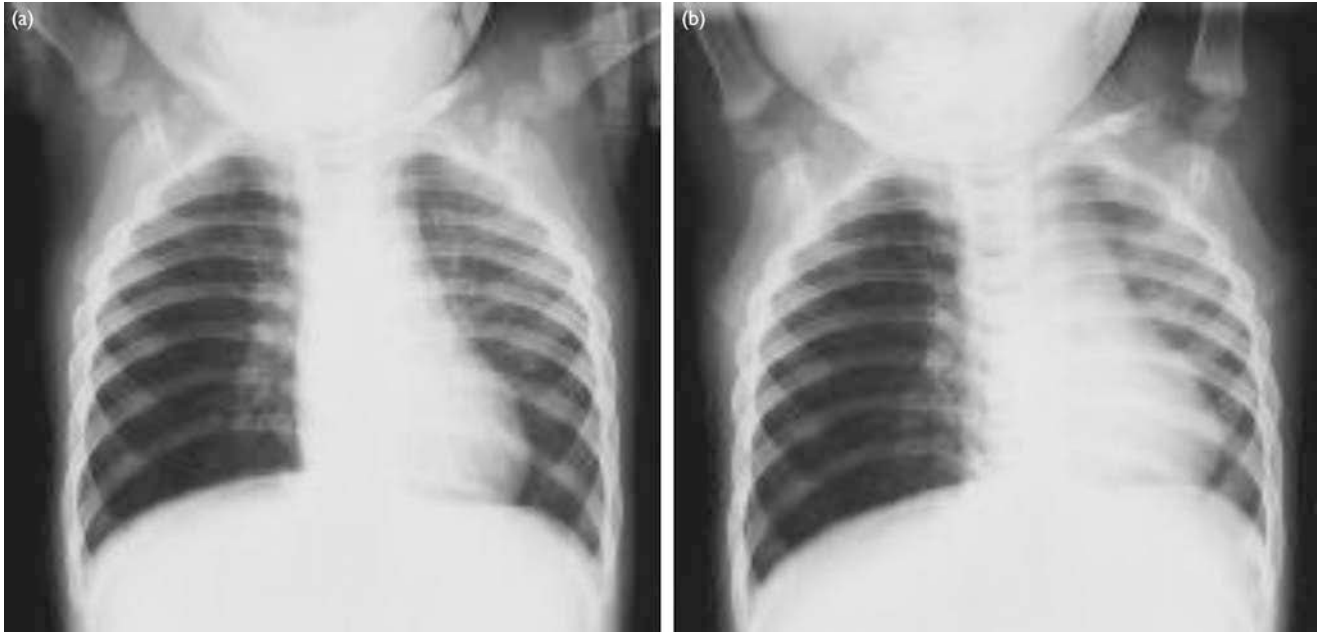In nonemergency cases, it is advisable to wait for the arrival of trained personnel, to assemble and check instruments, and to wait until the stomach of the patient is emptied. The instruments can be tested by attempting to find duplicate foreign bodies in the case of uncommon types.

The technique

For training and educational purposes, the technique is carried out by following these steps:

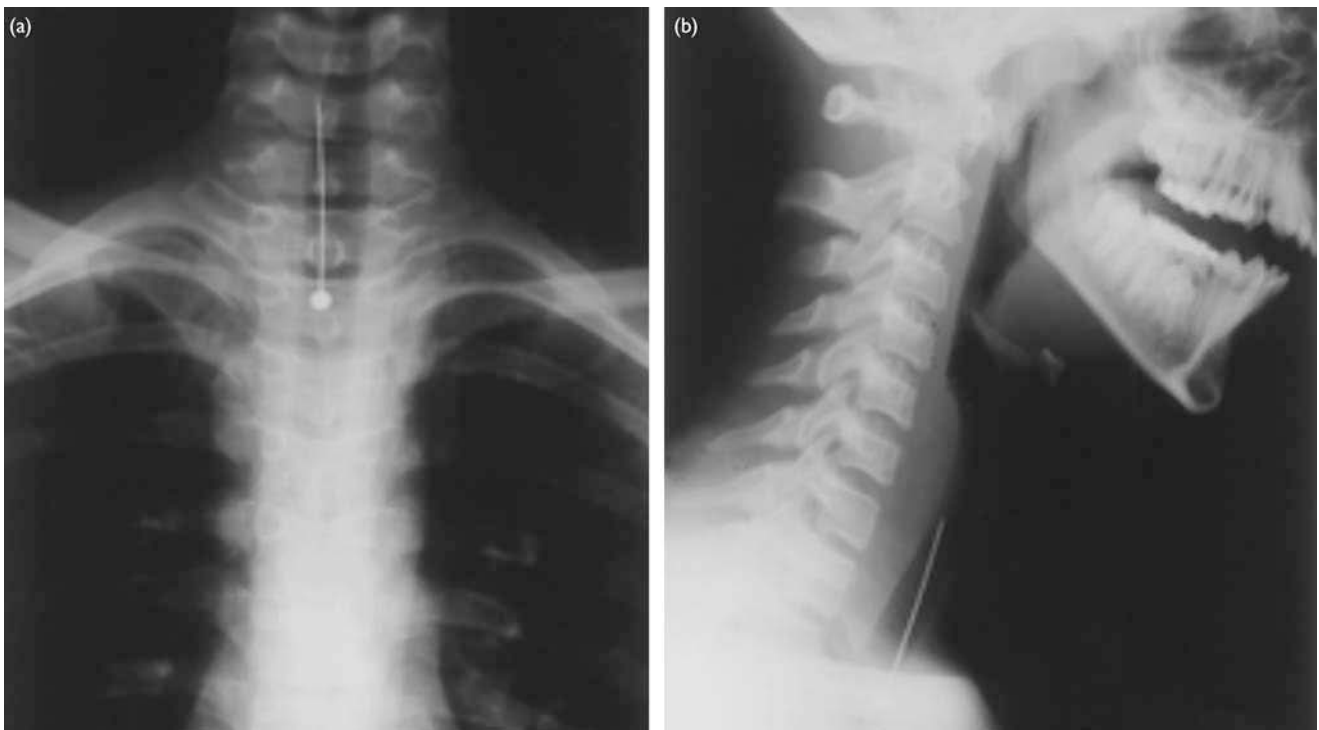
- (1) preparation;
- (2) positioning of the patient;
- (3) induction of anesthesia;

Figure 1



Plain radiograph of the chest showing enhanced air trapping in the expiratory film (b) as compared with the inspiratory film (a).

Figure 2



Postero-anterior (a) and lateral plain radiograph of the chest and neck (b) showing the foreign body in the trachea.

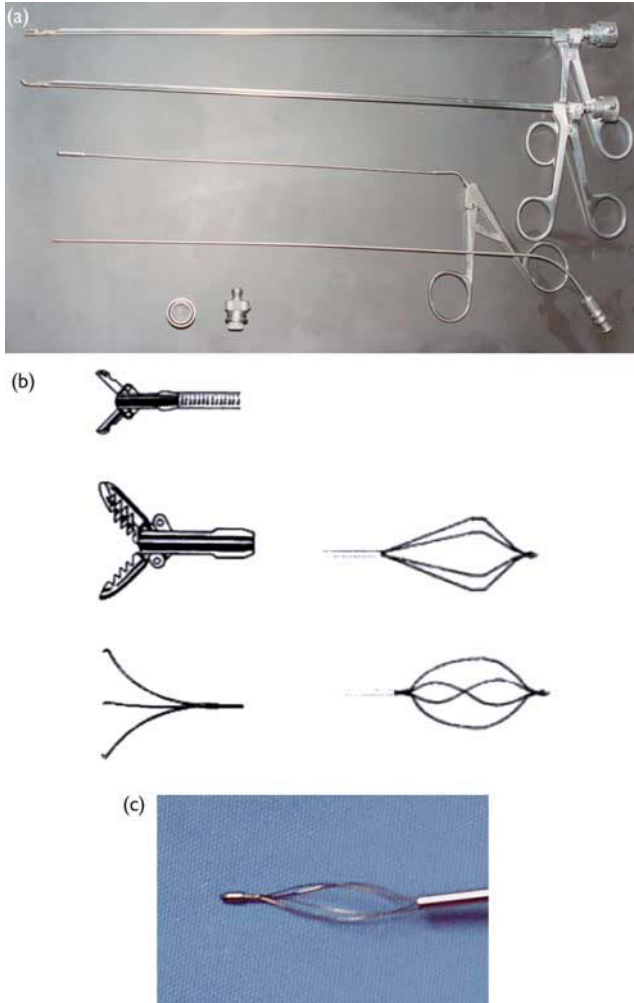
- (4) introduction of the bronchoscope;
- (5) identification of the anatomical region;
- (6) removal of the foreign body;
- (7) rechecking;
- (8) withdrawal of the bronchoscope;
- (9) emergence from the operating room; and

- (10) postoperative care.

Preparation

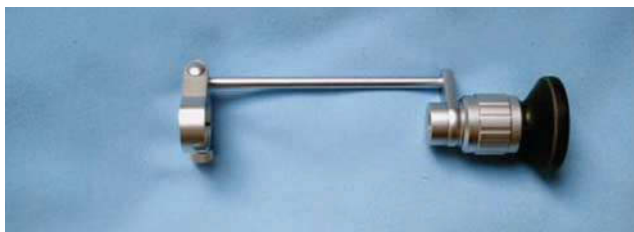
- (1) Dentures should be removed.

Figure 3



The forceps and suction set (a). The set should include forceps suitable for the type of foreign body expected (b). Also, special instruments such as basket coil and basket with a hexagonal base should be made available (c).

Figure 4



A magnification piece can be used with nonoptical forceps in uncomplicated cases.

- (2) Check your instruments: Instruments needed are those for general anesthesia, spontaneous ventilation, and bronchoscopy. For example:
- (a) laryngoscopes;
 - (b) bronchoscopes: age-matched appropriate bronchoscopes and a size smaller are needed in case edema or stenosis is encountered. Check the

Figure 5



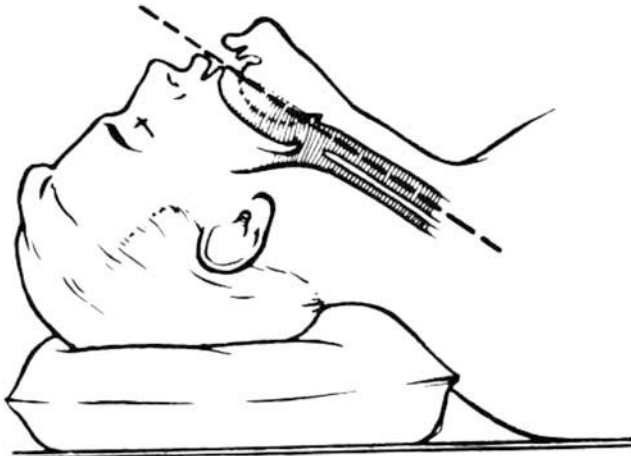
Check the length of the suction tube and the forceps in relation to the bronchoscope.

- length of the suction tube and the forceps in relation to the bronchoscope (Fig. 5).
- (c) suction;
- (d) forceps: optical forceps and/or a magnifying piece (Fig. 4). It is also advisable to have ordinary forceps for uncomplicated cases;
- (e) rod-lens telescopes.

Position

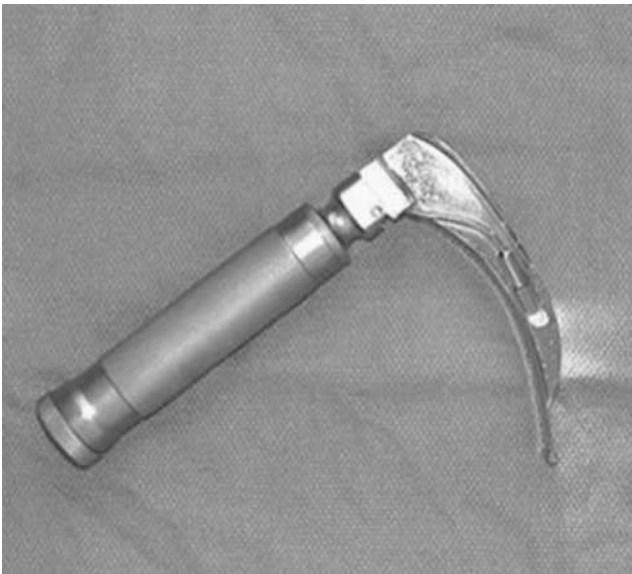The patient should be positioned supine with the head level with the end of the surgical table equipped with a moveable headpiece. The head should be fully extended

Figure 6



The shaving chin position.

Figure 7



Check the laryngoscope light.

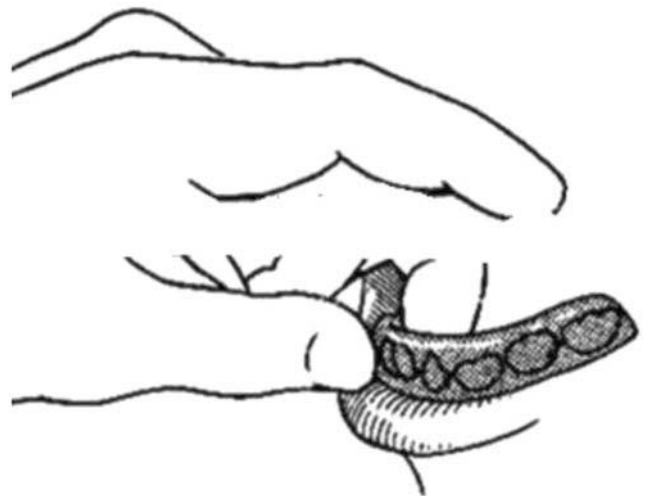
after keeping a pillow or a ring beneath it so that the chin points vertically upward in shaving chin position.

Anesthesia

Anesthesia is induced by administration of inhalation agents such as sevoflurane or halothane along with oxygen. Spontaneous ventilation should be through inhaled rather than fixed agents. Nitrous oxide is contraindicated in patients with air trapping because of the risk of lung overinflation. Pulse oximetry monitoring is mandatory. No muscle relaxant is given at the time of induction as a patient with a foreign body should never be paralyzed. Also, no endotracheal intubation is performed before evaluating the location of the foreign body.

Check the light of the laryngoscope (Fig. 7), remove any artificial denture, and use the tooth protector (Fig. 8).

Figure 8



Protect the upper teeth after removal of any removable artificial teeth.

Once the patient becomes tolerant to laryngoscopy, the airway can be sprayed with 4% lidocaine (4 mg/kg of 4% lidocaine or 0.1 ml of the 4% solution/kg) before insertion of the bronchoscope. Lidocaine doses up to 7 mg/kg have been proven safe if administered for more than 15 min.

It is important to handle the laryngoscope gently and under no circumstances should the upper teeth or gum be used as a fulcrum to lever the laryngoscope or the bronchoscope into position (Fig 9).

If 2.5-, 3.0-, and 3.5-mm internal-diameter bronchoscopes are used, there will be increased resistance to breathing. In combination with anesthetic agents that depress respiration, this increased resistance may result in compromised ventilation and oxygenation during spontaneous breathing.

Introduction of the bronchoscope

The bronchoscope is introduced while the anesthetic gases are being delivered to the patient, who is breathing spontaneously. The patient should be on 100% oxygen for at least 2 min.

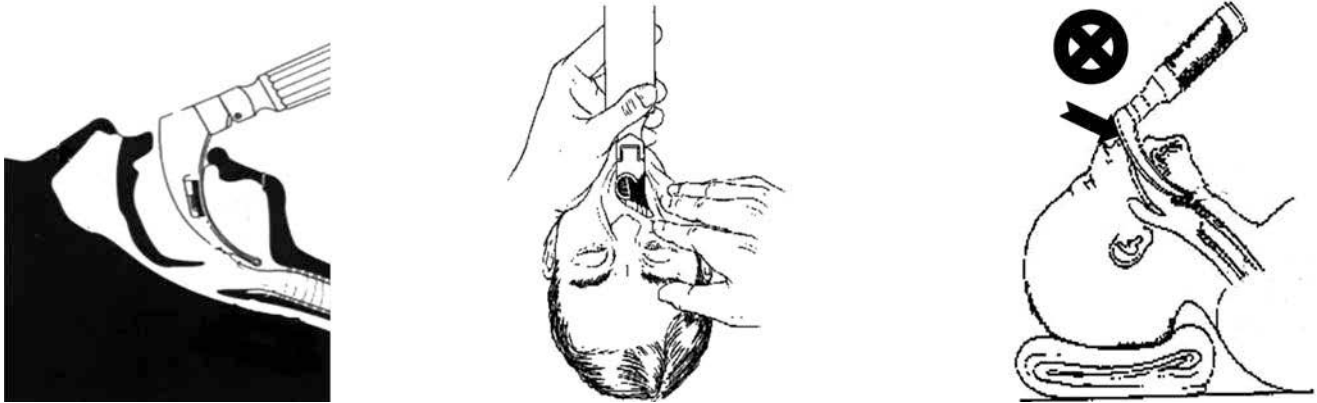
The forefinger and thumb of the left hand form a supportive guide for the bronchoscope and protect the teeth or gums from trauma (Fig. 8). Again, under no circumstances should the upper teeth or gum be used as a fulcrum to lever the bronchoscope into position.

The telescope is introduced after the laryngeal inlet is seen using the laryngoscope (Fig. 10).

The orientation of the bronchoscope is modified during its introduction between the vocal folds, as illustrated in Fig. 11. This is important to minimize trauma to the vocal folds or the arytenoids.

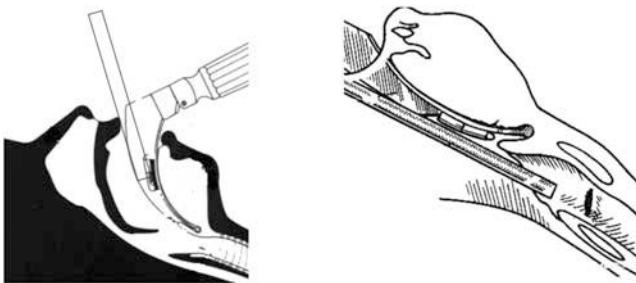
After stabilizing the bronchoscope in the trachea, connect the ventilation arm of the bronchoscope to the anesthesia equipment. Use a light connection tube to facilitate

Figure 9



The upper teeth or gum should not be used as a fulcrum to lever the laryngoscope or the bronchoscope into position.

Figure 10



Introduction of the bronchoscope guided by the laryngoscope after exposure of the laryngeal inlet.

handling of the bronchoscope. Short connection (Fig. 12) will limit the manipulation of the bronchoscope.

Anatomy identification

Observe the tracheal rings. The posterior membranous portion will bulge normally during expiration and cough. You have to familiarize yourself with the segmental anatomy and a three-dimensional feel for the tracheo-bronchial tree.

Foreign body manipulation

A muscle relaxant is requested after identifying the nature and location of the foreign body and before any manipulation. A muscle relaxant facilitates foreign body removal by keeping the vocal folds perfectly immobile, decreasing cough and bronchospasm. The airway is secured by the bronchoscope and the attached ventilation arm. Adequate relaxation of the upper airway and glottis reduces the risk of loss of the foreign body when it is pulled out of the airway with the grasping forceps and the bronchoscope.

Suction to remove any secretions is used sparingly and intermittently to avoid damage to the mucous membrane

and to avoid bleeding. The subsegments will also collapse with excessive suction.

Always enter the side opposite that of the known abnormal lung, as the preoccupation with the abnormal lung may preclude the operator from spending sufficient time for evaluation of the normal side.

Suction the opposite bronchus to improve oxygenation. Thereafter, advance to the foreign body and atraumatically grasp it. Smaller objects can be pulled through the bronchoscope, whereas larger objects should be pulled snugly against the bronchoscope and removed as a single unit.

In some cases you may need to remove granulation tissue or apply topical vasoconstrictors to staunch bleeding.

Attempts at removal of foreign body are carried out until the oximeter readings start to drop. When this occurs, typically after 2–3 min, the glass shield is repositioned and the patient is well ventilated with 100% oxygen, and the cycle is repeated as many times as necessary.

Recheck

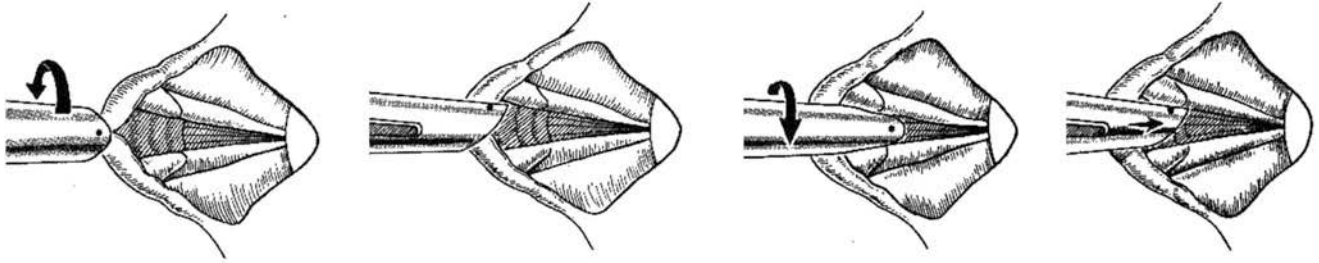
It is important to repeat bronchoscopy after suctioning of the bronchus as multiple foreign bodies may be found in 5–19% of cases.

Withdrawal of the bronchoscope

When the examination is complete, the bronchoscope is removed and a bag-and-mask ventilation with 100% oxygen is instituted. Withdrawal of the bronchoscope also requires care. This should be performed visually until the tip reaches the tongue.

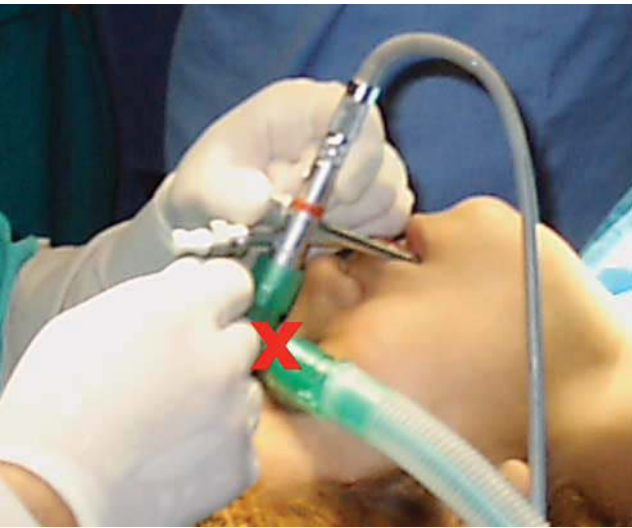An endotracheal tube may be inserted if the patient is apneic; if blood, secretions, or difficult anatomy makes the airway tenuous; or if the patient has a full stomach. If not, the patient may be awakened without an endotracheal tube, as long as he or she is closely observed by qualified personnel until airway reflexes have returned.

Figure 11



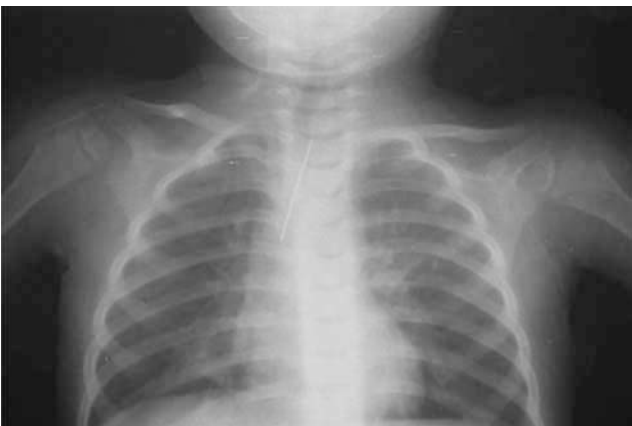Modification of the bronchoscope orientation during its introduction.

Figure 12



Short connection between the bronchoscope ventilation port and the anesthesia system is to be avoided as it hinders free handling of the bronchoscope and the instruments.

Figure 13



Plain postero-anterior chest radiograph showing a sharp foreign body (a needle) in the trachea and the right main bronchus.

Emergence from the operating room

During emergence from anesthesia, leave the child unstimulated and mechanically ventilated until spontaneous movement occurs. Do not stimulate with a suction catheter, jaw thrust, etc. It is very important that the child be completely conscious before extubation and not just aroused by inappropriate stimulation. Deep inhalation of the anesthetic described may require 10 or more min for recovery. It is desirable to extubate these patients in the operating room (not in the recovery room) as it is far easier to regain airway access, if necessary, in the operating room environment.

Postoperative care

Prevention/treatment of postoperative croup: for children with preoperative stridor or children who have subglottic involvement, consider giving dexamethasone (4–10 mg intravenously) before inserting the instrument into the airway. For postoperative stridor, consider administering nebulized racemic epinephrine (0.5 in 2.5 ml) in the recovery room. Chest physiotherapy may be needed for expelling retained secretions. Antibiotics and steroids are not routinely used.

Problems encountered during bronchoscopy for foreign body removal:

- (1) Slip of foreign body in the trachea causing complete airway obstruction: Push the foreign body back into a bronchus, preferably the same one, stabilize, and attempt removal again.
- (2) Sharp foreign body as in Fig. 13: Advance the bronchoscope over the foreign body to protect the mucosa during removal.
- (3) Large solid and semisolid objects: You have to be equipped with appropriate grasping instruments.
- (4) In patients with maxillofacial or cervical trauma: Use a flexible fiberoptic bronchoscope.
- (5) Rigid bronchoscopic procedure-related adverse events.

Most complications associated with rigid bronchoscopy are due to poor insertion techniques, prolonged trauma of the larynx and vocal cords, or failure to avoid or correct

Table 1 Storz bronchoscope sizes (Casselbrant and Alper, 2003)

Age	Premature	Premature–newborn	Newborn–6 months	6 months–1 year	1–2 years	3–4 years	5–7 years	Adult
Size	2.5	3.0	3.5	3.7	4.0	5.0	6.0	6.5
Length	20	20, 26	20, 26, 30	26, 30	36, 30	30	30, 40	43
ID (mm)	3.5	4.3	5.0	5.7	6.0	7.1	7.5	8.5
OD (mm)	4.2	5.0	5.7	6.4	6.7	7.8	8.2	9.2

ID, inside diameter; OD, outside diameter.

hypercapnia, hypoxemia, or hemodynamic instability. Bronchoscopists should not forget that the airway is shared with the anesthesiologist. A team approach to each procedure is therefore necessary. Oxygenation and ventilation always take priority over any rigid bronchoscopic manipulations. Any attempt at removal of the foreign body should be stopped to regain safe oxygenation of the patient. Other complications can be avoided by careful handling and inspection of the mouth, teeth and gums.

Patients with a history of laryngospasm or bronchospasm should be administered bronchodilators by inhalation and corticosteroids intravenously before and after the procedure. Bronchospasm results from insertion of instruments into an inadequately anesthetized airway, particularly if the bronchoscope is in contact with the carina.

Patients with cervical spine disease and severe osteoporosis should be evaluated carefully before deciding their fitness for rigid bronchoscopy. Airway wall perforation may occur at the posterior wall of the trachea, subglottis, and median walls of the left and right main bronchi just below the carina. Perforation can be caused by inadvertent rigid bronchoscopic manipulations.

Luxation or laceration of the vocal cords and arytenoids results from a faulty intubation technique; it can also occur if intubation is attempted before a patient is fully anesthetized.

Acknowledgements

Conflicts of interest

There are no conflicts of interest.