

Endoscopic management of a pediatric nasoethmoidal mucocele with intraorbital extension

Walied Radwan, Hesham Mohammad Eladl and Yasser Khafagy

Department of Otorhinolaryngology, Mansoura University Hospital, Mansoura University, Mansoura, Egypt

Correspondence to Hesham Mohammad Eladl, Department of Otorhinolaryngology, Mansoura University Hospital, Mansoura University, 35516 Mansoura, Egypt
Tel: +20 105 781 802; fax: +20 50 348 203; e-mail: meheladl@yahoo.ca or heshameladl@mans.edu.eg

Received 10 January 2012

Accepted 17 January 2012

The Egyptian Journal of Otolaryngology 2012, 28:80–84

Objective

To evaluate the transnasal endoscopic marsupialization of a pediatric nasoethmoidal mucocele with intraorbital extension in terms of technique, difficulty, and surgical outcome.

Design

Prospective study.

Patients and methods

Seven patients presented with a mucocele with intraorbital extension; they ranged in age from 8 to 14 years (average 11 years), and were treated using the transnasal endoscopic approach from March 2008 to March 2010. All patients underwent transnasal endoscopic marsupialization and were monitored clinically, radiologically, and endoscopically for a mean follow-up period of 15.3 months.

Results

Postoperative nasal examination showed no findings with improved orbital manifestations in all cases. Also, nasal congestion, obstruction, and postnasal discharge disappeared completely. Postoperative computed tomography evaluation indicated a significant improvement on comparison with the preoperative computed tomography score. No major complications were found in the study.

Conclusion

Transnasal endoscopic marsupialization of a pediatric mucocele with intraorbital extension is a safe technique and can be carried out successfully. Combined intensive medical treatment with surgery is important in a mucocele with an orbital manifestation. Nevertheless, this technique requires good experience with the relevant anatomy in a pediatric age group.

Keywords:

endoscopic, mucocele, nasoethmoidal, pediatric sinusitis, proptosis, sinus surgery

Egypt J Otolaryngol 28:80–84
© 2012 The Egyptian Oto - Rhino - Laryngological Society
1012-5574

Introduction

A mucocele is an epithelial-lined mucus-containing sac that fills a paranasal sinus and can expand by bone resorption and new bone formation [1].

The dynamic process at the interface of the epithelium and bone can help distinguish a mucocele from a blocked sinus filled with trapped mucus. Paranasal mucoceles are rare in children. The expanding mucocele often compresses the adjacent orbit. It is common for the patient to present to the ophthalmologist in the first instance with proptosis, visual symptoms, or epiphora. Other common features include headaches, facial swelling, or nasal obstruction [2].

A computed tomography (CT) scan is necessary for accurate analysis of the regional anatomy and extent of the lesion. MRI aids in defining the limited unusual lesions occurring in critical areas [3].

The traditional treatment of mucoceles has been to use an external approach to drain the mucocele, but the increasing use of endoscopic sinus surgery (ESS) has led

to the use of endonasal endoscopic drainage of the mucocele in cases that are anatomically suitable, whereas complex cases are managed by a combined external and endoscopic approach [4]. Endoscopic drainage has allowed successful treatment of the mucocele without complications or recurrence while avoiding facial scarring that occurs with the use of an external approach. Detailed knowledge of the relevant anatomy and familiarity with the techniques involved in ESS are essential prerequisites for surgeons undertaking this procedure [2]. In general, an endoscopic endonasal marsupialization is nowadays the surgical approach of choice in most cases of mucoceles [5], even in extensive mucoceles [6]. Also, endoscopic endonasal surgery is considered the gold standard technique for the treatment of pediatric paranasal sinus mucoceles [7].

Patients and methods

A prospective study was carried out on transnasal endoscopic marsupialization of pediatric nasoethmoidal mucoceles in the Otorhinolaryngology Department,

Mansoura University Hospital (four patients), and in Al-Noor Hospital (three patients), UAE, in the period from March 2008 to March 2010 utilizing the same technique. Seven pediatric patients [four men and three women, age range 8–14 years (average 11 years)] with nasoethmoidal mucoceles with an intraorbital extension (five ethmoidal and two frontoethmoidal mucoceles) were included in this study. This study has been approved by the ethical committees in both hospitals. All parents gave their informed consent before inclusion in the study.

Preoperative symptoms

In all patients, a case history was taken; the most common presenting symptoms were facial headache in all patients, postnasal drip in four patients, and nasal obstruction in three. However, orbital manifestations were detected in all cases in the form of blurred vision, periorbital edema, and swelling, which were resolved by intensive medical treatment (antibiotic injection, e.g. ceftriaxone after a culture sensitivity test for 7 days with follow-up CT). External swelling at the medial canthus was observed in four cases at presentation. There were no chest symptoms such as asthma or recurrent infection, except in one case (ciliary dyskinesia). All patients had a history of recurrent attacks of rhinosinusitis.

Preoperative examination

All patients were subjected to clinical, endoscopic, and CT examinations. According to the objective evaluation (mainly CT), surgery was conducted. Chest radiograph was performed for all patients. Also, ophthalmological consultations were performed for all cases.

All the patients underwent preoperative CT scans of the paranasal sinuses (Fig. 1). The CT score grading was based on the Lund–MacKay scoring system [8] Preoperative CT grading in this study group ranged from a score of 5 to 10 (average 7) according to the Lund–MacKay score.

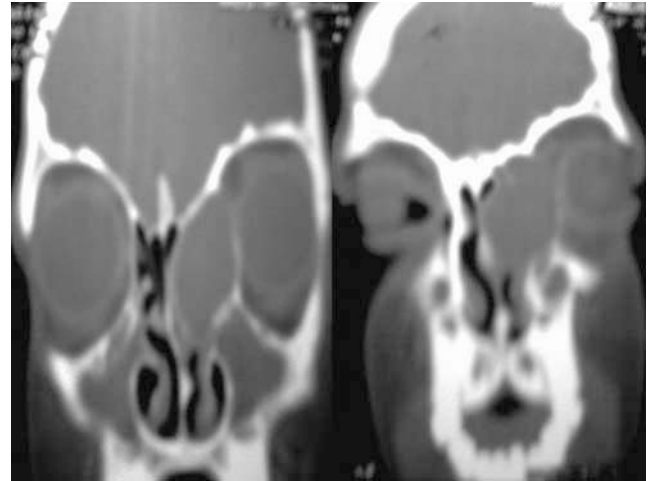
Seven patients (five ethmoidal and two frontoethmoidal mucocele) were included in our study. ESS was carried out for all cases. The operative details of each patient included the surgical steps, intraoperative blood loss in milliliter, and operative complications, if any. Patients' age at the time of treatment, sex, the type of mucocele, orbital manifestations, blood loss, and follow-up periods are shown in Table 1.

Postoperative follow-up included clinical examinations on regular visits, second-look endoscopy, the presence or absence of postoperative complications or recurrence, and postoperative CT of the paranasal sinus from 2 to 6 months postoperatively. The postoperative follow-up period ranged between 4 and 25 months (mean 15.3 months).

Intervention

Endoscopic marsupialization was performed for all patients, with a wide drainage of their contents. The

Figure 1



Preoperative computed tomography scan of the left ethmoidocele with an intraorbital extension (eroded lamina papyracea).

surgical procedure was performed under general anesthesia in all cases. The nose was prepared with 1/100,000 adrenaline on ribbon gauze for local hemostasis. A 4 mm endoscope was used; the surgical landmarks had to be clearly identified before opening the bulging mucocele directly into the nasal cavity. The bone overlying the mucocele was usually thin and dehiscent. The mucocele was opened carefully to avoid injury to unidentified important structures, and samples were routinely sent for microbiological assessment. The opening of the mucocele was enlarged using the usual ESS forceps to attain wide marsupialization. The lamina papyracea was found to be completely eroded, with the orbital periosteum forming the lateral wall of the mucocele cavity in four cases. This could be confirmed by gentle palpation of the globe. When no obvious intra-nasal component of the mucocele was present (three cases), conventional endoscopic dissection was carried out to locate it through anterior and/or posterior ethmoidectomy; in that case, the uncinat process was shifted from lateral to medial using a back biter. The sickle knife was not used to avoid injury to the lacrimal system and the orbit; care was taken to avoid injury to the teeth root, lamina papyracea, and skull base. Although minimal invasive sinus surgery is recommended in a pediatric population, wide marsupialization of the mucocele was performed in all cases to avoid closure and recurrence. Postoperatively, routine packing was performed. All patients were prescribed alkaline nasal douches and a topical corticosteroid spray, oxymetazoline hydrochloride spray, together with antibiotics. Patients were instructed not to blow the nose excessively for 2–3 weeks to avoid surgical emphysema.

Results

All patients with endoscopic marsupialization of a pediatric nasoethmoidal mucocele showed improvements on both subjective and objective assessments.

Table 1 Variables in the case series

N	Age (years)	Sex	Type of mucocele	Orbital manifestation	Preoperative CT score	Blood loss (ml)	Postoperative CT score	Follow-up period (months)
1	14	F	Frontoethmoidal	Periorbital swelling	7	66	0	25
2	12	M	Ethmoidal	Periorbital swelling	8	88	2	22
3	8	M	Ethmoidal	Periorbital swelling, medial canthal swelling	5	92	0	20
4	11	F	Ethmoidal	Periorbital swelling	5	70	1	16
5	10	M	Ethmoidal	Periorbital swelling, medial canthal swelling	10	97	2	12
6	13	M	Frontoethmoidal	Periorbital swelling, medial canthal swelling	8	–	1	8
7	9	F	Ethmoidal	Periorbital swelling, medial canthal swelling	6	–	1	4
Average	11				7	82.6	1	15.3

CT, computed tomography, F, female; M, male.

Subjective assessment

All patients showed resolution of nasal congestion, obstruction, and postnasal discharge. Facial pain disappeared completely in five cases and there were mild facial pain attacks (one to three attacks) in two patients 2 months postoperatively, which resolved completely thereafter. In terms of orbital manifestations, resolution of periorbital edema occurred in all patients. However, two patients (with preoperative medial canthal swelling) showed persistent periorbital edema and mild blurred vision 2 months postoperatively, which was resolved thereafter with medical treatment. No major postoperative complications such as orbital or brain injury or cerebrospinal fluid leakage were encountered.

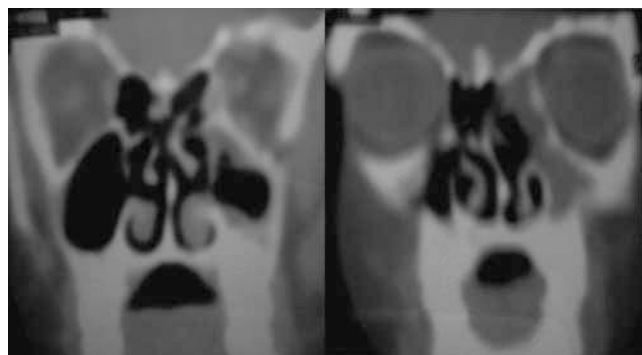Objective assessment

Nasal examination showed minimal crustations and granulations that resolved with medical treatment. Also, endoscopic evaluations (under local anesthesia) were carried out for all cases, showing no recurrence or adhesions in the drained sinuses. Visual examination was carried out postoperatively, with an improvement in all patients. Postoperative CT evaluation revealed a significant improvement in comparison with the preoperative CT score (Figs 2 and 3). The post-CT score ranged between 0 and 2.

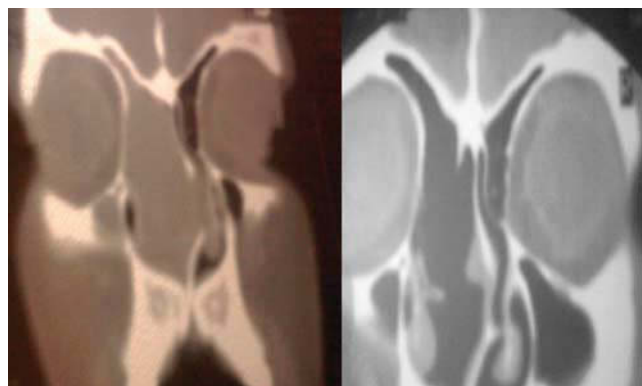
Discussion

A mucocele is an epithelial-lined mucus-containing sac completely filling a paranasal sinus that may expand through a dynamic process of bone resorption and new bone formation. It is the most common lesion that causes expansion of the paranasal sinuses [9]. The appearance of mucoceles of paranasal sinuses during infancy is very rare [10].

The etiologies of paranasal mucoceles were studied by Rombaux *et al.* [5]. One hundred and forty patients presenting 178 mucoceles were included in this study. Primitive mucoceles were reported in 35% of the patients, post-traumatic mucoceles in 2.1%, and postoperative mucoceles in 62.9%. Many predisposing factors to pediatric mucoceles have been suggested; many

Figure 2

Postoperative computed tomography scan of the left ethmoidocele with intraorbital extension.

Figure 3

Preoperative and postoperative computed tomography scan of the right frontoethmoidocele.

authors concluded that cystic fibrosis is a very important predisposing factor [7,11]. Some authors have even suggested that pediatric mucoceles occur exclusively in cystic fibrosis patients [12]. However, in our study, no association was found between pediatric mucoceles and cystic fibrosis, which was similar to the results of other studies [2,13]. Other etiological factors were trauma and inflammatory processes; or idiopathic [7]. In this series, an association between a pediatric mucocele and ciliary

dyskinesia was observed in only one case; however, a close association was observed with recurrent chronic rhinosinusitis with orbital manifestations. Nevertheless, more investigations and researches are needed to determine the exact predisposing factors for development of pediatric sinonasal mucocoeles.

The pediatric nasal cavity and paranasal sinuses, when compared with those in adults, differ not only in size but also in proportion. A detailed knowledge of the relevant anatomy and a familiarity with the techniques involved in ESS are essential prerequisites for surgeons performing this procedure [2].

A detailed knowledge of pediatric sinonasal anatomical landmarks and the growth pattern of pediatric sinuses are mandatory before usage of ESS in that age group. Also, surgeon should consider the unique position of uncinate and bulla to middle turbinate in pediatric age group which is relatively higher in position till it gradually reaches the adult position in between the age of 8 and 14 years. Nevertheless, mucocoeles may be associated with bony disturbances that may disrupt the already peculiar and specific anatomical landmarks in pediatric sinuses throughout their natural development. Also, an association with chronic rhinosinusitis with or without orbital complications and the possible effects on natural sinus development is another factor that must be taken into consideration. Extension of a mucocoele in the frontal sinus, although not common in a pediatric population, may represent another difficulty in the procedure.

In this study, the age was limited to 14 years, as the final stage of development and pneumatization of the paranasal sinuses occurs from age 8 to 14 years, roughly equal to adult size, and the maxillary sinus expands to the floor of the nose and beyond. Wolf *et al.* [14] studied the development of paranasal sinuses and classified the stages of development into the following: newborn and 1–4, 4–8, and 8–12 years. Meanwhile, Van Loosen *et al.* [15] stated that the maximum septal growth in children occurs in two different stages. The first stage is from birth to 5 years and the second stage is from 10 to 14 years.

Anderhuber *et al.* [16], by means of coronal CT scans of the paranasal sinuses with a slice thickness of 2 mm, showed that Keros classification is possible in children from the second year of life.

In terms of the site of paranasal sinus mucocoeles in all age groups, it predominantly occurs in the frontoethmoidal region (64%), followed by the maxillary sinus (18.6%), the sphenoid sinus (8.4%), and the posterior ethmoid sinus (6.7%). Uncommon locations have also been reported in 2.3% of cases (inferior turbinate, middle turbinate, pterygomaxillary space) [5]. In this case series, five were ethmoidal and two were frontoethmoidal mucocoeles.

Traditionally, it has been emphasized that sinus mucocoeles should be removed completely for a cure. However, with the introduction of endoscopic sinus surgical instruments and techniques, there has been a trend toward transnasal endoscopic management of sinus mucocoeles [17]. An endoscope has been used by many sinuscopists in the

management of pediatric mucocoeles, and endoscopic drainage is recommended for the treatment of mucocoeles in children. Sciarretta *et al.* [13] have pointed out the effectiveness of the endoscopic approach for the treatment of three children affected by mucocoeles. Two patients complained of visual disturbances, whereas one complained of persistent bitemporal headache. These young patients were free from any recurrence and symptoms at 36, 30, and 16 months of follow-up, respectively. However, Di Cicco *et al.* [18] studied paranasal mucocoeles in children with cystic fibrosis; they showed no recurrence in a follow-up period that ranged from 3 to 6 years. Endoscopic sinus surgery seems to be a safe and efficient treatment of pediatric mucocoele even in cystic fibrosis patients. Also, ESS is effective in improving ophthalmic symptoms and signs due to paranasal sinus mucocoeles. ESS may be a viable treatment for paranasal sinus mucocoeles with an orbital extension, and a direct orbital approach is rarely necessary [19]. The endoscopic technique can be safely used for the management of mucocoeles with skull-base and/or orbital erosion and open adjunct approaches can be avoided in most cases [20]. In this study, endoscopic management of pediatric mucocoeles with an orbital extension showed complete resolution of the preoperative orbital and nasal manifestations without recurrence of the mucocoele at a mean follow-up period of 15.3 months.

Conclusion

Endoscopic endonasal marsupialization is efficient in the treatment of pediatric mucocoeles with an orbital extension. Also, it is considered an easy and safe approach for the management of pediatric mucocoeles with different etiologies. Although minimal invasive sinus surgery is recommended in a pediatric population, wide marsupialization of the mucocoele was performed in all cases to avoid recurrence. Experience with the anatomical development and definite knowledge of surgical landmarks in a pediatric population are prerequisites in this surgery. Also, further researches are needed to distinguish the exact mechanism and etiology of pediatric paranasal sinus mucocoeles.

Acknowledgements

This study was funded by the Mansoura University.

Conflicts of interest

There are no conflicts of interest.

References

- 1 Lund VJ, Milroy CM. Fronto-ethmoidal mucocoeles: a histopathological analysis. *J Laryngol Otol* 1991; 105:921–923.
- 2 Hartley BEJ, Lund VJ. Endoscopic drainage of pediatric paranasal sinus mucocoeles. *Int J Pediatr Otorhinolaryngol* 1999; 50:109–111.
- 3 Serrano E, Klossek JM, Percodani J, Yardeni E, Dufour X. Surgical management of paranasal sinus mucocoeles: a long-term study of 60 cases. *Otolaryngol Head Neck Surg* 2004; 131:133–140.

- 4 Lund VJ. Endoscopic management of paranasal sinus mucocoeles. *J Laryngol Otol* 1998; 112:36–40.
- 5 Rombaux P, Bertrand B, Eloy P, Collet S, Daele J, Bachert C, *et al.* Endoscopic endonasal surgery for paranasal sinus mucocoeles. *Acta Otorhinolaryngol Belg* 2000; 54:115–122.
- 6 Lee TJ, Li SP, Fu CH, Huang CC, Chang PH, Chen YW, *et al.* Extensive paranasal sinus mucocoeles: a 15-year review of 82 cases. *Am J Otolaryngol Head Neck Med Surg* 2009; 30:234–238.
- 7 Nicollas R, Facon F, Sudre Levillain I, Forman C, Roman S, Triglia JM. Pediatric paranasal sinus mucocoeles: etiologic factors, management and outcome. *Int J Pediatr Otorhinolaryngol* 2006; 70:905–908.
- 8 Lund VJ, Mackay IS. Staging in rhinosinusitis. *Rhinology* 1993; 31: 183–184.
- 9 Gavioli C, Grasso DL, Carinci F, Amoroso C, Pastore A. Mucocoeles of the frontal sinus. Clinical and therapeutical considerations. *Minerva Stomatol* 2002; 51:385–390.
- 10 Pérez González R, Morais Pérez D, Martín Sigüenza G, Bachiller Alonso J. Childhood nasal sinus mucocoeles. Review and report of a new case. *An Otorrinolaringol Ibero Am* 2002; 29:27–36.
- 11 Alvarez RJ, Liu NJ, Isaacson G. Pediatric ethmoid mucocoeles in cystic fibrosis: long-term follow-up of reported cases. *Ear Nose Throat J* 1997; 76:538–547.
- 12 Guttenplan MD, Wetmore RF. Paranasal sinus mucocoele in cystic fibrosis. *Clin Pediatr* 1989; 28:429–430.
- 13 Sciarretta V, Pasquini E, Farneti G, Ceroni AR. Endoscopic treatment of paranasal sinus mucocoeles in children. *Int J Pediatr Otorhinolaryngol* 2004; 68:955–960.
- 14 Wolf G, Anderhuber W, Kuhn F. Development of the paranasal sinuses in children: implications for paranasal sinus surgery. *Ann Otol Rhinol Laryngol* 1993; 102:705–711.
- 15 Van Loosen J, Baatenburg De Jong RJ, Van Zanten GA, Engel T, Lanjewar DN, Van Velzen D. A cephalometric analysis of nasal septal growth. *Clin Otolaryngol* 1997; 22:453–458.
- 16 Anderhuber W, Walch C, Fock C. Configuration of ethmoid roof in children aged 0 to 14 years. *Laryngorhinootologie* 2001; 80:509–511.
- 17 Har El G. Endoscopic management of 108 sinus mucocoeles. *Laryngoscope* 2001; 111:2131–2134.
- 18 Di Cicco M, Costantini D, Padoan R, Colombo C. Paranasal mucocoeles in children with cystic fibrosis. *Int J Pediatr Otorhinolaryngol* 2005; 69:1407–1413.
- 19 Khong JJ, Malhotra R, Wormald PJ, Selva D. Endoscopic sinus surgery for paranasal sinus mucocoele with orbital involvement. *Eye* 2004; 18:877–881.
- 20 Sautter NB, Citardi MJ, Perry J, Batra PS. Paranasal sinus mucocoeles with skull-base and/or orbital erosion: is the endoscopic approach sufficient? *Otolaryngol Head Neck Surg* 2008; 139. pp. 570–574.