

TMC: a new staging system for tympanomastoid cholesteatoma

Aziz Belal, Mahmoud Reda, Ahmed Mehanna and Yousef Belal

Alexandria Ear Hospital, Alexandria, Egypt

Correspondence to Mahmoud Reda, Alexandria Ear Hospital, Alexandria, Egypt
Tel: +01223363987;
e-mail: mahmouredda99@yahoo.com

Received 18 September 2011

Accepted 29 October 2011

The Egyptian Journal of Otolaryngology
2012, 28:12–16

Objective

To present a new staging system for tympanomastoid cholesteatoma that is based on the primary site of pathology in the middle ear (T), its spread to the mastoid (M), and to the surrounding structures, either cranial, intracranial, or extracranial, and presence of complications (C).

Setting

Tertiary Care Center (ENT Department, Faculty of Medicine, University of Alexandria, Egypt).

Study design

Clinical Prospective Study.

Methods

The TMC staging system is based on the correlation of preoperative otoscopy findings with computed tomography examination of the temporal bone. Preoperative findings have also been correlated with intraoperative findings.

Patients

We included 120 patients with tympanomastoid cholesteatoma diagnosed preoperatively.

Results

In 87% of the patients, preoperative and intraoperative staging were well correlated.

Conclusion

The TMC staging system of cholesteatoma paves the way to a logical roadmap for functional surgery of the middle ear and mastoid; in addition, it makes the comparison of clinical studies about cholesteatoma meaningful.

Keywords:

atticotomy, cholesteatoma, mastoid, mastoidectomy, tympanic cavity

Egypt J Otolaryngol 28:12–16
© 2012 The Egyptian Oto - Rhino - Laryngological Society
1012-5574

Introduction

Surgical strategy of tympanomastoid cholesteatoma may be based on factors related to the patient, surgeon, or disease. Patient factors include general factors, such as age, general medical status, and occupation and local factors, such as status of hearing, only one hearing ear, bilateral cholesteatoma, mastoid pneumatization, and eustachian tube function. Surgeon factors include preference and training of the surgeon at a particular time. Factors related to the disease include the anatomical site of origin, paths of spread inside and outside the temporal bone, histological characteristics and biological behavior of cholesteatoma. Pathology seems to be the most logical way to outline a surgical strategy for cholesteatoma [1–3].

Why staging cholesteatoma?

Reviewing the techniques used to manage middle ear cholesteatoma showed that priority was given to the mastoid rather than the middle ear [3–6]. However, histopathological and clinico-operative studies have shown that the involvement of middle ear is much higher than the mastoid in primary and revision cholesteatoma cases [7–11]. Thus, we have to empathize the concept that is based on tailoring the surgical technique according to the site of

pathology and its extensions. Comparison of clinical and operative studies about tympanomastoid cholesteatoma always had the problem of finding a ‘standard’ to make a meaningful comparison. Terms of small, big, and huge cholesteatomas made comparisons between the different studies like comparing apples to oranges.

A standard staging system will definitely solve this problem.

Attempts to stage tympanomastoid cholesteatoma

The classical etiological classification [7] of cholesteatoma into congenital, primary acquired, and secondary acquired cholesteatoma is an etiopathological classification and describes well the site of origin of cholesteatoma, its paths of spread, and its histological behavior.

Lau and Tos [8] otoscopically classified cholesteatoma into the following types: attic type in the pars flaccida of the eardrum; sinus cholesteatoma starting as a postero-superior retraction or perforation of the pars tensa and extending to the tympanic sinus, posterior tympanum, and beyond; and tensa cholesteatoma presenting as retraction and adhesion of the entire pars tensa involving the tympanic orifice of the Eustachian tube (it may also extend further into the attic).

Tos and Lau [12] latter modified their classification into: attic, pars tensa I (marginal disease), and pars tensa II (central disease) cholesteatomas. Meyerhoff and Truelson [13] classified cholesteatoma into primary acquired, secondary acquired, tertiary acquired, and congenital cholesteatomas.

Saleh and Mills [14] introduced the Site-Ossicles-Complications classification System. It can be summarized as follows:

- S1: if the cholesteatoma is restricted to the site where it had started.
- S2: when the disease extends to another site.
- S3: if it affects three sites.
- S4: if it affects four sites.
- S5: cases in which the primary site is affected plus four or more sites are also involved.

Authors distinguished seven sites used in this classification: attic, antrum, middle ear, mastoid, auditory tube, labyrinth, and middle fossa.

- O0: if the ossicle chain is intact.
- O1: if incus is eroded but without chain discontinuity.
- O2: if incus and stapes suprastructures are eroded.
- O3: if the malleus head and incus are absent and stapes superstructure is eroded.
- C0: when there is no complication.
- C1: if there is one complication.
- C2: if there are two or more complications.

Regarding complications, the authors considered lateral semicircular canal fistula, facial palsy, total sensorineural auditory loss, sinus thrombosis, and intracranial invasion.

We thought that the latter staging system was very useful and well designed. However, it did not use and correlate to the computed tomography (CT) scanning, which has

an important rule in studying the site of tympanomastoid cholesteatoma, in the staging system. It staged ears according to the status of ossicles, which is not a reliable factor because the final status of the ossicular chain cannot be assessed except after the disease has been completely eradicated. Furthermore, the previous staging system did not categorize complications into cranial and intracranial, which we think is an important point in staging.

New staging system for tympanomastoid cholesteatoma

After reviewing the previous staging system, and depending on our clinico-operative observations and experiences, we designed a new staging system for tympanomastoid cholesteatoma from stage 1 to stage 5 depending on the site of disease in the tympanic cavity (T), the mastoid cavity (M), and the presence of any complication (C). Staging of any case is made according to the official clinical (otoscopic/microscopic/endoscopic) examination, the radiological study (axial, coronal, and saggital reconstruction views of high-definition CT Petrous bone), and the clinicoradiological correlation. (Tables 1 and 2, Fig. 1).

Case reports

Case 1

A 40-year-old patient presented with recurrent discharging from the right ear.

Otосcopy: attic cholesteatoma and small polyp on one side of the head of malleus and normal mesotympanum (T1a).

CT scan: it showed attic cholesteatoma with the involvement of the mastoid cavity only in the antrum (M1).

There was no clinical or radiological manifestation of complications (C0).

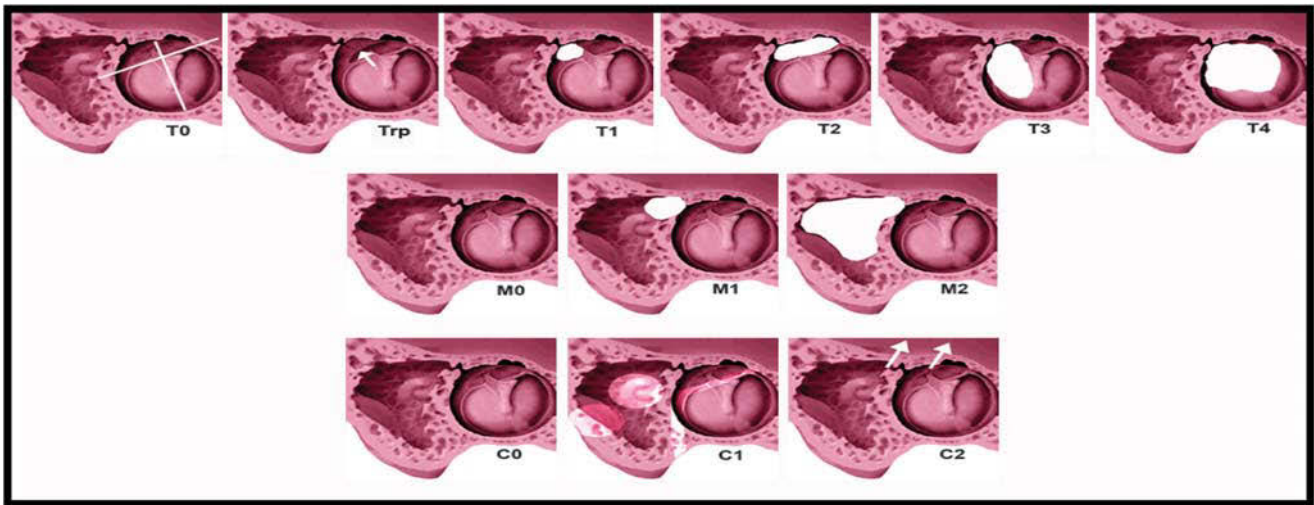
Table 1 TMC Staging system of tympanomastoid cholesteatoma

(T) Tympanic cavity involvement:				
T0: no tympanic cavity involvement				
Trp: retraction pocket (precholesteatoma)				
T1: cholesteatoma involving one side of one region				
T1a: one side of epitympanum				
T1b: one side of mesotympanum				
T2: cholesteatoma involving both sides of one region				
T1a: both sides of epitympanum				
T1b: both sides of mesotympanum				
T3: cholesteatoma extending from one region of the middle ear to another (vertical spread)				
T4: holotympanic cholesteatoma filling the whole middle ear				
Regions (epitympanum, mesotympanum, and hypotympanum)				
Sides (anterior or posterior in relation to a line along handle of malleus)				
(M) Mastoid cavity involvement:				
M0: no mastoid cavity involvement				
M1: cholesteatoma extending to the mastoid antrum only				
M2: cholesteatoma extending to mastoid cavity				
(C) Presence of complications:				
C0: uncomplicated cholesteatoma				
C1: cranial or extracranial complication				
C2: intracranial complications				
Stages				
1	2	3	4	5
Trp-1 M0 C0	T2 M0 C0	T3 M0 C0 Trp-3 M1 C0	T4 M0 C0 Any T M2 C0 Any T Any M C1	Any T Any M C2

C, complication; M, mastoid; rp, retraction pocket; T, tympanic.

Table 2 Comparison of preoperative and intraoperative findings

Stage	No. of cases	Good correlation	Underestimated cases	Overestimated Cases	Correlation (%)	Average correlation (%)
T1	5	5	–	–	100	87.3
T2	42	40	2	–	95	
T3	58	40	16	2	68	
T4	15	13	1	1	86.5	
M0	37	18	9	–	66.6	77.7
M1	39	20	9	1	74	
M2	54	50	–	4	92.5	
C0	115	104	11	–	90	96.6
C1	3	3	–	–	100	
C2	2	2	–	–	100	
Total no. of cases	120	87%	11%	1%		

Figure 1

Staging system of tympanomastoid cholesteatoma.

Staging: T1M1C0 = stage 3, intraoperative findings were corresponding to TMC staging (Fig. 2).

Case 2

A 24-year-old male patient presented with right ear hearing loss and occasional ear discharge.

Otосcopy: it showed a white pearly mass behind an intact tympanic membrane (T3).

CT scan: it showed a soft tissue mass in the tympanic cavity, with well-aerated mastoid (M0). The mass was eroding the basal turn of the cochlea (C1).

Staging: T3M0C1 = stage 4, intraoperative findings were corresponding to TMC staging (Fig. 3).

Case 3

A 35-year-old male patient presented with persistent foul-smelling intermittent discharge from the right ear.

Otосcopy: it showed cholesteatoma involving the whole tympanic cavity (T4).

CT scan: it showed cholesteatoma filling the whole mastoid cavity (M2).

There was no clinical or radiological manifestation of complications (C0).

Staging: T4M2C0 = stage 4, intraoperative findings were corresponding to TMC staging (Fig. 4).

Correlation of preoperative and intraoperative findings

A total of 120 cases of tympanomastoid cholesteatoma examined and operated at the Alexandria Ear Hospital, Egypt in the period between 2005 and 2010 were included in this study. Cases were examined preoperatively (otoscopy, microscopy, and endoscopy), were CT scanned (coronal and sagittal views), and then were preoperatively staged according to the TMC staging system. Cases were operated upon and then staged again according to the intraoperative findings. Staging correlated well in 87% of cases. Preoperative staging underestimated the size of cholesteatoma in 11% of the cases and overestimated it in 1% of cases. Table 2 summarizes the preoperative and intraoperative findings in these cases. MRI imaging of the temporal bone may help in better preoperative estimation of the size of cholesteatoma in future.

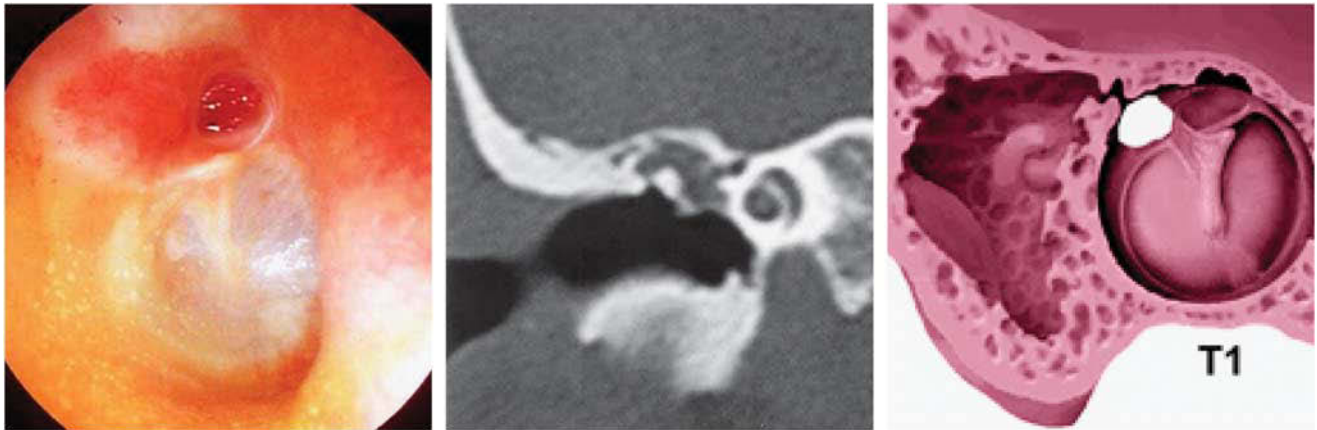
Conclusion

Although different staging systems for tympanomastoid cholesteatoma were described, they did not use the

advances in CT scanning, they overestimate the importance of preoperative status of ossicles, and they did not categorize complications into cranial and intracranial. Our TMC staging system is a clinoradiological system that

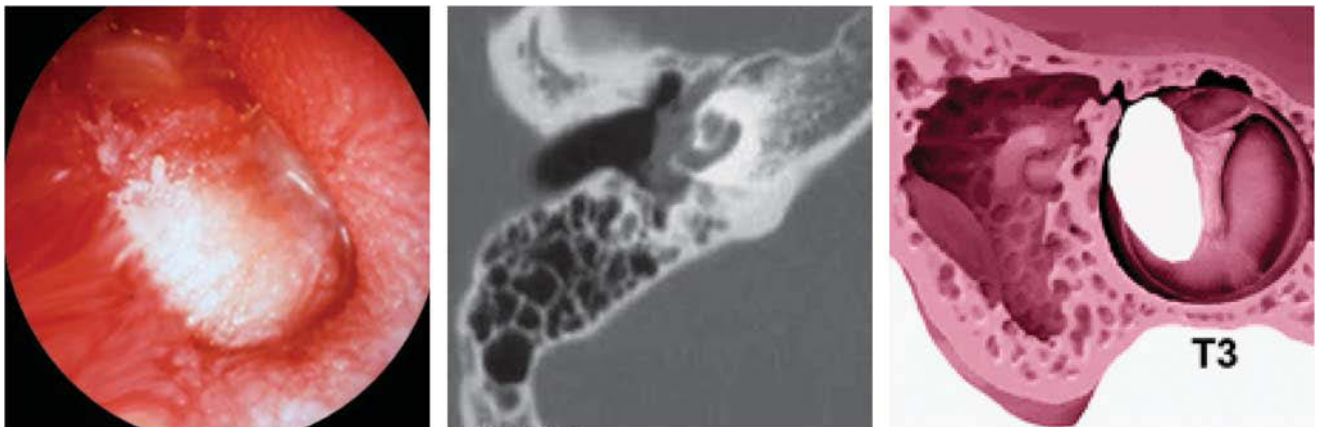
depends on the correlation between preoperative and intraoperative findings. TMC staging can be used to plan a roadmap of functional surgery in cases of tympanomastoid cholesteatoma. Furthermore, it simplifies the terminology

Figure 2



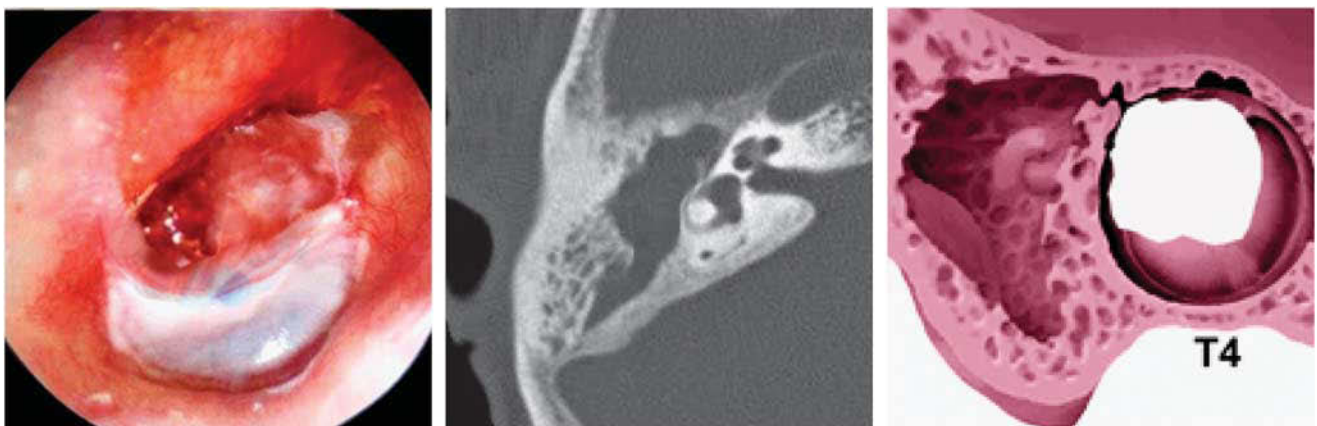
Otoscopic and computed tomography findings of case 1.

Figure 3



Otoscopic and computed tomography findings of case 2.

Figure 4



Otoscopic and computed tomography findings of case 3.

used to describe a case of tympanomastoid cholesteatoma. Thus, it facilitates a reliable type-specific comparison of published data reporting the results of tympanomastoid surgery. With the advances in the radiodiagnosis and histopathological technology, more tools of assessment of tympanomastoid cholesteatoma can be applied to design a more beneficial staging system in the future.

Acknowledgements

Conflicts of interest

There are no conflicts of interest.

References

- 1 Graham MD, Delap TG, Goldsmith MM. Closed tympanomastoidectomy. *Otolaryngol Clin North Am* 1999; 32:547–554.
- 2 Syms MJ, Luxford WM. Management of cholesteatoma: status of the canal wall. *Laryngoscope* 2003; 113:443–448.
- 3 Kapur TR. Causes of failure of combined approach tympanoplasty in the treatment of acquired cholesteatomas of the middle ear and the mastoid. *J Laryngol Otol* 1995; 109:710–712.
- 4 Reddy TN, Dutt SN, Shetty A, Maini S. Transcanal atticotomy and transcortical mastoidectomy for cholesteatoma: the Farrior–Olaizola technique revisited. *Ann Otol Rhinol Laryngol* 2001; 110:739–745.
- 5 Uzun C, Yagiz R, Tas A, Adali MK, Koken M, Karasalioglu AR. Combined Heermann and Tos (CHAT) technique in cholesteatoma surgery: surgical technique and preliminary results. *J Laryngol Otol* 2005; 119:429–435.
- 6 Dornhoffer JL. Retrograde mastoidectomy with canal wall reconstruction: a follow-up report. *Otol Neurotol* 2004; 25:653–660.
- 7 Olszewska E, Wagner M, Bernal Sprekelsen M, Ebmeyer J, Dazert S, Hildmann H, *et al.* Etiopathogenesis of cholesteatoma. *Eur Arch Otorhinolaryngol* 2004; 261:6–24.
- 8 Lau T, Tos M. Treatment of sinus cholesteatoma. Long-term results and recurrence rate. *Arch Otolaryngol Head Neck Surg* 1988; 114:1428–1434.
- 9 Sethom A, Akkari K, Dridi I, Tmimi S, Mardassi A, Benzarti S, *et al.* Preoperative CT scan in middle ear cholesteatoma. *Tunis Med* 2011; 89: 248–253.
- 10 Alzoubi FO, Odat HA, Al Balas HA, Saeed SR. The role of preoperative CT scan in patients with chronic otitis media. *Eur Arch Otorhinolaryngol* 2009; 266:807–809.
- 11 Williams MT, Ayache D. Imaging in adult chronic otitis. *J Radiol* 2006; 87 (11 C2):1743–1754.
- 12 Tos M, Lau T. Late results of surgery in different cholesteatoma types. *ORL* 1989; 51:33–49.
- 13 Meyerhoff WL, Truelson J. Cholesteatoma staging. *Laryngoscope* 1986; 96 (9 I):935–939.
- 14 Saleh HA, Mills RP. Classification and staging of cholesteatoma. *Clin Otolaryngol Allied Sci* 1999; 24:355–359.