

# C-arm-assisted internal fixation of pediatric mandibular fracture

Mohammad W. El-Anwar<sup>a</sup>, Mohamed Salah<sup>a</sup>, Ghada Abdulmonaem<sup>b</sup>

Departments of <sup>a</sup>Otorhinolaryngology Head and Neck Surgery, <sup>b</sup>Radiodiagnosis, Faculty of Medicine, Zagazig University, Zagazig, Egypt

Correspondence to Mohammad W. El-Anwar, MD, Department of Otorhinolaryngology Head and Neck Surgery, Faculty of Medicine, Zagazig University, Zagazig, Egypt  
Tel: +20 100 469 5197; fax: 0020552307830; e-mail: mwenteg@yahoo.com

Received 24 October 2017

Accepted 23 December 2017

The Egyptian Journal of Otolaryngology  
2018, 34:122–126

## Introduction

Dentition is one of the main concerns while managing pediatric mandibular fractures. The aim of this study was to assess the results of the usage of intraoperative images with C-arm to identify and protect the roots of nonerupted teeth during open reduction and internal fixation (OR/IF) of pediatric mandibular fractures.

## Patients and methods

This prospective study was conducted on children who had mandibular fractures with unerupted mandibular teeth appearing on panoramic examination. All patients were managed by OR/IF by titanium miniplates using manual maxillomandibular fixation treated under general anesthesia. Titanium miniplate was positioned according to preoperative radiology. Then C-arm images were taken to confirm the screws position away from the nonerupted teeth. Lastly, the screws were inserted at C-arm-confirmed safe position. Then the results were assessed such as reliability, difficulties of the procedures, operative time, dental occlusion, average intrinsic vertical mouth opening, and complication.

## Results

A total of 20 children with parasymphiseal fractures, with mean age of 6.5 (range: 4–9) years, were included. No difficulties were detected during application of the C-arm during surgery regarding position or projection, and the registered views were clearly seen and easily interpreted. Thus, added duration for C-arm use did not significantly elongate the operative time. Postoperative radiology confirmed proper position of all fixed screws away for the teeth root or unerupted teeth.

## Conclusion

Operative C-arm-guided plate screws positioning and fixation can effectively obviate the risk of injury to tooth root or bud during OR/IF of mandibular.

## Keywords:

C-arm, children, fracture mandible, internal fixation, maxillomandibular fixation

Egypt J Otolaryngol 34:122–126

© 2018 The Egyptian Journal of Otolaryngology

1012-5574

## Introduction

Maxillofacial fractures in general and mandibular fractures in particular are less common in children than in adults. Differences between children's and adults' facial bony structures are essentially the resilience of the developing mandible and the smaller size of the mandible relative to the cranium and forehead in children [1].

Displaced mandibular fractures in children need to be reduced and immobilized. Such fixation can be achieved with maxillomandibular fixation (MMF) or open reduction and internal fixation (OR/IF) or a combination of both. MMF is more difficult in children than in adult. Fewer teeth may be available, roots of deciduous may be resorbed, their surfaces are not retentive, and the crowns of incisors and canines and partially erupted permanent teeth may be unfavorably shaped for fixation of interdental wires and arch bars [2].

Today, OR/IF has become the standard treatment of displaced fractures [2–4]. In children, OR/IF can be

done provided that intraosseous tooth buds and erupting teeth in the line of fracture will not be traumatized during plate and screw placement [3], but the presence of tooth buds makes OR/IF risky [5]. The presence of tooth germs, the number of permanent teeth present, the size of primary teeth, and the resorption of their roots are important factors that should be taken into account when treating these fractures [6].

Thus, pediatric mandibular fractures pose a particular challenge to the maxillofacial surgeon. Closed reduction with acrylic splints and circum-mandibular wiring was favored by many surgeons [6]. However, many difficulties were associated with the period of MMF such as airway problems, poor nutrition, weight loss, poor mouth hygiene, phonation difficulties,

This is an open access journal, and articles are distributed under the terms of the Creative Commons Attribution-NonCommercial-ShareAlike 4.0 License, which allows others to remix, tweak, and build upon the work non-commercially, as long as appropriate credit is given and the new creations are licensed under the identical terms.

insomnia, social inconvenience, patient discomfort, work loss, and difficult in recovering normal range of jaw function [7]. Moreover, reduction is not possible with this technique in displaced or multiple fracture segments or infected old fractures that make it mandatory to open and reduce the segments [8].

Although intraoperative C-arm is routinely used during orthopedic fractures repair, its use during OR/IF of pediatric mandibular fracture was not investigated before.

The aim of this study was to assess the use of intraoperative images with a C-arm (mobile image intensifier system) as an intraoperative tool to identify and protect the teeth roots and unerupted teeth during OR/IF of pediatric mandibular fractures to achieve successful protection of tooth buds.

## Patients and methods

### Study design

This prospective study was conducted at the Otorhinolaryngology Department, over a period from January 2013 to January 2016. Informed consent was signed by parents of all enrolled participants after explanation of the research purpose, and ethical committee approved the study.

### Study participants

Children with traumatic mandibular fractures and unerupted mandibular teeth appeared on panoramic examination who were prepared to undergo OR/IF were included in this study. Inclusion criteria were age less than 12 years, mandibular fracture, and presence of unerupted mandibular teeth appearing on panoramic examination. Exclusion criteria were pathological fracture; condylar, subcondylar, or angle mandibular fractures; associated other maxillofacial fractures; and history of pretrauma malocclusion.

Under general anesthesia using nasal endotracheal intubation, all patients were treated by OR/IF using manual MMF without rigid MMF (no wires or arch bars) as previously described by Song *et al.* [3] and El-Anwar *et al.* [4]. The surgical team and the patient were wearing the protective lead apron.

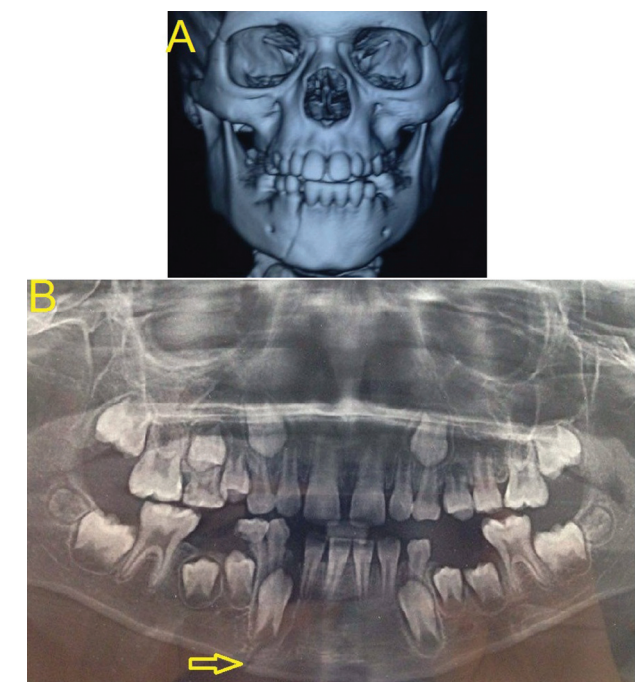
### Surgical work

Adrenaline, 1/200 000 concentration, was injected at the incision and dissection area. Through lower sublabial incision, exposure, dissection, disimpaction, and reduction of the fracture were performed while the mandible was opened. Then temporary intraoperative

manual MMF was performed by the assistant to get and maintain proper dental occlusion during IF. Titanium miniplate (usually 2.0 mm) was positioned with the expected holes of screws fixation fashioned according to preoperative radiology. Then C-arm images were taken to confirm the miniscrews (usually 7 mm length) position away from the nonerupted teeth. Then the plate and screws were readjusted till proper and safe position regarding tooth root and buds (Figs. 1 and 2) was obtained, avoiding screw insertion in plate hole near to tooth bud or using plate with space to bypass risky area. Lastly, screws were totally inserted at that safe position (Fig. 3). Care was taken during incision, dissection, and IF to avoid injury of mental nerve. The sublabial incision was then closed with immediate mobilization of the mandible.

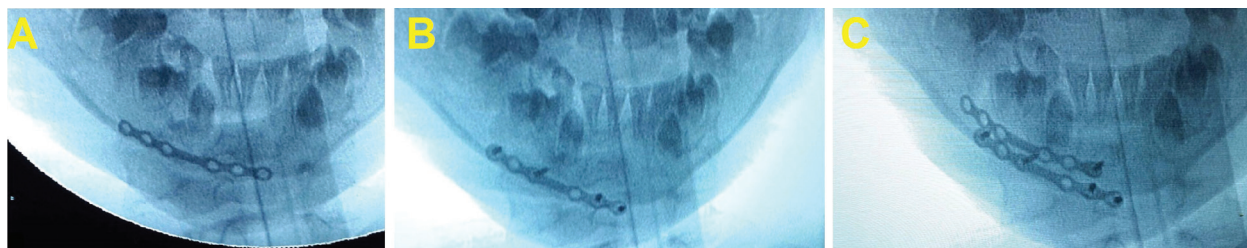
The intraoperative image was done with a mobile C-arm (Radius R-9; AFG, Grassobbio BG, Italy). C-arm was used by an extraoral approach for the mandibular fracture related to the teeth. The patient was lying in the supine position with head up and extended neck to clear the mandible of the cervical spine. The C-arm was positioned, so the radiographic tube was below the operative table facing the back of the patient head (Fig. 3). The image intensifier (X-ray sensor) was placed as close as possible to the patient in

Figure 1



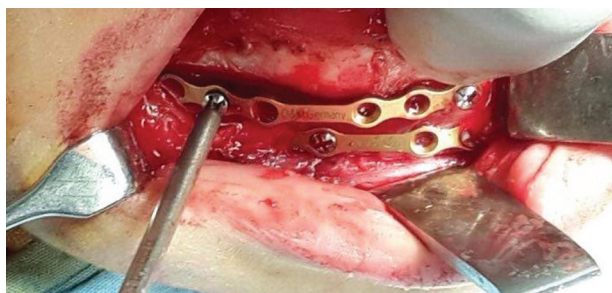
(a) Preoperative three-dimensional computed tomography scan displaying a parasymphyseal fracture. (b) Preoperative orthopantomograph demonstrates the parasymphyseal fracture (arrow) with multiple nearby teeth roots and unerupted teeth.

Figure 2



Intraoperative C-arm images. (a) First plate position at lower border of the mandible confirmed to be safe. (b) After screw fixation in the first plate, determining space available for the second plate. (c) Ensure proper position of the second plate with safe expected screws sites.

Figure 3



Screws were totally inserted at the C-arm-determined safe position avoiding screw insertion in plate hole near to tooth bud and using plate with space to bypass risky area.

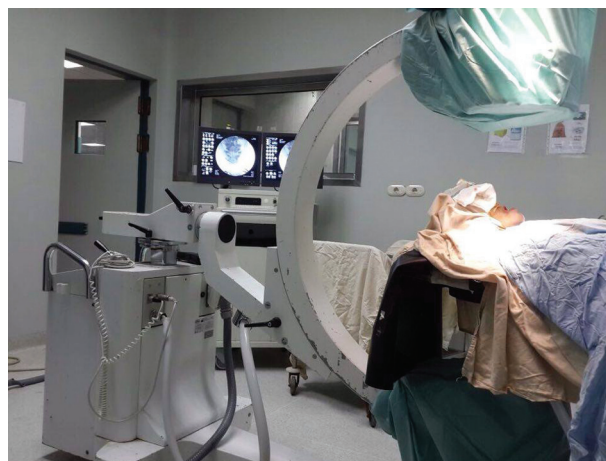the external surface of cheek. However, the X-ray source was kept as far as possible from the patient to help to reduce the entrance surface dose to the patient and the magnification of the image.

Mainly posteroanterior view (parietoacanthial) with cephalad angulation was done to all patients. The Skull's sagittal plane was rotated about  $15^\circ$  contralateral to the X-ray axis. In general, the rotation of the head was in an oblique direction (the degree of obliquity depends upon the section of mandible that is of interest), and the beam angles were  $20 \pm 10^\circ$  in coronal plane (Fig. 4). The intraoperative image was obtained using pulse acquisition (dose 55–60 kV, 2–2.5 mA).

No difficulties were detected during intraoperative C-arm application regarding positioning or projection, and the registered views were clearly seen and easily interpreted. All patients had eventless recovery from general anesthesia. In all cases, postoperative radiology over the 6 months between OR/IF and plate removal confirmed the proper position of fixed screws away for the teeth bud or root.

For their part, the postoperative radiographic controls for the patients were taken within 24 h after surgery with conventional radiographic equipment (dose 70–75 kV, 10 mAs).

Figure 4



C-arm application by an extraoral approach while the patient was lying in the supine position under general anesthesia during open reduction and internal fixation.

Postoperative follow-up was done every week for 1 month, and then at 3 and 6 months postoperatively with monitoring of complications and functional results. Panoramic view of the mandible was done 6 months postoperatively, and at that time, plate was removed. Results were assessed according to the following criteria:

- (1) Reliability and difficulties of the procedure.
- (2) Angle's classification of dental occlusion.
- (3) The average intrinsic vertical mouth opening (between the upper and lower central incisors) [2,4,5]:
- (4) Normal: mouth opening measures 36–50 mm.
- (5) Functional: mouth opening measures 25–35 mm.
- (6) Limited: mouth opening measures 10–24 mm.
- (7) Operative duration.
- (8) Complications.

#### Statistical analysis

Statistical analyses were performed using SPSS 14.0 statistical software for Windows (SPSS Inc., Chicago, Illinois, USA). The significance level was set at *P* value less than 0.05.

## Results

A total of 20 patients were included in the study group, with 13 (65%) male and seven (35%) female patients, and their mean age was  $6.5 \pm 1.235$  years. The site of the mandibular fracture was parasymphyseal fracture in all cases.

Postoperatively, pretrauma dental occlusion was achieved in all cases. Regarding mouth opening, 1 week after surgery, it was normal in 16 (80%) patients and it was functional in four (20%) patients. Eight weeks postoperatively, all patients gained normal mouth opening.

Actual operative work duration was  $22 \pm 11$  min, whereas the mean total operative duration, including duration of the operative use of the C-arm, was  $29 \pm 12$  min with no significant difference ( $t=1.923$ ,  $P=0.62$ ). Thus, addition of C-arm did not significantly elongate the operative time.

Infection, hematoma, malocclusion, delayed union, and nonunion were not encountered. No intraoperative or postoperative anesthesia problems were detected. Postoperatively, oral analgesic was sufficient to control pain in all patients and was prescribed for 1 week.

## Discussion

The basic principle of fracture treatment is reduction, fixation, immobilization, prevention of infection, and rehabilitation, with the least disability and smallest risk for the patient [3,4]. The simplest and easiest treatment should be chosen whenever it is as effective as more invasive one [9].

Today, OR/IF is the standard management technique for displaced fractures. OR/IF of fracture mandible provides stable reconstruction, promotes bone healing, and shortens treatment time [8], allowing immediate jaw mobility [10]. However, OR/IF of mandibular fracture in children carries considerable risk to nonerupted teeth and tooth root, and this pushes many surgeons to closed reduction with MMF [8] in spite its many negative sequels and difficulties [2]. Additionally, it should be noted that when a child is in the deciduous dentition phase, standard intermaxillary fixation is difficult owing to tooth shape [11,12]. If teeth molds are used for MMF, the patient requires general anesthesia for making the molds, which then have to be fashioned into a lingual splint. Placement of the splint then typically requires a second anesthesia, and a third for splint removal [13] with increasing risk of ankylosis particularly in case of concomitant

condylar process fractures as immobilization continues for more than 1 week [13].

In fractures that do not involve bone or tooth loss, it is believed and preferable to simply plate the inferior border of the mandible [13]. However, such single basal plate is not fully effective from the biomechanical point of view and contradicts Champy's principles. Thus, double plating is recommended in such parasymphyseal fractures. But the development of dentition is one of the main concerns while managing pediatric mandibular fractures owing to the presence of multiple tooth buds throughout the substance of the mandible [14]. Thus, management of pediatric mandibular fractures is still a challenge.

Manual temporary intraoperative MMF (3MF) during OR/IF of selected cases of mandibular fractures was successfully used [3,4], allowing more rapid and less complex procedure limited to the mandible. In current study, we treat mandibular fracture in children by OR/IF using 3MF.

C-arm is a widely available and reliable equipment. Although C-arm fluoroscopy is routinely used in the repair of orthopedic fractures, its use in the maxillofacial region has been scarcely reported [10] and was not previously reported in pediatric mandibular fracture.

In the current study, C-arm-assisted IF of pediatric mandibular fracture allows proper fixation of plates and screws safely away from the permanent tooth buds, and this was proved by the postoperative radiology. Moreover, pretrauma dental occlusion and normal mouth opening could be achieved in all cases with no reported complication.

In the current study, operative C-arm guide represents an important advance in management of fracture mandible in children because, it allows safe use of its treatment of choice of OR/IF and avoids the important concerns about OR/IF of pediatric mandibular fracture. C-arm does emit radiation; using this radiographic technique, only low-dose nonfluoroscopic views are used, and the reductions can be completed with no more than five images. Thus, the accumulated dose is ultimately considerably less than what is emitted by a maxillofacial computed tomography scan [15]. Therefore, C-arm is safe with low emission levels, and it gives easily reproducible images and table information without a time lag. Moreover, the used C-arm machine in our study is equipped with automatic tube current modulation technology. This technology of radiation dose management is a very effective way of reducing radiation dose while maintaining image quality.

Based on the result obtained from this study, it is obvious that C-arm-guided plate and screws fixations in pediatric fracture add a real-time assessment on fractured areas and relation of inserted screws to tooth root and buds, and so add the ability of immediate, easy, same-time plate and screws position corrections during the operation without the need for reintervention.

Added operative duration by prepared C-arm was nonsignificant. Moreover, this obviates the need for rigid MMF and second intervention for its removal needed for closed technique or time for preparing used acrylic molds. As we used titanium miniplates and screws so it will need to be removed later. Thus our approach using C-arm guide for safe OR/IF in pediatric mandibular fracture is needed to be investigated using bioresorbable plating system plates without need to remove [16].

To the best of our knowledge, this is the first work that highlights the reliability and results of using C-arm as a guide tool intraoperatively to identify the roots of nonerupted teeth in cases of pediatric mandibular fracture to eliminate the risk of their damage during placement of plates and screw. Thus, the current work safely opens the door for increase trends toward more accurate OR/IF of fractured mandible in children. In addition, this study provides a basis for future wider use of C-arm as a guide intraoperative tool during repair of maxillofacial fracture.

## Conclusion

Operative C-arm-guided plate screws positioning and fixation can effectively obviate the risk of injury to tooth root or bud during OR/IF of mandibular fracture in children, allowing confirming safety and so popularity of OR/IF of such fracture.

## Financial support and sponsorship

Nil.

## Conflicts of interest

There are no conflicts of interest.

## References

- Bhagol A, Goel M, Ghandhi S. Supplemental maxillomandibular fixation with miniplateosteosynthesis: required or not? *Oral Maxillofac Surg* 2011; 15:27–30.
- Gallagher C, Gallagher V, Whelton H, Cronin M. The normal range of mouth opening in an Irish population. *J Oral Rehab*. 2004; 31:110–116.
- Song SW, Burm JS, Yang WY, Kang SY. Microplate fixation without maxillomandibular fixation in double mandibular fractures. *Arch Craniofac Surg* 2014; 15:53–58.
- El-Anwar MW, Sayed El-Ahl MA, Amer HS. Open reduction and internal fixation of mandibular fracture without rigid maxillomandibular fixation. *Int Arch Otorhinolaryngol* 2015; 19:314–318.
- El-Anwar MW, Hegab A. Internal fixation of single mandibular fracture under mandibular nerve block. *Oral Maxillofac Surg* 2016; 20:57–61.
- Patrick CP, Kaufman Y, Izaddoost S, Hatef DA, Hollier L. Principles of pediatric mandibular fracture management. *Plast Reconstr Surg* 2009; 123:1022–1024.
- Schneider M, Erasmus F, Gerlach KL, Kuhlisch E, Loukota RA, Rasse M, *et al*. Open reduction and internal fixation versus closed treatment and mandibulomaxillary fixation of fracture of the mandible condylar process: a randomized, prospective, multicenter study with special evaluation of fracture level. *J Oral Maxillofac Surg* 2008; 66:2537–2544.
- Smartt JM, Jlow DW, Bartlett SP. The pediatric mandible: II. Management of traumatic injury or fracture. *Plast Reconstr Surg* 2005; 116:28.
- Hang RH, Assael LA. Outcomes of open versus closed treatment of mandibular subcondylar fractures. *J Oral Maxillofac Surg* 2001; 59: 370.
- Van Hout WM, van Cann EM, Muradin MS, Frank MH, Koole R. Intraoperative imaging for the repair of zygomaticomaxillary complex fractures: a comprehensive review of the literature. *J Craniomaxillofac Surg* 2014; 42:1918–1923.
- Demianczuk AN, Verchere C, Phillips JH. The effect on facial growth of pediatric mandibular fractures. *J Craniofac Surg* 1999; 10:323.
- Schweinfurth JM, Koltai PJ. Pediatric mandibular fractures. *Facial Plast Surg* 1998; 14:31.
- Cole P, Kaufman Y. Principles of pediatric mandibular fracture management. *Plast Reconstr Surg* 2009; 123:1022–1024.
- Ferreira PC, Amarante JM, Silva PN, Rodrigues JM, Choupina MP, Silva AC, *et al*. Retrospective study of 1251 maxillofacial fractures in children and adolescents. *Plast Reconstr Surg* 2005; 115:1500.
- Czerwinski M. C-arm assisted zygoma fracture repair: a critical analysis of the first 20 cases. *J Oral Maxillofac Surg* 2015; 73:692E1–692E8.
- Singh M, Singh RK, Passi D, Aggarwal M, Kaur G. Management of pediatric mandibular fractures using bioresorbable plating system – efficacy, stability, and clinical outcomes: our experiences and literature review. *J Oral Biol Craniofac Res* 2016; 6:101–106.