

Saddle nose deformity: pathological grading and anatomical reconstruction

Amr N. Rabie, Ahmed Gamal

Department of Otorhinolaryngology, Ain Shams University, Cairo, Egypt

Correspondence to Amr N. Rabie, MD, Department of Otorhinolaryngology, Ain Shams University, 13 Gesr El Suez Street, Heliopolis, Cairo, Egypt. Tel: +20 122 746 1182; e-mail: arabie@live.com

Received 2 May 2016

Accepted 5 May 2016

The Egyptian Journal of Otolaryngology
2017, 33:31–36

Importance

Management of saddle nose deformity needs to be directed toward diagnosing its etiology and its treatment.

Objective

The aim of this study was to propose a simple classification system for saddle nose deformity that depends on pathologic grading and anatomic reconstruction.

Setting

This study was conducted at a university-affiliated tertiary hospital.

Study design

The study design was a retrospective chart review.

Patients and methods

Patients with saddle nose deformity presenting from 2012 to 2014 were reviewed. The patients were classified according to the septal condition as follows: grade 1, saddle nose due to pathology other than septal collapse (dorsum over-resection, familial, or racial); grade 2, septum is collapsed but can be fixed by means of bone grafts or septal replacement grafts; and grade 3, patients need cartilaginous septum reconstruction.

Results

The study included 32 patients, 20 female and 12 male, with a mean age of 27 years. Eleven cases were of grade 1 and were managed with dorsal grafts (septal cartilage in two, conchal cartilage in two, and diced cartilage in fascia in seven cases). Sixteen cases were of grade 2, and all were post-traumatic primary cases. Bone grafts to straighten and stabilize the broken septum were used in 13 cases, and septal replacement grafts were used in three cases. Five cases were of grade 3 and required replacement of septal L-strut that was concealed with diced cartilage in fascia. Columellar strut was used in all cases.

Conclusion

Diagnosis and management of saddle nose deformity should depend on identifying the etiology of each case and classifying them into cases due to correctable septal pathology that can be managed with straightening the septum, or those due to missing septum that need septal reconstruction, and those due to low dorsum without septal pathology that can be simply corrected with dorsal grafts. Using this anatomical approach we are trying to achieve a strong esthetic pleasing functioning nose.

Keywords:

diced cartilage, diced cartilage in fascia, rhinoplasty, saddle nose, septum reconstruction

Egypt J Otolaryngol 33:31–36

© 2017 The Egyptian Journal of Otolaryngology
1012-5574

Introduction

Managing saddle nose deformity is among the most demanding deformities in rhinoplasty surgery. The hallmark of this deformity is loss of septal support with collapse of the upper lateral cartilage and nasal bone septal complex with contraction of the skin soft tissue envelope and mucosal lining, leading to a deficiency of the middle nasal vault that impairs internal nasal valve function [1]. The acute columellar–labial angle, the collapsed lower and upper nasal cartilages, and the widened septum may contribute to compromised nasal functions in cases of saddle nose deformity [2]. The etiology of saddle nose has changed over the years; infectious and toxic causes

have become less frequent, whereas trauma and surgery are now representing the main causes of this deformity [3].

Most articles on saddle nose focused on esthetic improvement using different materials and techniques of dorsal-only grafts, comparing the advantages and disadvantages of each technique, and neglected the reconstruction of the nasal septum to

This is an open access article distributed under the terms of the Creative Commons Attribution-NonCommercial-ShareAlike 3.0 License, which allows others to remix, tweak, and build upon the work noncommercially, as long as the author is credited and the new creations are licensed under the identical terms.

improve airway [4–6]. Recently, some authors highlighted the importance of septal reconstruction as an integrated part of saddle nose management, as the main feature of saddle deformity is loss of septal support, leading to functional and esthetic sequelae that need to be addressed not simply by camouflaging the dorsum defect [2,7,8].

Daniel [8], introduced the term septal saddle nose deformity and discussed the composite reconstruction, in which the deep structural layer should be strong enough to hold the superficial esthetic layer is usually comprised of dorsal diced cartilage in fascia (DCF) and columellar strut to support and stabilize the nasal base and project the tip above the dorsal line.

We believe that management of the saddle nose should be directed toward fixing the cause of the problem and not only its consequences. As the etiology of the saddle deformity is usually due to loss of septal support, supporting the collapsed septum or rebuilding the septum caudal and dorsal L-strut is the pivotal step in the success of managing saddle nose deformities. Unfortunately, this is not a simple maneuver and is very demanding. Hence, we thought that straightening and supporting the nasal septum in cases of septal fractures in which the cause of saddle nose is septal collapse will elongate the septum and may decrease or obviate the need for dorsal graft.

The purpose of this study was to grade and classify saddle nose deformity in a simplified surgically oriented manner and to describe our technique in the management of each grade.

Patients and methods

This was a retrospective study that is approved by the Ain Shams Faculty of Medicine Ethics Committee. All the patients signed an informed consent.

The charts and photographs of patients suffering from saddle nose deformity during the period between 2010 and 2014 were reviewed.

All patients were subjected to full ENT history and examination, including endoscopic nasal examination. Standard preoperative and postoperative photographs in six views (frontal, basal, right lateral and oblique, and left lateral and oblique) were taken. Surgical notes were reviewed. Postoperative satisfaction of patients was recorded.

Grading and surgical management

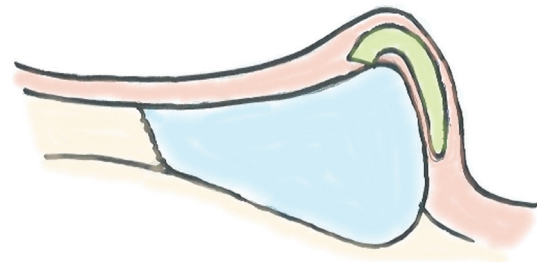
Grade 1

These patients present with depression of the nasal dorsum (bony and/or cartilaginous) (Fig. 1) without significant septal abnormality and are usually congenital, racial, or familial, or secondary to rhinoplasty with overzealous resection of cartilaginous/bony vault. These patients have a strong septum that can reliably hold grafts and are managed with dorsal grafts and columellar strut (Fig. 2). In our series it was made of DCF.

Grade 2

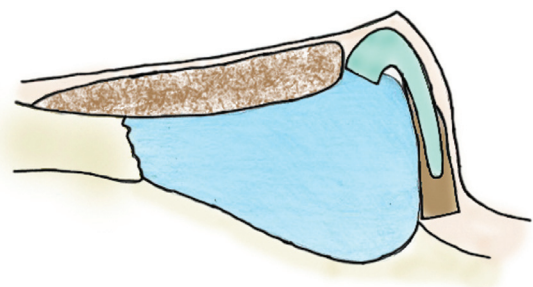
These patients present with minimal-to-moderate cartilaginous dorsum deficiency with or without deviation and are mostly traumatic in origin. The septum is usually broken, collapsed, and deviated (Fig. 3), causing dorsal saddling and deviation. The septum can be fixed mainly by straightening the septum with bone grafts (Figs. 4 and 5) and rigidly fixing the septum to a drill hole in the anterior nasal spine to have a straight septum in the mid line to which the upper lateral cartilages are reattached in a higher central position. In cases in which the septal fractures are complex and difficult to be splinted, a septal replacement graft can be used from a straight part of the cartilaginous septum that is usually available in

Figure 1



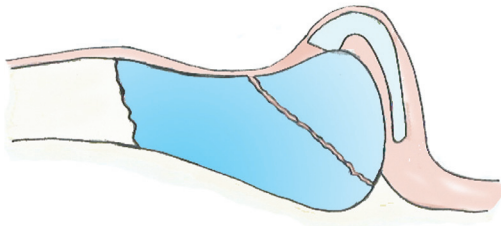
Grade 1, saddle nose due to low cartilaginous and bony dorsum without septal pathology.

Figure 2



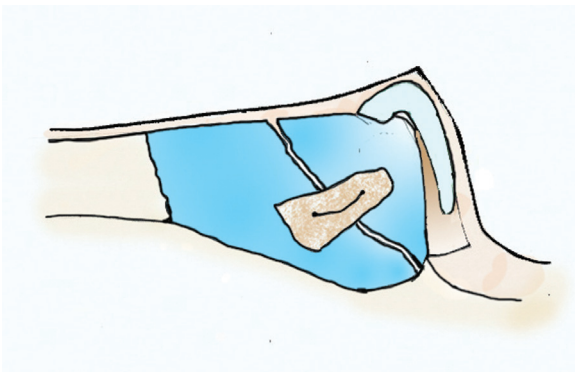
Diced cartilage in fascia and columellar strut for grade 1 cases.

Figure 3



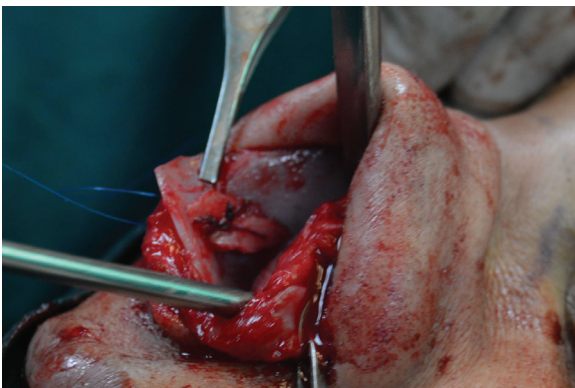Grade 2 saddle nose due to fractured collapsed septum.

Figure 4



Drawing illustrating bone graft splinting septal fracture.

Figure 5



Bone graft to splint septal fracture.

primary cases, and usually they need columellar strut too.

Grade 3

These patients present with moderate-to-severe cartilaginous with or without bony dorsum deficiency with or without deviation, and are mostly iatrogenic following submucous resection of the nasal septum with excessive cartilage resection with or without previous rhinoplasty. The septal dorsal and caudal L-strut were

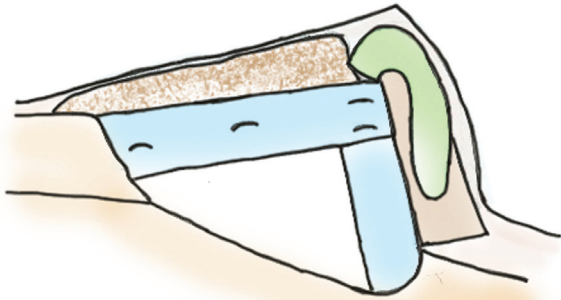
deficient. These cases need reconstruction of the septal L-strut. This is performed first by inserting two spreader grafts that are fixed to the septal remnants and to a septal strut that replaces the caudal part of the septum L-strut. One of the spreader grafts is cut long and is fixed to the side of the upper part of the septal strut, and the other is cut short just posterior to the septal strut to act as a backstop for the strut. These grafts are usually carved from costal cartilages that are cut in slices from the sixth or seventh rib. They are usually 2 mm in thickness and the width is that of the octal cartilage and the length according to the need (Figs. 6–8). These slices of costal cartilage were left in 200 ml of normal saline with 1 g of ceftriaxone and 80 mg gentamicine for about an hour before being used so that those slices that have tendency to warp will appear and are diced and only those that stay straight are used as solid grafts. A broad columellar strut is usually required to help in managing columellar retraction that is usually present in these cases. This is followed by insertion of DCF to gain some dorsal height as needed and to cover and camouflage any dorsal irregularities to give the patient smooth natural-looking dorsum.

In all grades, the nasal base needed to be stabilized with columellar strut. After completion of the reconstruction, the columellar incision is closed by means of single suture to inspect the dorsum and the tip carefully, and if more dorsal elevation is required a layer of cartilage can be added.

Results

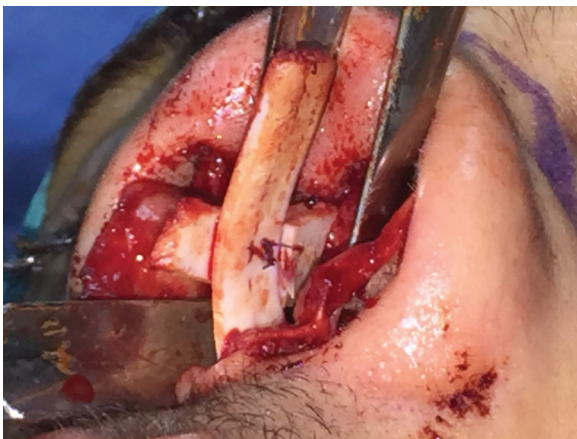The study included 32 patients, 20 female and 12 male, with a mean age of 27 years (range: 18–42 years). Follow-up was at least 12 months. Eleven cases were of grade 1; five were primary, and seven were revision cases. Dorsal grafts were used to treat those patients as the septum was not collapsed. Septal cartilage was used in two of them, conchal cartilage in two, and DCF (conchal cartilage in temporalis fascia) in seven cases (Fig. 9). Sixteen were of grade 2, and all were post-traumatic primary cases. Bone grafts to straighten and stabilize the broken septum were used in 13 cases, one graft in nine cases and two grafts in four cases. Septal replacement grafts were used in three cases whose septum was severely fractured in multiple areas beyond repair with one or two bone grafts, and hence we opted to use septal replacement graft as an easier and stronger way to correct such weak and fragmented septa. Six cases were of grade 2 and also required a cartilaginous dorsal graft. Five cases were of grade 3 and required replacement of septal L-strut with slices of costal cartilage followed by DCF layer

Figure 6



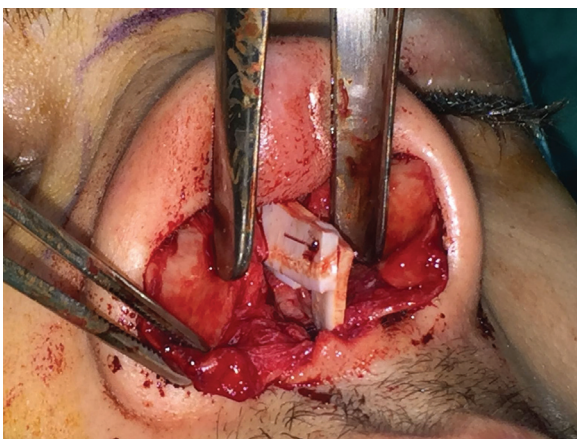Composite septal reconstruction, reconstruction of the deep septal L-strut, and diced cartilage in fascia for the dorsum and columellar septal strut.

Figure 7



Septal L-strut reconstruction fixed before trimming excess cartilage.

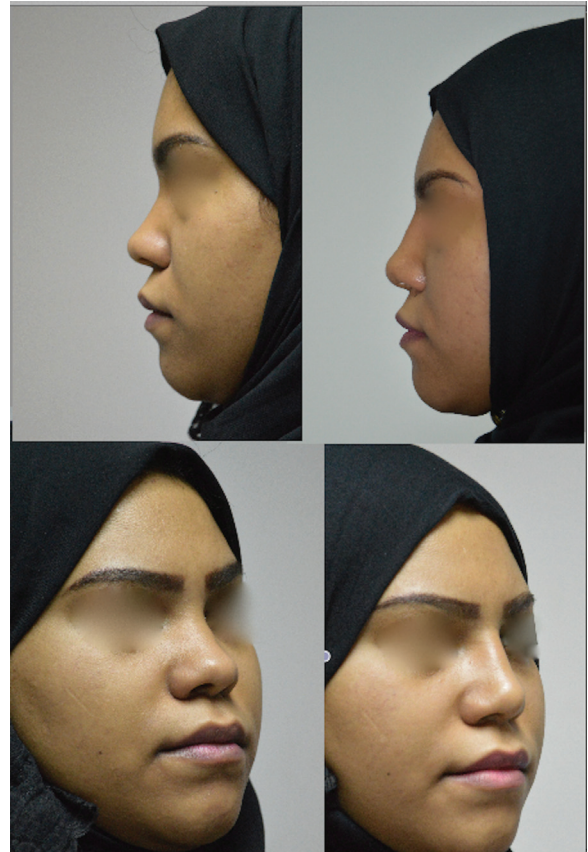Figure 8



Septal L-strut reconstruction fixed after trimming excess cartilage.

(Fig. 10); four were revision cases and one case had near-total cartilaginous septal loss secondary to septal abscess. In all cases the nasal base needed to be stabilized with columellar strut and to get the tip

Figure 9



Grade 1 case preoperative and postoperative photographs. Surgical steps included diced cartilage in fascia, columellar strut, medial and lateral osteotomies, transdomal, interdomal and tip positioning sutures, and alar flare and nasal base reduction.

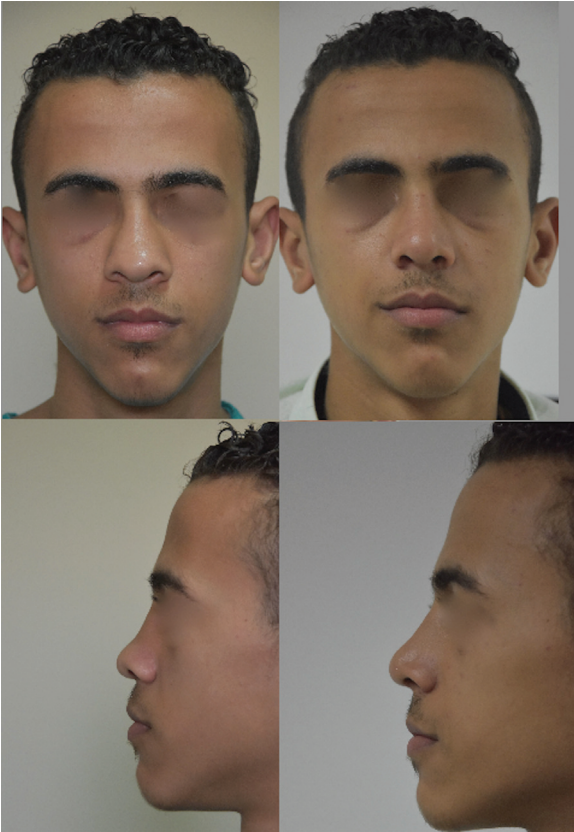above the dorsal line. All patients were satisfied, and none required revision.

Discussion

The management of saddle nose has changed a lot in the recent years, from just dorsal camouflaging that does not address the septal or the internal nasal valve problems to reconstruction and correcting the nasal septum so that nasal shape and function could be restored [2,3,7-9].

Daniel and Brenner [9] introduced a new classification depending mainly on septal support that was determined by means of the septal support test in which the patient presses on the tip of his or her nose to see if the lobule is going to collapse against the upper lip. The classification was as follows: type 0 (pseudosaddle), cartilaginous dorsum depression due to over-resection in a previous rhinoplasty, which can be managed with dorsal grafts; type 1 (minor), reduced but stationary septal support and can be managed with cosmetic concealment; type 2 (moderate), septal compromise and cartilaginous dorsum collapse and may be managed with extended

Figure 10



Grade 3 case preoperative and postoperative photographs. This patient had near-total cartilaginous septal loss due to septal abscess, and surgical steps included reconstruction of the septal L-strut with slices of costal cartilage, diced cartilage in fascia and columellar strut, medial and lateral osteotomies, transdomal, interdomal and tip positioning sutures, and alar flare and nasal base reduction.

vault grafts fixed to a columellar strut; type 3 (major), complete loss of septal support and needs composite reconstruction with deep foundation layer of spreader grafts and septal strut concealed with esthetic contour layer of DCF and columellar strut (That is what we did to grade 3 cases in our series.); type 4 (severe), cases that require structural reconstruction with structural cantilevered dorsal graft attached to a strong columellar graft; and type 5 (catastrophic), requires nasal reconstruction and many require forehead flap [9]. We found that this classification is a bit complex with unclear demarcation between types 3 and 4. Daniel [8], recently, performed composite reconstruction in most of the cases as it is a flexible technique with low risk, as warping is not an issue as the structure grafts are hidden by the superficial DCF contour layer. In our series, composite reconstruction was performed for all grade 3 cases with loss of septal support, but we did not have cases requiring nasal reconstruction.

Durbec and Disant [3] proposed a classification of the various stages of saddle nose deformity and they adapted the management to each stage: stage 1,

minimal depression of the supratip area due to loss of septal support, but septal material is available, and managed with extracorporeal septoplasty with spreader grafts; stage 2, moderate depression but less than 5 mm and accompanied by decreased projection, and are corrected with multilayer dorsal conchal graft and the nasal base is projected with columellar strut; stage 3, major loss of bony and cartilaginous dorsal support and managed with dorsal L-shaped costal cartilage graft in a mortise and tenon joint design, inserted through the endonasal or sublial approach. This staging system depends mainly on the availability of the cartilage. It does not address correcting the septal structure except in stage 1. However, in other stages in which the septum anatomy is moderately or markedly shortened disturbed, they opted to dorsal camouflaging in stage 2 and dorsal and caudal in stage 3, unlike our grading system in which we opted to dorsal camouflaging only in grade 1 when the pathology is only low dorsum. However, in grades 2 and 3 when the pathogenesis of the saddle is due to loss of septal support we addressed the septum mainly to achieve structural and functional correction.

Cakmak *et al.*[7] claimed that re-establishing septal height and support and connecting the dorsum septum and the upper lateral cartilage in higher level will lead to functional improvements by correcting internal nasal valve angles, whereas dorsal-only or cantilever grafts placed on the dorsum will further depress the middle vault and may further impair nasal breathing. They proposed an algorithm to address the saddle nose deformity by camouflaging only minimal cases and restoring high middle vault, by repositioning septal cartilage. Utilizing a wide columellar strut, the L-strut septal graft is fixed to septal remnants or to the bone when the nasal bone projection is good, and in case of loss of nasal bone projection a cantilever graft sitting on the radix and articulating with wide columellar graft is used. This algorithm is very informative; however, it is a bit complex and may be difficult to follow. Our grading system is simple and easy to use and focuses mainly on the septal condition: straight, strong, and does not need to be fixed, grade 1; broken, deviated, and collapsed but can be fixed by means of simple maneuvers as bone grafts or septal replacement grafts, grade 2; or needs to be reconstructed, grade 3.

The DCF has revolutionized the management of saddle nose deformity, with a simplified technique that can be used to manage challenging cases of partial or full dorsum grafting. It is superior to solid cartilage grafts with no risk or warping, edge visibility, malalignment, and K-wire extrusion. Histologic

studies of DCF showed viable cartilage cells and normal metabolic activity with coalescence of the diced cartilage into a single mass that survived completely [4,10,11].

Foda [12] proposed the use of bone grafts to rigidly correct septal deviations. In grade 2 cases, we opted to straighten the septum and to re-establish septal support mainly through the use of bone grafts.

In the management of saddle nose deformity, we believe the septum is a pivotal factor. Therefore, we grade the patients and tailor our surgical technique depending on the septum condition. Our proposed grading system is surgically oriented and focuses on the condition of the septum: dorsal on-lay grafting was performed when the septum is strong straight and needs no intervention (grade 1); deviated and broken and needs to be re-enforced and straightened by bone grafts (grade 2); or missing due to previous overzealous excision and needs to be reconstructed to re-establish the deep foundation layer made of dorsal spreader grafts fixed to the septal remnant and septal strut fixed to the anterior nasal spine; and superficial cosmetic layer of DCF and columellar strut (grade 3). In all grades, any dorsal irregularities can be filled with crushed cartilage or only grafts. Nasal base stabilization required a strong columellar strut to position the tip above the dorsal line was always used.

Conclusion

The diagnosis and management of saddle nose deformity should depend on identifying the etiology of each case, and classifying them into cases due to correctable septal pathology that can be managed with straightening the septum, or those due to missing septum that needs septal reconstruction and those

due to low dorsum without septal pathology that can be simply corrected with dorsal grafts. We believe that using this approach we are trying to get the nose to its natural anatomy in order to look and function normal.

Financial support and sponsorship

Nil.

Conflicts of interest

There are no conflicts of interest.

References

- 1 Kim DW, Toriumi DM. Management of post traumatic nasal deformities: the crooked nose and the saddle nose. *Facial Plast Surg Clin North Am* 2004; 12:111–132.
- 2 Riechelmann H, Rettinger G. Three-step reconstruction of complex saddle nose deformities. *Arch Otolaryngol Head Neck Surg* 2004; 130:334–338.
- 3 Durbec M, Disant F. Saddle nose: classification and therapeutic management. *Eur Ann Otorhinolaryngol Head Neck Dis* 2014; 131:99–106.
- 4 Eren F, Öksüz S, Melikoglu C, Karagöz H, Ülkür E. Saddle-nose deformity repair with microplate-adapted costal cartilage. *Aesthetic Plast Surg* 2014; 38:733–741.
- 5 Erol OO. The Turkish delight: a pliable graft for rhinoplasty. *Plast Reconstr Surg* 2000; 105:2229–2241.
- 6 Celik M, Haliloglu T, Bayçin N. Bone chips and diced cartilage: an anatomically adopted graft for the nasal dorsum. *Aesthetic Plast Surg* 2004; 28:8–12.
- 7 Cakmak O, Emre IE, Ozkurt FE. Identifying septal support reconstructions for saddle nose deformity: the Cakmak algorithm. *JAMA Facial Plast Surg* 2015; 17:433–439.
- 8 Daniel RK. Rhinoplasty: septal saddle nose deformity and composite reconstruction. *Plast Reconstr Surg* 2007; 119:1029–1043.
- 9 Daniel RK, Brenner KA. Saddle nose deformity: a new classification and treatment. *Facial Plast Surg Clin North Am* 2006; 14:301–312 vi.
- 10 Daniel R. The role of diced cartilage grafts in rhinoplasty. *Aesthet Surg J* 2006; 26:209–213.
- 11 Daniel R, Calvert J. Diced cartilage grafts in rhinoplasty surgery. *Plast Reconstr Surg* 2004; 113:2156–2171.
- 12 Foda HM. The role of septal surgery in management of the deviated nose. *Plast Reconstr Surg* 2005; 115:406–415.
- 13 Young K, Rowe-Jones J. Current approaches to septal saddle nose reconstruction using autografts. *Curr Opin Otolaryngol Head Neck Surg* 2011; 19:276–282.