

Immunologic changes after diode laser inferior turbinoplasty in allergic rhinitis

Hazem M.A. Saleh^a, Dalia R. Ibrahim^b, Michael I. Michael^b, Amal M. Kamal^b, Ahmed M. El-Kharbotly^a, Mervate M. Bahgat^b

^aOtolaryngology Unit, National Institute of Laser Enhanced Sciences, Cairo University, Giza,

^bDepartment of Radiobiological Applications, Clinical Pathology Unit, Nuclear Research Center, Atomic Energy Authority, Egypt

Correspondence to Dr Hazem Saleh, 10, El Messaha Square, Apt. 1401, 12311 Giza, Egypt Tel & Fax: +20 237 482 838; e-mail: hazemsalehnils@yahoo.com

Received 1 September 2015

Accepted 15 October 2015

The Egyptian Journal of Otolaryngology 2016, 32:141–146

Objectives

It was suggested previously that turbinoplasty by laser improves the symptomatology of allergic rhinitis (AR) not only by a mechanical effect but also by inhibiting the local allergic reaction at the level of the inferior turbinates. The aim of this study was to determine whether the short-term immunologic effects of diode laser, when used to perform inferior turbinoplasty in AR, can also be detected at the systemic level.

Patients and methods

Twenty patients, seeking a treatment by laser for AR manifestations refractory to local and systemic medical therapy, were included in a prospective study. Blood picture, total immunoglobulin E, interleukin (IL)-4, IL-5, and interferon- γ levels were assessed immediately before and 1 month after diode laser inferior turbinoplasty (DLIT).

Results

One month after DLIT, the total leukocytic count increased with relative eosinopenia. Total immunoglobulin E and IL-5 decreased, together with insignificant changes in IL-4 and interferon- γ .

Conclusion

It is not impossible that DLIT modifies the clinical course of AR not only by a mechanical effect but also by its local or even by a systemic immunologic effect. The laser modulation of T-cell functions in the engorged turbinate submucosa is a plausible biomolecular interpretation of the observed effect.

Keywords:

cytokines; hematology; immunology; inferior turbinates; interleukins; reduction; semiconductor

Egypt J Otolaryngol 32:141–146

© 2016 The Egyptian Journal of Otolaryngology

1012-5574

Introduction

Allergic rhinitis (AR) is, by definition, an inflammatory reaction at the level of the nasal mucosa. However, it is specifically marked by complex interactions between the different inflammatory mediators that finally trigger an allergic immunoglobulin E (IgE) reaction [1–3]. With more than 600 million sufferers, AR is the most prevalent allergic disorder worldwide [1,4,5]. This global health problem is worsened by its seriously increasing incidence rate [6].

Many AR patients present with nasal obstruction secondary to congestive hypertrophy of the inferior turbinates [7–9]. Fibrosis in addition to chronic congestion of the inferior turbinates makes medical therapy insufficient, opening the door for the surgical reduction of the hypertrophied turbinates [9,10] by various techniques.

Pioneering workers popularized the use of laser in the reduction of the hypertrophied inferior turbinates [11,12]. Compared with conventional procedures, laser provides

limited tissue trauma, less bleeding, and high patient acceptance, especially in outpatient facilities [13].

Kawamura *et al.* [14], Lippert and Werner [12], and Fukutake *et al.* [15] reported that 78, 87.5, and 93.5% of patients achieved subjective excellent or good results after inferior turbinates reduction by carbon dioxide (CO₂) laser, respectively. Takeno *et al.* [16] and Furukido *et al.* [17] also reported a significant decrease in symptom scores after inferior turbinates reduction by CO₂ laser. Siegel *et al.* [18] concluded that nearly half of the patients (44.4%) could stop their medications after CO₂ laser turbinoplasty. Tsai *et al.* [19] and Caffier *et al.* [1] reported that the nasal symptoms improved significantly after diode laser inferior turbinoplasty (DLIT). Tsai *et al.* [19] reported that DLIT is effective in improving health-related quality of life in patients with AR for at least 6 years after treatment.

This is an open access article distributed under the terms of the Creative Commons Attribution-NonCommercial-ShareAlike 3.0 License, which allows others to remix, tweak, and build upon the work noncommercially, as long as the author is credited and the new creations are licensed under the identical terms.

In the nose, the allergic reaction can be inhibited by modifying the local environment of the superficial mucosal layer [20,21] and hence modifying the immunologic response. Two subsets of T-helper (Th) cells are responsible for the regulation of cellular and humoral immunities [22]: Th1 cells, which produce IL-2, interferon (IFN)- γ , and lymphotoxin, and Th2 cells, which produce interleukin (IL)-4, IL-5, IL-6, and IL-10. Imbalance between Th1 and Th2 cells toward an increased Th2 activity, either in the nose or elsewhere, is associated with an increased allergic risk [23].

It was suggested previously that laser turbinoplasty improves the clinical symptoms in AR not only by its mechanical effect but also by inhibiting the allergic reaction at the level of the inferior turbinates mucosa [23]. In our study, we explored whether the effect of DLIT, performed in AR patients, can be translated into some systemic hematologic and immunologic variables, namely, IgE, IL-4, IL-5, and IFN- γ in peripheral blood. Blood picture and assessment of the above-mentioned variables were performed on venous samples collected immediately before and 1 month after DLIT.

Patients and methods

Fifty-three adult patients, complaining of bilateral or alternating nasal obstruction, sought management at the Otorhinolaryngology Outpatient Clinic at the National Institute of Laser, Cairo University, Egypt. Their symptoms were refractory to maximal doses of local steroids, local, and systemic antihistamines. After an assessment of the complete medical history and anterior rhinoscopy, patients with previous nasal surgery or immunotherapy, recurrent epistaxis, symptoms, or signs suggestive of vasomotor rhinitis or sinonasal polyposis were excluded. The radioallergosorbent test was used to identify those with AR. Finally, 20 patients with confirmed AR who were offered the option to undergo a DLIT agreed to be enrolled in this prospective cohort study. They underwent a nasal endoscopic examination using 4 mm 0° Hopkins telescopes (Karl Storz, Tubingen, Germany) to confirm the presence of hypertrophy of the inferior turbinates and to exclude nasal polyposis. All the endoscopic examinations and DLITs were performed by the first author (HS). Patients were instructed to stop any local or systemic steroids or antihistamines 2 weeks before DLIT. They received a detailed explanation of the study and of the DLIT procedure before providing a formal consent.

All procedures performed in this study were in accordance with the ethical standards of the Institutional and National Research Committee and with the 1964 Helsinki Declaration and its later amendments or comparable ethical standards.

Diode laser inferior turbinoplasty

Before laser application, and after obtaining two blood samples from each patient to determine the baseline of his/her hematologic and immunologic variables, we topically anesthetized the inferior turbinates by packing the inferior meatus with cotton pads soaked in Lidocaine solution (Xylocaine 10%; AztraZeneca UK Horizon Place, 600 Capability Green, Luton, Bedfordshire, LU1 3LU) mixed with Xylometazoline HCL 0.1% (Otrivin; Novartis Pharma, Cairo, Egypt). We used a semiconductor diode laser (Quanta System, Italy) adjusted to the following laser parameters: wavelength=980 nm, continuous-wave, and output power=5–7W. We applied the laser under videoendoscopic guidance to the inferior turbinates in a contact submucosal mode by a soft bending, plastic-clad silica fiber (600 μ m core diameter) for 5–10 min. The laser fiber was introduced into the body of the turbinate through a small burn/hole in the turbinate head. The laser firing took place while introducing and while withdrawing the fiber from the turbinate body. The postoperative care protocol consisted of decongestive nasal drops for 5 days for hemostatic purposes, followed by saline irrigations for 2 weeks. No other topical or systemic treatments were prescribed. Patients were scheduled for two follow-up visits: the first 1 week after DLIT and the second 1 month after DLIT. During the second visit, blood samples were collected to evaluate the hematologic and immunologic changes.

Laboratory tests

Two peripheral venous samples were obtained from each patient: one immediately before DLIT and the other on the second follow-up visit 1 month later. Complete blood picture was performed using a Coulter apparatus (Micro 60-ABX: HORIBA Medical 9755 Research Drive Irvine California CA 92618 USA). Total IgE, IL-4, IL-5, and IFN- γ were determined using the enzyme-linked immunosorbent assay technique with a Stat Fax Reader.

Statistical analysis

The results of the hematologic and immunologic variables were evaluated statistically by a third party not involved in or attending the DLIT. Data were represented in tables as mean \pm SE and percentage of

change. The paired Student *t*-test was used for the analysis of the mean values. Correlation coefficient analysis was also carried out, when necessary, to evaluate the relations between the tested parameters before and after diode laser turbinoplasty.

Results

The cohort included 20 patients, 11 men and nine women. Their ages ranged from 28 to 37 years (mean=32 years). They had a positive radioallergosorbent test score of 2 or more for Dermatophagoides Farinae and Dermatophagoides Pteronyssinus (IgE level>0.70IU/ml). The mean time for DLIT was 8min (range, 5–12 min), whereas the total energy applied for each nasal turbinate ranged from 900 to 2600J (mean=1650J). DLIT was uneventful in all 20 patients; no major or minor complication requiring medical attention was observed. Postoperative packing was never required.

Laboratory tests

Hematologic changes

Erythroid parameters showed insignificant changes 1 month after DLIT, indicating a negligible effect of DLIT on the erythroid system. The platelet count also showed insignificant changes (Table 1 and Fig. 1).

Table 1 Statistical analysis of RBCs count, Hb level, Hct%, MCV, MCH, MCHC values, and platelet count before and after DLIT

Parameters	Groups (N=20)	
	Pre-DLIT	Post-DLIT
RBCs (million/mm ³)		
X±SE	4.14±0.12	4.18±0.11
% of change		1
Hb (g/dl)		
X±SE	11.9±0.12	11.96±0.09
% of change		1
Hct (%)		
X±SE	35.7±0.52	36.02±0.94
% of change		1
MCV (fl)		
X±SE	87.16	91.5
% of change		8
MCH (pg)		
X±SE	29.14	28.84
% of change		1
MCHC (g/dl)		
X±SE	33.41	31.54
% of change		-6
Platelet count(thousands/mm ³)		
X±SE	294.6±8.52	268±10.9
% of change		-6

DLIT, diode laser inferior turbinoplasty; Hb, hemoglobin; Hct, hematocrit; MCV, mean corpuscular volume; MCH, mean corpuscular hemoglobin; MCHC, mean corpuscular hemoglobin concentration; RBC, red blood cells.

After DLIT, the absolute total leukocytic count, eosinophils, staff, segmented, lymphocyte, and monocyte counts were within normal ranges. Nevertheless, highly significant changes were apparent in all parameters once the preoperative and postoperative values were compared. DLIT was followed by a sharp significant increase (*P*<0.001) in absolute total leukocytic count, staff, segmented, and lymphocytic counts (36, 268, 42, and 35%, respectively) relative to their pre-DLIT values, whereas the monocytic count showed insignificant changes. In contrast, eosinophils showed a marked, significant decrease (*P*<0.001) compared with the pre-DLIT counts (-96%) (Table 2 and Fig. 2).

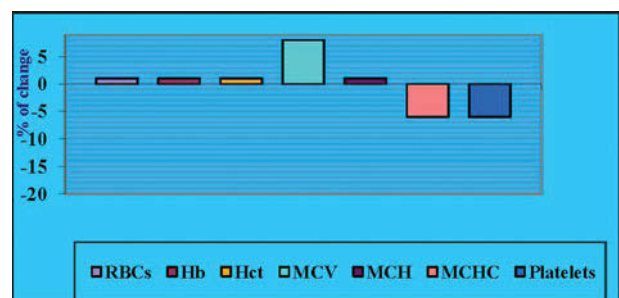
Immunologic changes

The immunologic parameters showed a highly significant decrease in IgE (-45%) and IL-5 (-63%) levels after DLIT together with insignificant changes in IL-4 and IFN-γ levels (Table 3 and Fig. 3).

The correlation coefficient test showed considerable significance after DLIT as follows:

There was a positive correlation between the erythroid parameter levels and platelet count postoperatively. The same positive significant correlation outcome was also found for the total and differential leukocytes 1 month after DLIT, except for the lymphocytes, which showed a negative significant correlation. Eosinophils showed a significant negative correlation with IL-4, IL-5, and IFN-γ before DLIT. After DLIT, eosinophils showed a negative correlation with IgE and a positive correlation with IFN-γ. Similarly, other significant correlations were obtained between every immunological parameter and the other parameters either before or after DLIT as follows: IgE level showed a significant negative correlation with IL-5

Figure 1



Percentage of change in red blood cells count, hemoglobin level, hematocrit value, and platelet count after DLIT. DLIT, diode laser inferior turbinoplasty.

Table 2 Statistical analysis of absolute numbers of the total leukocytic count, eosinophils, staff, segmented, lymphocytes, and monocyte count before and after DLIT

Parameters	Groups (N=20)	
	Pre-DLIT	Post-DLIT
TLC (thousands/mm ³)		
X±SE	5460±197.78	7400±267.96
% of change		36
Eosinophils		
X±SE	157±14.44	58±5.93
% of change		-96
Staff		
X±SE	44±16.3	162±35.1
% of change		268
Segmented		
X±SE	2726±96.11	3871±186.3
% of change		42
Lymphocytes		
X±SE	2144±121.11	2891±179.44***
% of change		35
Monocytes		
X±SE	388±3944	403±52.03
% of change		4

DLIT, diode laser inferior turbinoplasty; TLC, total leukocytic count. Statistically significant changes after DLIT.

***P < 0.001.

Table 3 Statistical analysis of IgE, IL-4, IL-5, and IFN-γ values before and after DLIT

Parameters	Groups (N=20)	
	Pre-DLIT	Post-DLIT
IgE (IU/ml)		
X±SE	838.89±109.33	478.75±50.39**
% of change		-43
IL-4 (pg/ml)		
X±SE	6.72±1.69	5.17±0.81
% of change		-23
IL-5 (pg/ml)		
X±SE	26.11±6.44	9.63±1.89*
% of change		-63
IFN-γ (pg/ml)		
X±SE	27.4±3.52	28.88±3.23
% of change		12

DLIT, diode laser inferior turbinoplasty; IFN, interferon; IgE, immunoglobulin E; IL, interleukin.

Statistically significant changes after DLIT.

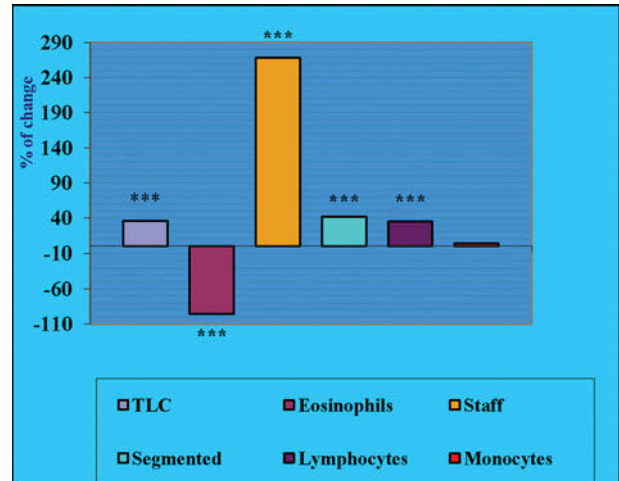
*P < 0.05.

**P < 0.01.

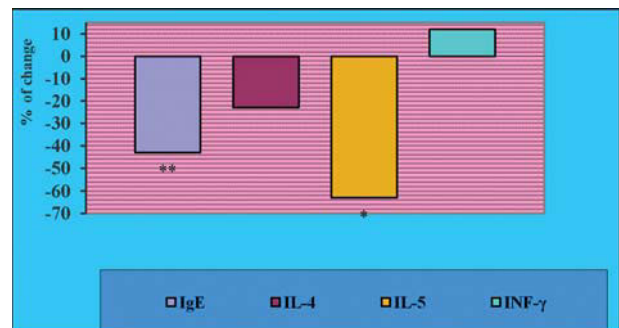
before DLIT. After DLIT, the IgE level was negatively correlated with IL-5 and IFN-γ. IL-4 showed a positive correlation with IFN-γ both before and after DLIT. IL-5 showed a significant positive correlation with IFN-γ both before and after DLIT.

Discussion

In the field of treatment of AR, laser surgery aims primarily to reduce the size of hypertrophied inferior

Figure 2

Percentage of change TLC, eosinophils, staff, segmented, lymphocytes, and monocyte counts after DLIT. DLIT, diode laser inferior turbinoplasty; TLC, total leukocytic count.

Figure 3

Percentage of change of IgE, IL-4, IL-5, and IFN-γ values after DLIT. DLIT, diode laser inferior turbinoplasty; IFN, interferon; IgE, immunoglobulin; IL, interleukin; TLC, total leukocytic count.

turbinates. However, it was suggested that laser turbinoplasty improves the clinical symptoms in this condition not only by its mechanical effect but also by the impact on allergic parameters resulting from decreasing the volume of the inferior turbinates [23]. In the present study, we explored a further effect of DLIT, performed in AR patients, that is on the blood picture and on the levels of IgE, IL-4, IL-5, and IFN-γ in the systemic circulation.

Our technique of submucosal diode laser fiber application under videoendoscopic guidance targets the inferior mucosal layers showing the greatest thickening and the superficial zone of the lamina propria infiltrated with inflammatory cells. These areas are suitable for reduction because they are rich in venous sinusoids; their excision alleviates the excessive congestion and obstruction. As they are

poor in glandular elements, their excision does not increase the probability of nasal dryness. Finally, these areas lack any major artery and their excision does not increase the likelihood of perioperative hemorrhage [24]. It is not impossible that targeting this area, rich in white blood cells, is responsible for the amplification of the immunologic changes to the extent of becoming detectable systemically, that is, in the peripheral venous circulation.

We did not observe any significant effect on the erythroid parameters. This may be because of the fact that the life span of red blood cells is 120 days. The insignificant decrease in the platelet number after turbinoplasty may reflect a redistribution process; DLIT is a sort of injury or trauma where platelets are rapidly deployed [25–27].

Among the tested differential leukocytic counts, we observed a significant increase in the lymphocytic and neutrophilic counts after DLIT. This may be because of the stimulation of the regenerative processes. In fact, *in-vitro* studies have shown that the application of low-level laser irradiation at different energy densities stimulates proliferation, increases growth factors' secretion *in vitro*, and facilitates myogenic differentiation of bone marrow-derived mesenchymal stem cells [28].

The eosinophils were the only cells that showed a significant decrease. The changes in nasal homeostasis by DLIT modified the systemic and possibly the local expression of IL-5, on which the activation of eosinophils is closely dependent. Also, the statistical decrease in total IgE and IL-5 and the decrease and increase in IL-4 and IFN- γ , respectively, although insignificant, may indicate an improvement in the individual allergic state and coincides with the decrease in the eosinophilic count after DLIT. This is in agreement with Furukido *et al.* [17], who examined the changes in the cytological profile of nasal mucosa after the use of a CO₂ laser. They found a significant decrease in eosinophilic infiltration after CO₂ laser surgery, where the infiltrations of both total eosinophils and activated eosinophils were decreased to less than half their baseline values.

Allergic disorders including AR are known to be Th2 specific IgE-dependent immune diseases, where the shift in the Th1/Th2 balance is toward the Th2 dominant state. In our study, the levels of Th1 type cytokines such as IFN- γ were lower in AR patients before DLIT than after surgery, although the changes

were not statistically significant. However, the levels of Th2 type cytokines such as IL-4 and IL-5 were higher in AR patients before DLIT than after the surgery. These results suggest that DLIT modulates the T-cell function and tilts the Th1/Th2 balance toward a Th1 dominant state locally, and this local effect appears to be significant enough to be reflected on the systemic circulation. The decrease in the eosinophilic count and in the IgE levels were the consequences of this shift. Our results were in agreement to some extent with Mori *et al.*[23], who reported that there was a significant decrease in specific IgE levels in the sera of AR patients after KTP laser therapy ($P < 0.05$). They also showed that the levels of IFN- γ produced by post-KTP surgery peripheral blood mononuclear cells (collected from the AR patients after surgery) after stimulation with staphylococcus enterotoxin B *in vitro* were higher than those produced by peripheral blood mononuclear cells collected before the surgery; however, the difference was not statistically significant. They found no difference in IL-4 levels produced by peripheral blood mononuclear cells after KTP laser therapy. The discrepancy from our results may be because of the fact that we measured the level of IL-4 in the sera of AR patients *in vivo* before and after DLIT, whereas Mori *et al.*[23] measured the IL-4 produced by peripheral blood mononuclear cells (collected from the AR patients) after stimulation with staphylococcus enterotoxin B *in vitro* before and after KTP laser surgery.

No previous studies, to our knowledge, have addressed the peripheral immunologic role of inferior turbinoplasty. The results obtained from this preliminary uncontrolled study paves an avenue for further investigations. The absence of a negative control in our study was because of ethical issues and the absence of a positive control was mainly because our patients sought care or were referred to our institute for treatment with laser therapy. Further work should be carried out on larger cohorts, with controls subjected to non-laser inferior turbinoplasty. Longer follow-up periods are also recommended to detect whether the reversion of the immunologic effects coincides with the symptomatic recurrence of AR.

Conclusion

In the short term, DLIT seems to have an immune effect that modulated T-cell function and tilts the Th1/Th2 balance toward a Th1 dominant state. This effect can be detected in the systemic circulation and is a plausible interpretation of the positive effect of DLIT on symptoms of AR.

Conflicts of interest

There are no conflicts of interest.

References

- 1 Caffier PP, Scherer H, Neumann K, Luck S, Enzmann H, Haisch A. Diode laser treatment in therapy-resistant allergic rhinitis: impact on nasal obstruction and associated symptoms. *Lasers Med Sci* 2011;26: 57–67.
- 2 Ibiapina Cda C, Sarinho ES, Camargos PA, Andrade CR, Cruz Filho AA. Allergic rhinitis: epidemiological aspects, diagnosis and treatment. *J Bras Pneumol* 2008;34:230–240.
- 3 Mullol J, Bachert C, Bousquet J. Management of persistent allergic rhinitis: evidence-based treatment with levocetirizine. *Ther Clin Risk Manag* 2005;1:265–271.
- 4 Mullol J, Valero A, Alobid I *et al.* Allergic rhinitis. *J Investig Allergol Clin Immunol* 2008;18:327–334.
- 5 Meltzer EO, Blaiss MS, Derebery M *et al.* Burden of allergic rhinitis: results from the Pediatric Allergies in America survey. *J Allergy Clin Immunol* 2009;124:S43–S70.
- 6 Settipane RA, Charnock DR. Epidemiology of rhinitis: allergic and nonallergic. *Clin Allergy Immunol* 2007;19:23–34.
- 7 Farmer SE, Eccles R. Chronic inferior turbinate enlargement and the implications for surgical intervention. *Rhinology* 2006;44:234–238.
- 8 Leong SC, Eccles R. Inferior turbinate surgery and nasal airflow: evidence-based management. *Curr Opin Otolaryngol Head Neck Surg* 2010; 18:54–59.
- 9 Cassano M, Granieri C, Del Giudice AM, Mora F, Fiocca-Matthews E, Cassano P. Restoration of nasal cytology after endoscopic turbinoplasty versus laser-assisted turbinoplasty. *Am J Rhinol Allergy* 2010;24:310–314.
- 10 Passali D, Passali FM, Damiani V, Passali GC, Bellussi L. Treatment of inferior turbinate hypertrophy: a randomized clinical trial. *Ann Otol Rhinol Laryngol* 2003;112:683–688.
- 11 Lagerholm S, Harsten G, Emgard P, Olsson B. Laser-turbinectomy: long-term results. *J Laryngol Otol* 1999;113:529–531.
- 12 Lippert BM, Werner JA. CO₂ laser surgery of hypertrophied inferior turbinates. *Rhinology* 1997;35:33–36.
- 13 Janda P, Sroka R, Baumgartner R, Grevers G, Leunig A. Laser treatment of hyperplastic inferior nasal turbinates: a review. *Lasers Surg Med* 2001;28:404–413.
- 14 Kawamura S, Fukutake T, Kubo N, Yamashita T, Kumazawa T. Subjective results of laser surgery for allergic rhinitis. *Acta Otolaryngol Suppl* 1993;500:109–112.
- 15 Fukutake T, Yamashita T, Tomoda K, Kumazawa T. Laser surgery for allergic rhinitis. *Arch Otolaryngol Head Neck Surg* 1986;112: 1280–1282.
- 16 Takeno S, Osada R, Furukido K, Yajin K. Analysis of local cytokine gene expression in patients with allergic rhinitis treated with CO₂ laser surgery. *Laryngoscope* 2000;110:1968–1974.
- 17 Furukido K, Takeno S, Osada R, Ishino T, Yajin K. Study of eosinophil activation in nasal mucosa in patients with perennial nasal allergy: effects of CO₂ laser surgery. *Am J Rhinol* 2002;16:1–6.
- 18 Siegel GJ, Seiberling KA, Haines KG, Haines KG, Aguado AS. Office CO₂ laser turbinoplasty. *Ear Nose Throat J* 2008;87:386–390.
- 19 Tsai YL, Su CC, Lee HS, Chen HC, Chen MK. Symptoms treatment for allergic rhinitis using diode laser: results after 6-year follow-up. *Lasers Med Sci* 2009;24:230–233.
- 20 Elwany S, Abel Salaam S. Laser surgery for allergic rhinitis: the effect on seromucinous glands. *Otolaryngol Head Neck Surg* 1999;120: 742–744.
- 21 Inouye T, Tanabe T, Nakanoboh M, Ogura M. Laser surgery for allergic and hypertrophic rhinitis. *Ann Otol Rhinol Laryngol Suppl* 1999;180:3–19.
- 22 Mosmann TR, Sad S. The expanding universe of T-cell subsets: Th1, Th2 and more. *Immunol Today* 1996;17:138–146.
- 23 Mori K, Tamura M, Kawamoto M *et al.* Modulation of T-cell functions by laser surgery in patients with allergic rhinitis. *Acta Otolaryngol* 2003;123: 704–708.
- 24 Berger G, Ophir D. The histopathology of the hypertrophic inferior turbinate. *Arch Otolaryngol Head Neck Surg* 2006;132:588–594.
- 25 Wagner DD, Burger PC. Platelets in inflammation and thrombosis. *Arterioscler Thromb Vasc Biol* 2003;23:2131–2137.
- 26 Weyrich AS, Zimmerman GA. Platelets: signaling cells in the immune continuum. *Trends Immunol* 2004;25:489–495.
- 27 Iannaccone M, Sitia G, Isogawa M *et al.* Platelets mediate cytotoxic T lymphocyte-induced liver damage. *Nat Med* 2005;11:1167–1169.
- 28 Hou JF, Zhang H, Yuan X, Li J, Wei YJ, Hu SS. In vitro effects of low-level laser irradiation for bone marrow mesenchymal stem cells: proliferation, growth factors secretion and myogenic differentiation. *Lasers Surg Med* 2008;40:726–733.