

Unilateral submandibular gland agenesis associated with capillary hemangioma of the cartilaginous nasal septum

Janani Moorthy^a, Subramanian Ilanchezhian^b, Rajoo Ramachandran^a, Periasamy V. Prithiviraj^a

Departments of ^aRadiology, ^bPathology, Sri Ramachandra University, Chennai, Tamil Nadu, India

Correspondence to Janani Moorthy, MBBS, Department of Radiology, Sri Ramachandra University, Porur, Chennai 600116, Tamil Nadu, India
Tel: 04425531414;
e-mail: drjananimbbs@gmail.com

Received 08 June 2015

Accepted 31 July 2015

The Egyptian Journal of Otolaryngology
2016, 32:79–81

Congenital agenesis of the submandibular gland with compensatory hypertrophy of the contralateral gland is an extremely rare disorder and only few cases are reported in the literature. To our knowledge the reported cases of submandibular agenesis have been asymptomatic and associated with facial anomalies. In our study we present the imaging features of the right submandibular gland agenesis with associated capillary hemangioma of the cartilaginous nasal septum in a middle-aged man who presented with a right-sided nasal block.

Keywords:

agenesis, capillary hemangioma, submandibular gland

Egypt J Otolaryngol 32:79–81

© 2016 The Egyptian Oto - Rhino - Laryngological Society
1012-5574

Introduction

Congenital absence of submandibular gland is an infrequent disorder and is usually associated with contralateral submandibular gland hypertrophy [1,2]. Major salivary gland aplasia are seen in congenital disorders such as lacrimoauriculodentodigital syndrome, mandibulofascial dysostosis, and ectodermal dysplasia in association with dysplasia or aplasia of lacrimal or thyroid glands [3,4]. To the best of our knowledge, this is the first case of submandibular gland agenesis associated with capillary hemangioma of the cartilaginous nasal septum. In this case report we present the computed tomographic (CT) findings in a 48-year-old man with right submandibular gland agenesis associated with left side capillary hemangioma of the cartilaginous nasal septum.

Case report

A 48-year-old man came with complaints of left-sided nasal block for 1 month, without any history of pain, fever or of salivary hypofunction. On examination the patient had a nasal mass that had minimal bleeding on touch. The patient underwent nasal endoscopy, which showed polypoidal mass lesion in the anteroinferior nasal cavity. The patient then underwent contrast-enhanced CT of the paranasal sinus, which showed absent right submandibular gland with compensatory hypertrophy of the left submandibular gland (Fig. 1a–c). There was also a well-defined polypoidal mass lesion in the anteroinferior nasal cavity in close proximity with the cartilaginous nasal septum that showed intense and persistent contrast enhancement suggestive of capillary hemangioma (Fig. 2a–c). The patient was counseled and then his consent for the surgery was obtained. The

polypoidal mass lesion was surgically excised and sent for histopathological analysis. Histopathology detected thin-walled, small- and medium-sized capillaries lined by a single layer of endothelium with intervening fibrous stroma consistent with capillary hemangioma of the nasal septum (Fig. 3), thus confirming the radiological diagnosis.

Discussion

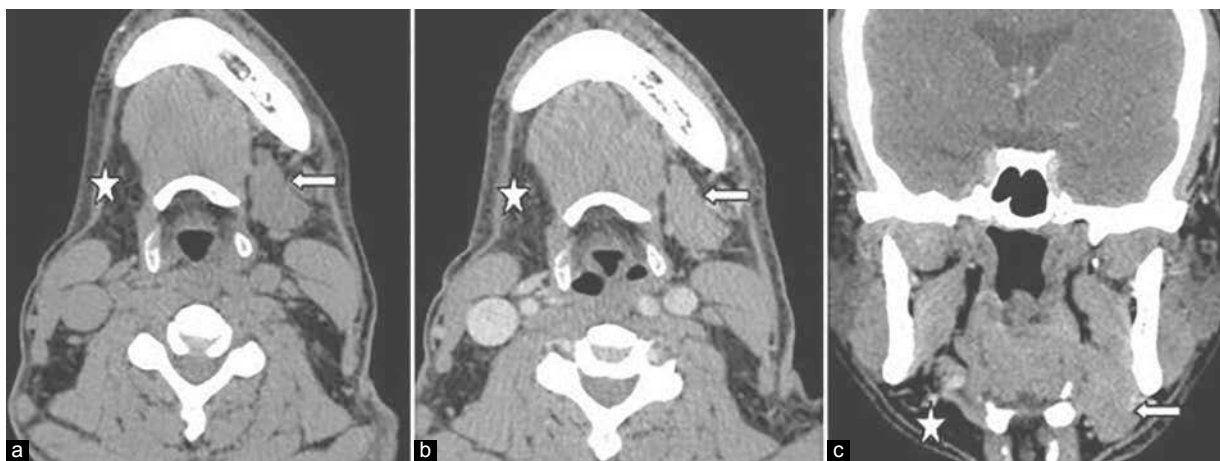
The major salivary glands sequentially develop between 4th and 12th week of the fetal development as solid epithelial buds from the primary oral cavity. These primordal buds grow and extend into the underlying mesenchymal tissue as solid core of cells, which then undergoes extensive branching and eventually develops into lumina. The submandibular gland arises at the 6th week of gestation [5,6].

Agenesis of the major salivary gland is a rare disorder. Although the etiology is unknown, it is thought to occur because of the defects that occur during early fetal development [6,7].

The clinical symptoms related to salivary gland agenesis are varied. In most of the cases dry mouth, difficulty in swallowing, and dental problems can be seen. But in our case there were no such symptoms. Absence of salivary gland may also be seen as part of the

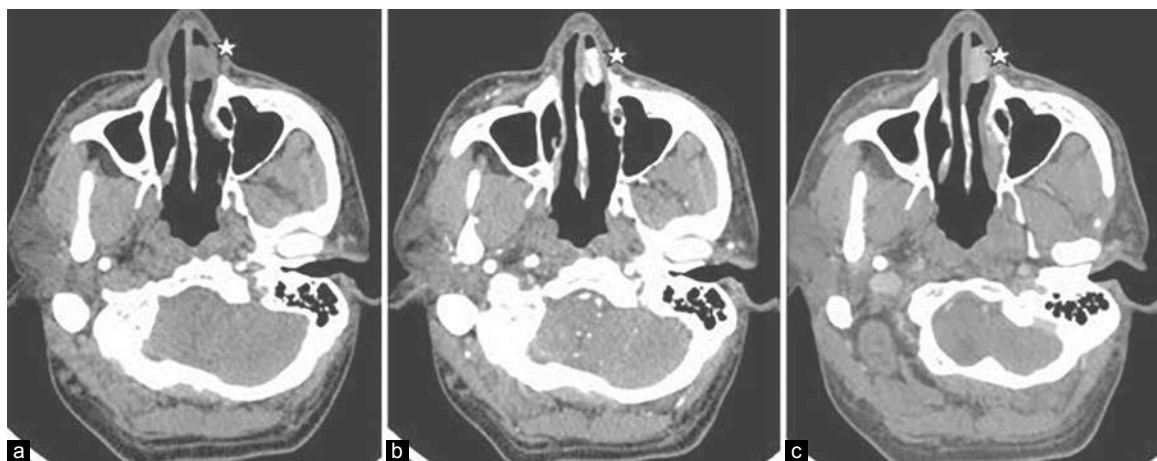
This is an open access article distributed under the terms of the Creative Commons Attribution-NonCommercial-ShareAlike 3.0 License, which allows others to remix, tweak, and build upon the work non-commercially, as long as the author is credited and the new creations are licensed under the identical terms.

Figure 1



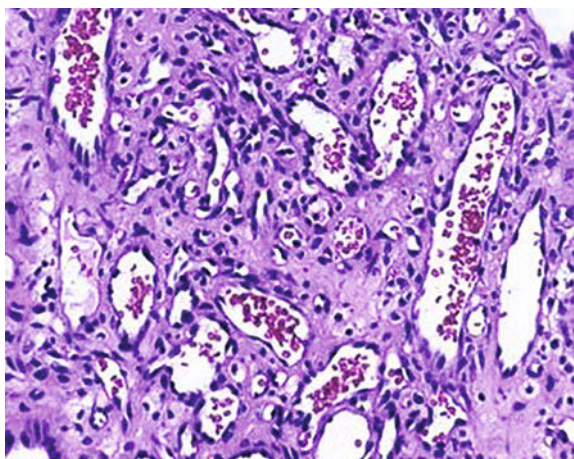
(a–c) Axial plain and contrast-enhanced computed tomographic images of the neck in venous phase with reformatted coronal images show absent right submandibular gland (star) with compensatory hypertrophy of the contralateral left submandibular gland (left arrow).

Figure 2



(a–c) Axial plain and contrast-enhanced computed tomographic images of the paranasal sinus in arterial and venous phase show a well-defined intensely enhancing polypoidal mass lesion involving the cartilaginous nasal septum (star).

Figure 3



Photomicrograph of hematoxylin and eosin (x200) stained sample of a nasal mass shows thin-walled small- and medium-sized capillaries lined by a single layer of endothelium with intervening fibrous stroma.

lacrimoauriculodentodigital syndrome, characterized by hypoplasia, aplasia, or atresia of the lacrimal system, deafness and ear malformations, and dental and digital anomalies [8]. There were no such anomalies present in our patient. The lack of salivary gland related symptoms was probably because of the secretions of the other salivary glands compensating for this.

Salivary gland aplasia can be diagnosed with a variety of imaging techniques that include ultrasonography, CT, MRI sialography or scintigraphy. In our patient we were able to confirm the diagnosis with the help of a CT scan. The characteristic imaging feature in CT is the nonvisualization of the submandibular gland, which is often replaced by fatty tissue, the margins of which are well defined with no signs of invasion of the adjacent soft tissue or bone and compensatory hypertrophy of the contralateral submandibular gland, as seen in our case.

Nasal lobular capillary hemangioma is a rare benign tumor of the paranasal sinuses. The most common location of lobular capillary hemangioma is the head and neck region. Nasal lobular capillary hemangioma occurs at all ages but is more commonly seen in middle-aged adults, with a slight predilection toward women than men [9,10]. In children nearly 76.9% of the cases occur in the gingiva, lips, and tongue and only few cases are seen in the nasal cavity [11,12].

Nasal lobular capillary hemangiomas usually arises from the nasal septum, predominantly from the little area and/or from the roof of the nasal cavity and turbinates or in the maxillary sinus [13].

The exact etiology of lobular capillary hemangioma is still unknown. Recurrent nose picking or nasal packing plays a significant role in the development of lobular capillary hemangioma resulting in excessive growth of the granulation tissue [10,12,14]. It is commonly found in pregnant women and in women on oral contraceptive pills, and its development has a strong association with trauma and hormonal influences [14]. Epistaxis and nasal obstruction are the most common symptoms of lobular capillary hemangioma.

On plain CT, nasal lobular capillary hemangioma appear as a well-defined soft-tissue mass that shows intense enhancement on post contrast study [15]. The differential diagnosis of capillary hemangioma is juvenile nasal angiofibroma, which are commonly seen in adolescent men. Other differential diagnoses are angiomatous polyp and some uncommon malignant lesions such as nasopharyngeal carcinoma or nasopharyngeal teratoma.

On MRI, these lesions have an intermediate signal on T1-weighted and heterogeneous signal with areas of flow void on T2-weighted sequences showing intense enhancement post gadolinium.

Angiography is useful for preoperative embolization as it significantly reduces the occurrence of bleeding during the operation.

The management of capillary hemangioma consists of preoperative embolization of the tumor followed by complete surgical resection of the mass as in our case. Nasal lobular capillary hemangioma associated with pregnancy may regress following childbirth. The lesions

that do not regress completely may require surgery and the patients are generally advised to follow-up.

Conclusion

Unilateral submandibular gland agenesis is an extremely rare disorder and its incidence is unknown. To the best of our knowledge this is the first case report of submandibular gland agenesis and capillary hemangioma of the nasal septum seen in the same patient. However, no established association has been mentioned so far.

Financial support and sponsorship

Nil.

Conflicts of interest

There are no conflicts of interest.

References

- Higashino H, Horii T, Ohkusa Y, Ohkuma H, Ino C, Nakazawa M, *et al.* Congenital absence of lacrimal puncta and of all major salivary glands: case report and literature review. *Clin Pediatr (Phila)* 1987; 26:366–368.
- Park SH, Sohn YM, Kim EK. Agenesis of a submandibular gland with compensatory pseudotumoral hypertrophy of the contralateral gland: sonographic findings. *J Clin Ultrasound* 2013; Suppl 1:15–17.
- Inan UU, Yilmaz MD, Demir Y, Degirmenci B, Ermis SS, Ozturk F. Characteristics of lacrimo-auriculo-dento-digital (LADD) syndrome: case report of a family and literature review. *Int J Pediatr Otorhinolaryngol* 2006; 70:1307–1314.
- Singh P, Warnakulasuriya S. Aplasia of submandibular salivary glands associated with ectodermal dysplasia. *J Oral Pathol Med* 2004; 33:634–636.
- Yilmaz MD, Yucel A, Derekoy S. Unilateral aplasia of the submandibular gland. *Eur Arch Otorhinolaryngol* 2002; 259:554–556.
- Srinivasan A, Moyer JS, Mukherji SK. Unilateral submandibular gland aplasia associated with ipsilateral sublingual gland hypertrophy. *Am J Neuroradiol* 2006; 27:2214–2216.
- Kubo S, Abe K, Ureshino T, Oka M. Aplasia of the submandibular gland. A case report. *J Craniomaxillofac Surg* 1990; 18:119–121.
- Hollister DW, Klein SH, De Jager HJ, Lachman RS, Rimoin DL. The lacrimo-auriculo-dento-digital syndrome. *J Pediatr* 1973; 83:438–444.
- Ozcan C, Apa DD, Görür K. Pediatric lobular capillary hemangioma of the nasal cavity. *Eur Arch Otorhinolaryngol* 2004; 261:449–451.
- Puxeddu R, Berlucchi M, Ledda GP, Parodo G, Farina D, Nicolai P. Lobular capillary hemangioma of the nasal cavity: a retrospective study on 40 patients. *Am J Rhinol* 2006; 20:480–484.
- Pagliai KA, Cohen BA. Pyogenic granuloma in children. *Pediatr Dermatol* 2004; 21:10–13.
- Patil P, Singla S, Mane R, Jagdeesh KS. Nasal lobular capillary hemangioma. *J Clin Imaging Sci* 2013; 3:40.
- Miller FR, D'Agostino MA, Schlack K. Lobular capillary hemangioma of the nasal cavity. *Otolaryngol Head Neck Surg* 1999; 120:783–784.
- Lee HM, Lee SH, Hwang SJ. A giant pyogenic granuloma in the nasal cavity caused by nasal packing. *Eur Arch Otorhinolaryngol* 2002; 259:231–233.
- Lee G, Suh K, Lee Y, Kang I. CT findings in two cases of lobular capillary haemangioma of the nasal cavity: focusing on the enhancement pattern. *Dentomaxillofac Radiol* 2012; 41:165–168.