

Severe esophageal damage caused by button battery ingestion in a 10-month-old infant

Savita Lasrado, Kuldeep Moras, George J.O. Pinto, Anita Aramani, Ayshwarya Vijayan

Department of Otorhinolaryngology and Head & Neck Surgery, Father Muller Medical College, Mangalore, Karnataka, India

Correspondence to Savita Lasrado, MS, DNB, Department of Otorhinolaryngology, Father Muller Medical College, Mangalore 575002, India
Tel: +91 994 536 1819; fax: +91 824 2436661; e-mail: savita_menezes@yahoo.com

Received 06 September 2014

Accepted 20 March 2015

The Egyptian Journal of Otolaryngology
2015, 31:204–206

Foreign body ingestion is commonly encountered in infants and young children. Button batteries represent a special category of pediatric ingested foreign bodies because of the serious possibility of complications when impacted in the esophagus. Herein we report a case of emergency medicine in a 10-month-old infant who accidentally ingested a button battery, causing severe esophageal damage. He presented with excessive crying and decreased oral intake. A chest radiograph revealed a coin shadow at the mid-esophagus, which subsequently led to the diagnosis and removal of the object. Postoperative treatment options such as antireflux therapy, antibiotic therapy, steroids, and esophageal stenting, which are still controversial, have been discussed in this paper. With increasing accessibility to electronic toys and gadgets, accidental ingestion is on the rise in infants and young children. Judicious management should be tailored in every case.

Keywords:

accident, button battery, emergency medicine, esophageal injury, foreign body

Egypt J Otolaryngol 31:204–206

© 2015 The Egyptian Oto - Rhino - Laryngological Society
1012-5574

Introduction

Ingestion of a button battery has been considered an emergency as it causes necrosis and perforation when impacted in the esophagus. This damage can begin as early as 24–48 h and hence necessitates special consideration. They are small, found in a variety of common household electronics, and can be easily swallowed. These batteries can contain manganese dioxide, zinc, silver oxide, mercuric oxide, or lithium. Lithium cells have the strongest current; they generate more hydroxide more rapidly compared with other types of cells, and thus lithium cells are associated with more morbidity and mortality compared with other button batteries. Here we present an interesting case report of a 10-month-old infant who had accidentally swallowed a battery 5 days ago and presented with excessive crying and decreased oral intake. Failing conventional therapy, a chest radiograph was taken, which led to the diagnosis and subsequent removal of the battery.

Case report

A 10-month-old infant presented to the pediatric outpatient department with a history of excessive crying and fever and decreased oral intake since the past 5 days. Clinical examination of the child was normal. The child was admitted and routine blood tests and ultrasonography of the abdomen did not reveal any gross abnormality. As the child continued to

have fever and excessive crying a chest radiograph was taken, which showed a coin shadow at the level of the mid-esophagus. The case was referred to us for further management.

Lateral neck radiograph showed that the radiopaque object was located posterior to the trachea and was noted to have a stepped-off silhouette; the anteroposterior view revealed that it could be a battery masquerading as a coin as it had a double-rimmed appearance (Fig. 1). Diagnosis of a button battery was made. The child was taken immediately for rigid esophagoscopy under general anesthesia. An impacted disc battery was found at the level of the mid-esophagus. Following removal, a check esophagoscopy revealed deep ulceration and focal charring in the mid-esophagus.

A Ryle's tube was passed under vision to prevent esophageal perforation. The Ryle's tube was placed to prevent stricture and also to facilitate feeding as the possibility of esophageal perforation was not ruled out. On removal the battery appeared to be corroded (Fig. 2). Postprocedural chest radiograph revealed clear lung fields, with no evidence of pneumothorax or pneumomediastinum. The child was not fed orally for 1 week and only Ryle's tube feeds were given. The child was started on antibiotics, amoxicillin and potassium clavulanate, steroids, dexamethasone 1 mg/kg, and systemic antacid therapy with a histamine H₂-receptor antagonist. After a week the child was allowed to take clear oral fluids, along with

Ryle's tube feeds. A gastrograffin swallow performed at the end of 2 weeks revealed no leak or strictures (Fig. 3). Dexamethasone at 1 mg/kg was continued for 4 weeks. The child was discharged in stable condition with Ryle's tube *in situ*. The tube was removed after 5 weeks as the child had no further complaints and was able to take normal oral feeds. Barium swallow performed at the end of 6 months did not show any strictures (Fig. 4).

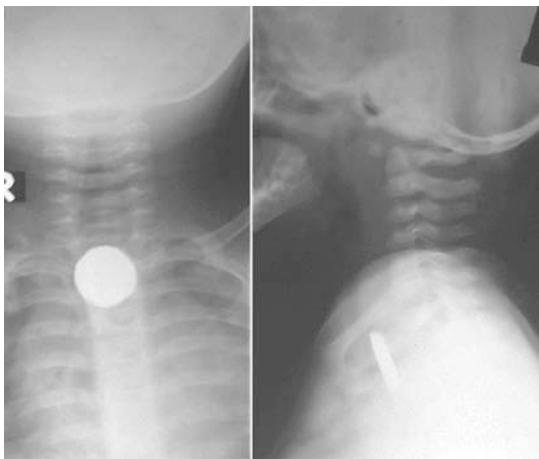
Discussion

Ingestion of button batteries by children must be treated as a medical emergency as they are corrosive. With increasing accessibility to electronic toys and gadgets, accidental ingestion is on the rise. Although small foreign bodies that are swallowed generally pass

down the gut without any problem, some foreign bodies can get lodged in the esophagus and cause trouble. Lodgment in the esophagus can lead to mucosal damage, and exposure to gastric acid causes leakage of cell contents. Significant damage may occur within a short period of time after ingestion of the battery. Maves *et al.* [1] observed mucosal damage as early as 1 h after oesophageal impaction in cats, progressing to transmural necrosis within 4 h.

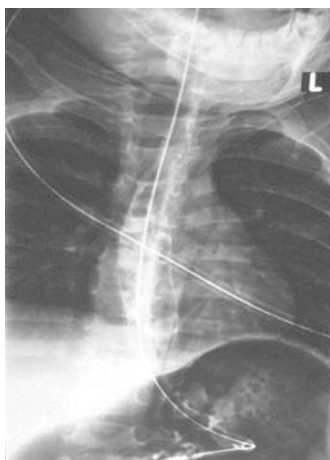
Ingested button batteries have been reported to cause esophageal stricture and perforation [2,3], vocal cord paralysis [4], and tracheoesophageal fistulas [5]. Esophageal lesions are particularly dangerous because of the proximity to major vessels and organs including the heart. On the basis of the chemical composition, five types of batteries are in common use: manganese, silver, mercury, lithium, and zinc. Button batteries are constructed

Figure 1




Anteroposterior and lateral chest radiographs of the patient showing radiopaque foreign body at the level of the mid-esophagus.

Figure 3



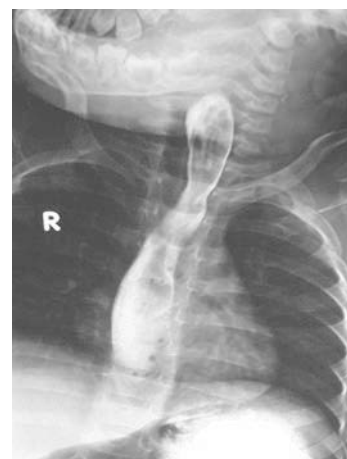Postprocedure gastrograffin swallow showing free flow of contrast with Ryle's tube *in situ*.

Figure 2



Battery after removal; note corroded battery.

Figure 4



Barium swallow at the end of 6 months, with no evidence of strictures.

of a zinc anode and a cathode made of either manganese, silver, or mercuric oxide, separated by a disc containing a strong alkali [6], contained within a steel case. Strong alkali solutions induce rapid liquefaction necrosis of tissue [7]. The battery cases are not biologically sealed and therefore leakage of alkali may occur in a fluid environment, such as the lumen of the esophagus [8].

All button batteries impacted in the esophagus should be removed immediately as the outcome is potentially disastrous. Prevention of esophageal perforation and/or stricture formation is the goal behind esophageal stenting following battery ingestion. Prevention of contact between opposite sides of a circumferentially raw esophageal surface prevents adherence and decreases stricture formation. Stenting can be done with nasogastric tubes or with specially designed silicon stents [9]. In the present case, there was focal charring involving the entire circumference, and hence a Ryle's tube was passed under vision to prevent perforation. In addition, nasogastric tubes can serve for feeding purposes when esophageal damage is extensive. However, blind nasogastric intubation may result in the perforation of the esophagus through damaged tissues.

Addition of steroids after battery removal is still controversial, and in the present case, as the infant had severe damage, steroids were added to prevent strictures and facilitate healing. Dexamethasone at 1 mg/kg was given for 4 weeks. Antibiotics to prevent infection and systemic antacid therapy with a histamine H₂-receptor antagonist to prevent reflux of gastric contents also play a role in rapid healing. In the present case report we have highlighted the role of steroids and Ryles's tube, which probably prevented stricture formation although the damage was extensive.

Conclusion

We have reported the case of emergency medicine related to a 10-month-old infant who accidentally ingested a button battery causing severe esophageal damage. With increasing accessibility to electronic toys and gadgets, accidental ingestion is on the rise. The packaging of new cells should be more secure, with clear labelling that draws the attention of parents to keep them away from children. The hazards of button battery ingestion should be publicized and prevention encouraged through parental education and safe disposal of used batteries. In conclusion, the authors herein present a case of button battery ingestion that caused focal ulceration and charring in the mid-esophagus. With judicious management, stricture formation was prevented in the present case.

Acknowledgements

Conflicts of interest

There are no conflicts of interest.

References

- 1 Maves MD, Carithers JS, Birk HG. Esophageal burns secondary to disc battery ingestion. *Ann Otol Rhinol Laryngol* 1984; 93(Pt 1):364–369.
- 2 Raboei EH, Syed SS, Maghrabi M, El Beely S. Management of button battery stricture in 22-day-old neonate. *Eur J Pediatr Surg* 2009; 19:130–131.
- 3 Yardeni D, Yardeni H, Coran AG, Golladay ES. Severe esophageal damage due to button battery ingestion: can it be prevented? *Pediatr Surg Int* 2004; 20:496–501.
- 4 Hamilton JM, Schraff SA, Notrica DM. Severe injuries from coin cell battery ingestions: two case reports. *J Pediatr Surg* 2009; 44:644–647.
- 5 Imamoglu M, Cay A, Kosucu P, *et al.* Acquired tracheo-esophageal fistulas caused by button battery lodged in the esophagus. *Pediatr Surg Int* 2004; 20:292–294.
- 6 Litovitz TL. Button battery ingestions: a review of 56 cases. *JAMA* 1983; 249:2495–2500.
- 7 Houck JC, De Angelo L, Jacob RA. The dermal chemical response to alkali injury. *Surgery* 1962; 51:503–507.
- 8 Votteler TP, Nask JC, Rutledge JC. The hazard of ingested alkaline disc batteries in children. *JAMA* 1983; 249:2504–2506.
- 9 Saleem MM. Acquired oesophageal strictures in children: emphasis on the use of string-guided dilatations. *Singapore Med J* 2009; 50:82–86.