

Tracheolith: a case report of a new disease entity

Hussain Albaharna, Aqeel Ahmad

Qatif Central Hospital, Eastern Province, Qatif, Saudi Arabia

Correspondence to Hussain Albaharna, MD, Qatif Central Hospital, Eastern Province, 32631-7074 Mahmod Wararq Street - 4568, Qatif, Saudi Arabia
Tel: +966504233099;
e-mail: h.albaharna@gmail.com

Received 04 July 2014

Accepted 26 August 2014

The Egyptian Journal of Otolaryngology
2015, 31:202–203

This case reports a stone in the trachea of a patient with tracheostomy. The presence of stone in the airway is uncommon condition. Broncholithiasis is characterized by formation of the stone due to erosion of calcified lymph node in the bronchus. There is no reported case of a stone in the trachea in the literature. The pathophysiology of this condition is still unknown, but we think that it is related to prolong tracheostomy. We recommend performing chest radiography in all cases of tracheostomy obstruction.

More investigation and data collection of same cases are needed to have a more clear picture regarding the pathophysiology and the underlying cause.

Keywords:

airway, bronchololith, stone, tracheolith

Egypt J Otolaryngol 31:202–203

© 2015 The Egyptian Oto - Rhino - Laryngological Society
1012-5574

Introduction

The presence of stone in the airway is uncommon condition. Broncholithiasis is characterized by formation of the stone due to erosion of calcified lymph node in the bronchus. There is no reported case of a stone in the trachea in the literature. This case reports a stone in the trachea of a patient with tracheostomy. We would like to propose the term tracheolith to describe this condition.

Case report

A 13-year-old girl was diagnosed as a case of oculocerebral syndrome (Lowe's syndrome). She was admitted to the ICU because of respiratory problem. During her stay of more than 1 month, tracheostomy was performed using silicon (portex) tracheostomy tube with cuff. Later, gastrostomy was performed for feeding purposes. Tracheostomy care was given either at hospital or by qualified nurse at home after discharge. About 2 years and 9 months later (post-tracheostomy), she was brought to emergency department with difficulty in breathing, despite adequate cleaning of tracheostomy tube and suctioning of secretions as per standard guidelines. Patient was taken to operation room and tracheostomy tube was replaced, but surprisingly dyspnea aggravated. Plain radiograph of the neck and chest revealed an opaque shadow in trachea between carina and tip of tracheostomy tube. A bronchoscopy showed a gritty mass, which was removed in piecemeal with difficulty. Slight oozing was noted at the site and was controlled. Postoperatively, airway obstruction was completely alleviated. The removed specimen was sent for analysis, which concluded to be a stone. Since then,

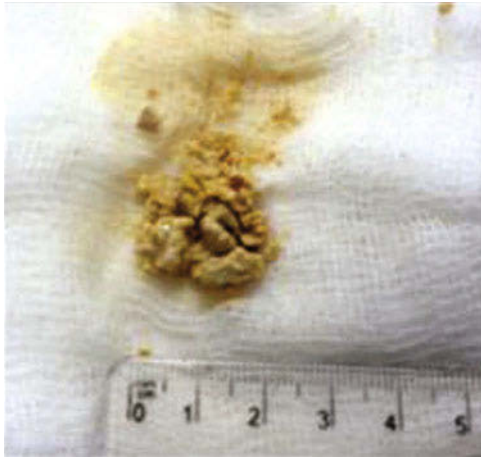she is under periodic observation and no similar complaint has been reported.

Discussion

It is uncommon to have stone formation in the airway. Bronchololith is a term used to describe presence of stone in the bronchus due to erosion of calcified lymph node to the airway [1]. The most common underlying causes are tuberculosis and histoplasmosis [1,2]. Hemoptysis is the most common symptom and lithoptysis is almost peculiar for the disease [2,3]. Computed tomographic scan can help in the diagnosis and knowing the site to plan for removal [3,4]. Lobectomy is the traditional method of treatment but there are many reported cases managed using bronchoscopy or moreover laser and cryotherapy [2,5–7]. We want here to introduce a new term, tracheolith. In this case, we reported a presence of stone in the trachea of a patient with tracheostomy for 2 years. It is unusual cause of tracheostomy tube obstruction. Chest radiography showed the finding of radio-opaque mass and bronchoscope was used to remove the mass (Figs. 1 and 2). The analysis of the mass confirmed the diagnosis of stone (Table 1). The patient was followed for 1 year after that without recurrence.

It is unclear what the underlying cause is, because the patient does not have history of tuberculosis or histoplasmosis. We suggest two theories to explain this phenomenon: to have calcified granuloma after prolong tracheostomy or formation of stone from stagnant secretion. It is unlikely to have lymph node eroding to trachea because it will be obvious on the bronchoscopy. As the stone is formed in

Figure 1



Gross picture of the stone after removal.

Table 1 Chemical analysis of the stone

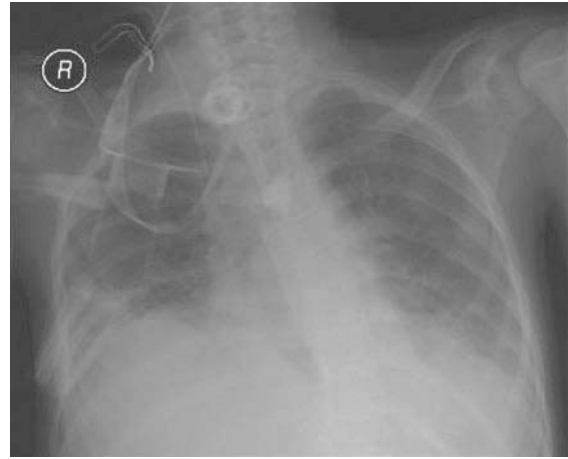
Elements	(%)
Calcium oxalate	16
Calcium phosphate	26
Calcium	30
Oxalate	10
Ammonium	0
Phosphate	15
Magnesium	0
Uric acid	0
Cystine	0

the trachea, it can be directly removed by the rigid bronchoscope.

Conclusion

Tracheolith is a stone formation in the trachea. As it leads to airway obstruction, it must be removed. The most effective and easy way is to perform rigid bronchoscopy. The pathophysiology of this condition is still unknown, but we think that it is related to prolong tracheostomy. We recommend performing chest radiography in all cases of tracheostomy obstruction.

Figure 2



Chest radiograph of the patient showing radio-opaque mass at the end of the tracheostomy tube.

More investigation and data collection of same cases are needed to have a more clear picture regarding the pathophysiology and the underlying cause.

Acknowledgements

Conflicts of interest

There are no conflicts of interest.

References

- 1 Nollet AS, Vansteenkiste JF, Demedts MG. Broncholithiasis: rare but still present. *Respir Med* 1998; 92:963–965.
- 2 Reddy AJ, Govert JA, Sporn TA, Wahidi MM. Broncholith removal using cryotherapy during flexible bronchoscopy: a case report. *Chest* 2007; 132:1661–1663.
- 3 Shin MS, Ho KJ. Broncholithiasis: its detection by computed tomography in patients with recurrent hemoptysis of unknown etiology. *J Comput Tomogr* 1983; 7:189–193.
- 4 Conces DJ, Tarver RD, Vix VA. Broncholithiasis: CT features in 15 patients. *Am J Roentgenol* 1991; 157:249–253.
- 5 Olson EJ, Utz JP, Prakash UB. Therapeutic bronchoscopy in broncholithiasis. *Am J Respir Crit Care Med* 1999; 160:766–770.
- 6 Menivale F, Deslee G, Vallerand H, Toubas O, Delepine G, Guillou PJ, *et al.* Therapeutic management of broncholithiasis. *Ann Thorac Surg* 2005; 79:1774–1776.
- 7 Miks VM, Kvale PA, Riddle JM, Lewis JW. Broncholith removal using the YAG laser. *Chest* 1986; 90:295–297.