

Value of hyperbaric oxygen therapy in the management of malignant otitis externa patients

Reda M. Sabra, Mohamed S. Taha, Ahmed G. Khafagy, Talat Elsamny

Department of ENT, Ain Shams University, Cairo, Egypt

Correspondence to Reda M. Sabra, MD, 71 Waley Alaahd, Hadayek Elkobba, Cairo, Egypt
Tel: +20 260 12021;
e-mail: redasabra@yahoo.com

Received 12 December 2014

Accepted 01 February 2015

The Egyptian Journal of Otolaryngology
2015, 31:143–148

Background

Malignant external otitis is a rapidly spreading bacterial infection that is aggressive in nature and may be fatal if left untreated. Hyperbaric oxygen therapy (HBOT) is a medical treatment in which the entire body is placed in an airtight chamber at increased atmospheric pressure and has been proven to be effective for a number of different medical conditions.

Objective

The aim of this study was to assess the usefulness of HBOT as an adjunctive treatment in patients with malignant otitis externa.

Patients and methods

Forty-three diabetic patients, who had malignant otitis externa, underwent control of diabetes mellitus and were treated with ciprofloxacin. HBOT was administered to 15 patients as an adjunctive treatment. All the patients were evaluated clinically (in terms of ear discharge, granulations, and pain severity) and radiologically by a temporal bone computed tomography scan. The minimum follow-up duration in both groups was 2 months. HBOT was administered in one session every other day for 2 months, resulting in a total of 30 sessions. Patient factors analyzed included age, sex, ear discharge, and pain severity.

Results

A total of 43 patients (28 men, 15 women) were divided into two groups: group A (28 patients) only received the antibiotic ciprofloxacin and group B (15 patients) was treated with ciprofloxacin and hyperbaric oxygen. The severity of pain improved considerably and the pain score decreased markedly from score 3 (severe) to score 0 (no pain) after 1 month in 46.7 and 93.3% of the patients by the end of the second month in comparison with patients treated only with the antibiotic: 0% after 1 month and 28.5% after 2 months. On clinical and microscopic examination, both ear discharge and granulations in the external canal had improved considerably. There was no ear discharge in 80% of patients in group B after one month treatment, 93.3% after 2 months, in comparison with 0% after 1 month, 28.5% after 2 months treatment in group A, highly statistically significant ($P < 0.001$).

Conclusion

The addition of HBOT to medical treatment is highly effective and has facilitated considerable improvement in patients.

Keywords:

hyperbaric oxygen therapy, malignant, otitis externa

Egypt J Otolaryngol 31:143–148

© 2015 The Egyptian Oto - Rhino - Laryngological Society
1012-5574

Introduction

Malignant external otitis is an infection that affects the external auditory canal and temporal bone. The causative organism is usually *Pseudomonas aeruginosa*, and the disease commonly manifests in elderly patients (pt) with diabetes. The infection begins as an external otitis that progresses to an osteomyelitis of the temporal bone. Spread of the disease outside the external auditory canal occurs through the fissures of Santorini and the osseocartilaginous junction [1]. Malignant external otitis is a rapidly spreading bacterial infection that accounts for a relatively small proportion of infections, but arise aggressive in nature and may be fatal if left untreated [2].

Hyperbaric oxygen therapy (HBOT) is a medical treatment in which the entire body is placed in an

airtight chamber at increased atmospheric pressure. In this chamber, the patient is surrounded by and breathes 100% pure oxygen. This treatment has been proven effective for a number of different medical and surgical conditions either as a primary or as an adjunctive treatment. The pressure can be increased to as much as three times the normal atmospheric pressure (although the usual treatment pressure is 1.5–2.0 atmospheric depending on the diagnosis). Pure, 100% oxygen is continuously maintained and circulated throughout the chamber during the treatment [3].

HBOT is an effective treatment for acute and chronic damaged tissue of all types – any cause, any duration, any location. The underlying causes can be trauma, infection, autoimmunity, ischemia, hypoxia, toxins, or something similar [4].

These infections may be single aerobic or anaerobic, but are more often mixed infections. They are often observed in compromised hosts who have diabetes or a vasculopathy of another type. These infections are named on the basis of their clinical presentation and include malignant external otitis [5]. Irrespective of the depth of the tissue invasion, these infections have similar pathophysiology that includes local tissue hypoxia, which is exacerbated by a secondary occlusive endarteritis [5].

Multiple clinical studies suggest that HBOT is efficacious in the treatment of necrotizing soft tissue infections [6–15]. These include case series, retrospective and prospective studies, and nonrandomized clinical trials. They suggest significant reductions in mortality and morbidity.

It is also used to treat many other medical conditions that are still considered experimental by the mainstream medical establishment – despite decades of reported benefits.

The aim of this article is to assess the value of hyperbaric oxygen (HBO) as an adjunctive treatment of malignant external otitis along with antimicrobial agents.

Patients and methods

Patients' selection criteria

This is a retrospective study. It was carried out at the Otorhinolaryngology Department, Ain Shams University Hospitals in the period between January 2011 and December 2014 with Institutional Review Board approval. An informed written consent was obtained from all participants. Forty-three patients (pt) were examined and treated for malignant otitis externa; they all had diabetes mellitus, and were undergoing treatment for control of diabetes mellitus. They were divided into two groups: group A (28 pt) only received the antibiotic ciprofloxacin and group B (15 pt) was

treated with ciprofloxacin and HBO as an adjunctive treatment. The minimum follow-up duration in both groups was 2 months. Their ages ranged from 56 to 72 years. Both groups were similar in age, ear discharge bacteriology, and antimicrobial therapy.

The Student *t*-test was used for statistical analysis. Skewed numerical data are presented as median and interquartile range. Qualitative data are presented as number and percentage. A *P* value less than 0.05 was considered statistically significant.

Treatment strategy

Control of diabetes: All patients were treated with insulin injections and diabetes mellitus was strictly controlled.

Ear discharge culture and sensitivity were assessed for all patients, which indicated growth of pseudomonas.

Computed tomography (CT) scan temporal bone was performed before (Fig. 1a and b) and 2 months after treatment (Fig. 2a and b). All patients were administered an antibiotic (ciprofloxacin). HBOT was administered at 2.0–2.5 ATA for 90 min per session. HBOT was administered for one session every other day for 2 months. HBOT was administered in the Naser National Institute in Sechrist hyperbaric oxygen chamber (Sechrist Monoplace Hyperbaric Chambers H-Series) (Fig. 3).

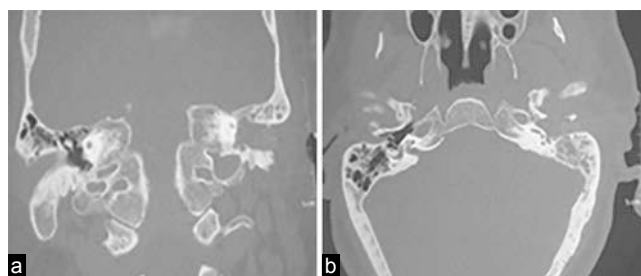
Comparison criteria

Clinical microscopic examination (ear discharge, external canal edema, and granulations). Figure 4 showed granulations filling the external ear canal and purulent discharge (Table 1).

Pain severity (pain was scored for assessment of severity of pain and degree of improvement and cure).

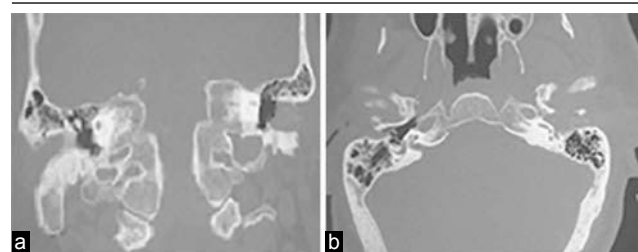A pain score of 3 indicated severe pain (preventing patients from sleep and normal activities), a pain score of 2 indicated moderate pain (controlled sometimes

Figure 1



(a, b): Computed tomography (CT) scan temporal bone coronal and axial view before treatment showing opacity in the left mastoid bone and the external ear canal.

Figure 2



(a, b): Computed tomography (CT) scan temporal bone coronal and axial view after treatment showing improvement of mastoid opacity.

Table 1 Comparison criteria

Patient comparison criteria	Group A		Group B	
Treatment	Antibiotic only (<i>n</i> = 28)		Antibiotic + HBOT (<i>n</i> = 15)	
Clinical examination [<i>n</i> (%)]				
Ear discharge and granulations	21 (75) (profuse)	7 (25) (moderate)	11 (73.3) (profuse)	4 (26.7) (moderate)
Pain severity [<i>n</i> (%)]	20 (71.4)	8 (28.6)	13 (87)	2 (13)
Score before treatment	3	2	3	2
CT temporal bone scan	Before and after 2 months of treatment			

CT, computed tomography; HBOT, hyperbaric oxygen therapy.

Figure 3

Hyperbaric oxygen room.

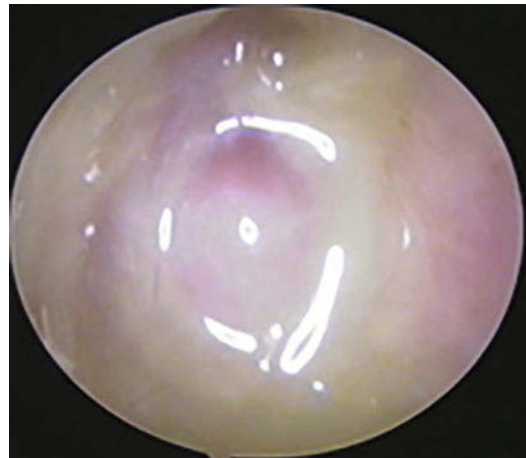with powerful analgesics), a pain scored of 1 indicated mild pain (bearable without analgesics), and a pain score of 0 indicated no pain.

Post-treatment CT scan: CT temporal bone was performed 2 months after the initiation of therapy (Fig. 2a and b).

Results

A total of 43 patients had malignant external otitis; these patients were divided into two groups: group A (*n* = 28) received antibiotics only (18 men, 10 women; median age 64 years, interquartile range 58–70) and group B (*n* = 15) received HBO (90 min at 2.5 ATA) in addition to antibiotics (10 men, five women; median age 62 years, interquartile range 56–72) (Table 2).

A total of 43 patients were identified, including 15 patients who underwent HBOT with antibiotics. The degree of improvement of patients after treatment with adjuvant HBOT with antibiotic was high both symptomatically and clinically, and for CT scan of temporal bone (Tables 3–6). Pain severity improved markedly and the pain score decreased considerably from 3 (severe) to 0 (no pain) after 1 month in 46.7 and 93.3% of the patients by the end of the second month in comparison with patients treated only with

Figure 4

Ear granulation, discharge.

an antibiotic: 0% after 1 month and 28.5% after 2 months. Pain score in group B patients was greatly shifted toward score 0 (no pain) more than three to five folds by the end of treatment; 93.3% were pain free in group B compared with 28.5% in group A, and this was highly statistically significant (Figs. 5 and 6). On clinical and microscopic examination, both ear discharge and granulations in the external canal were markedly improved. In group B, 80% of patients had no discharge after 1 month and 93.3% after 2 months, in comparison with 0% after 1 month and 28.5% after 2 months treatment in group A; this was highly statistically significant ($P < 0.001$) (Figs. 7 and 8). Also, there was radiological improvement in mastoid opacity and fluid and granulations in the mastoid and the middle ear.

Discussion

Necrotizing invasive pseudomonal infection of the external auditory canal (malignant external otitis) is an uncommon, but major disorder in the elderly. The high morbidity, and even mortality, of this disorder has been reduced by the early and intensive use of combination antipseudomonal antibiotics. However, in severely immunocompromised patients or in infections involving the base of the skull, multiple

cranial nerves, or the meninges, conventional therapy is prolonged, intensive, and relatively ineffective [6]. Prompt identification, antibiotic therapy, control of medical condition, and HBOT have reduced the mortality resulting from this infection. Oxygen, at increased pressures, augments tissue oxygen partial pressure, allowing increased bacterial killing by providing a substrate for the formation of oxygen free radicals and augmenting respiratory burst [16]. During the healing process, hyperoxia causes increased formation of capillaries for oxygen, nutrient, and antibiotic delivery, leading to increased efficacy of some antibiotics in the high-oxygen environment, and possibly more rapid overall wound healing [17,18]. HBOT can enhance host immune systems [19]. There is limited evidence showing that HBOT may facilitate antibiotic penetration or action in several classes of antibiotics, including aminoglycosides [20], cephalosporins, sulfonamides, and amphotericin [19].

Table 2 Demographic data of the study groups

Patient data	Group A	Group B
Number of patients	28	15
Sex	18 M, 10 F	10 M, 5 F
Age	58–70 (64)	56–72 (62)
DM	+++++	+++++
Treatment	Antimicrobial therapy	Antimicrobial therapy+HBOT
Ear discharge bacteriology	++ Pseudomonas	++ Pseudomonas
Pain	Main C/O	Main C/O

DM, diabetes mellitus; HBOT, hyperbaric oxygen therapy.

Table 3 Results after 1 month of treatment

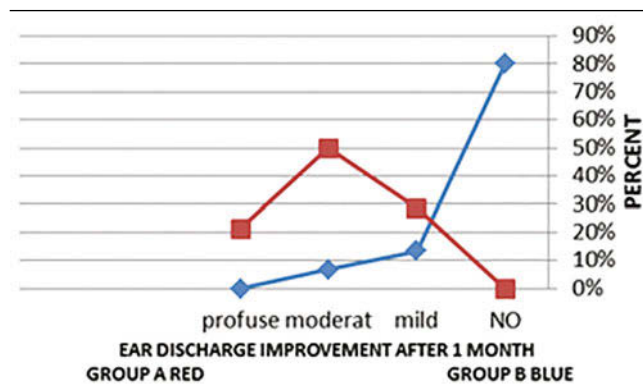
Results after 1 month of treatment	Group A	Group B
Number of patients	28	15
Clinical examination [n (%)]		
Ear discharge		
No		12 (80)
Mild	8 (28.6)	2 (13.3)
Moderate	14 (50)	1 (6.7)
Profuse	6 (21.4)	
Pain severity score [n (%)]		
0 (no pain)	0 (0)	7 (46.7)
1 (mild pain)	9 (32.1)	6 (40)
2 (moderate pain)	17 (60.7)	2 (13.3)
3 (severe pain)	2 (7.2)	0 (0)

Table 4 Pain severity score after 1 and 2 months of treatment

Group	Group A (28 patients)				Group B (15 patients)				P
	No	Mild	Moderate	Severe	No	Mild	Moderate	Severe	
After 1 month	0	9	17	2	7	6	2	0	<0.001
	0%	32.1%	60.7%	7.2%	46.7%	40%	13.3%	0%	
After 2 months	8	15	5	0	14	1	0	0	<0.001
	28.6%	53.6%	17.9%	0%	93.3%	6.7%	0%	0%	

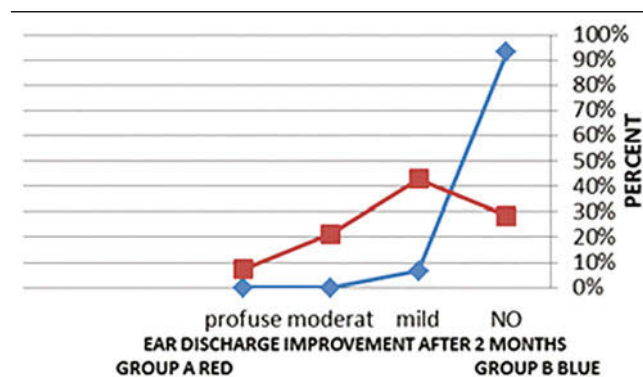
Pain Score: NO = 0, Mild = 1, Moderet = 2, Sever = 3.

Figure 5



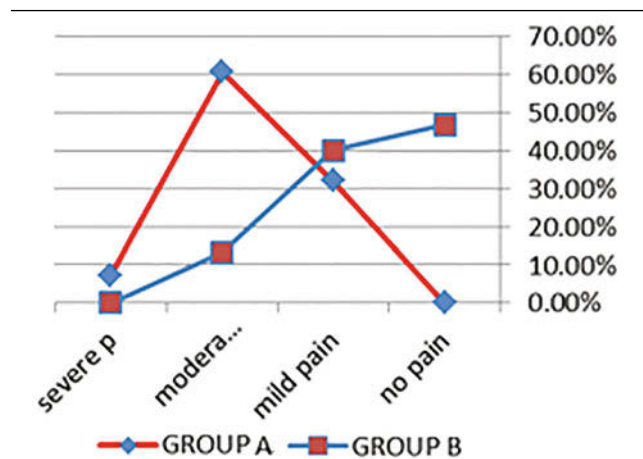
Pain severity after 1 month.

Figure 6



Pain severity after 2 months.

Figure 7



Ear discharge after 1 month.

Infections for which HBOT has been studied and is recommended by the Undersea and Hyperbaric Medicine Society include necrotizing fasciitis, gas gangrene, chronic refractory osteomyelitis (including malignant otitis externa), mucormycosis, intracranial abscesses, and diabetic foot ulcers that have concomitant infections [7]. In all of these processes, HBOT is used adjunctively along with antimicrobial agents and aggressive surgical debridement [7].

This study evaluates how the addition of HBOT to antibiotic treatment has affected improvement, cure, and infection control in these patients.

In our study, we found that the addition of HBOT to the antibiotic therapy was very beneficial to the

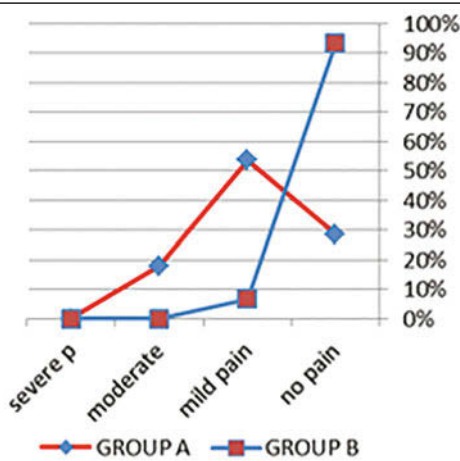
patients with malignant otitis externa in the control of infection, improvement of symptoms and signs, and cure of the condition. Clinically, in group B, 86.7% of the patients reported considerable improvement in pain after the first month of treatment (15 sessions), with 93.3% being pain free after the second month (30 sessions). On the other hand group A showed only 32.1% improved of pain after 1 month and 28.5% free of pain after 2 months those patients treated with antibiotic only ($P < 0.001$). On examination, purulent ear discharge was markedly reduced with HBOT therapy, there was no ear discharge in 80% of patients after the first month and in 93.3% of patients after the second month; without HBOT therapy, only 28.5% of patients were free of discharge after 2 months ($P < 0.001$). Radiologically, CT scan temporal bone indicated considerable improvement with HBOT treatment, with less infection, opacity, fluid in mastoid, and osteomyelitic changes. Generally, all cases treated with antibiotic and HBOT showed considerable improvement subjectively and objectively by examination and radiology, with more than 93% of cases cured and discharged early from the hospital. In contrast, those treated only with antibiotic showed slow improvement, low percent of complete cure (less than 30%), with persistent discharge and some degree of pain, and longer duration of hospitalization. No complications were reported with this treatment.

Davis et al. [6] reported that all 16 of their patients responded promptly when a 30-day course of HBO was added to the antibiotic regimen, and all patients remained free from infection during 1 to 4 years of follow-up. No complications were noted. Pilgramm et al. [8] also showed that hyperbaric oxygenation had a positive influence on the reduction of *P. aeruginosa* in the external auditory canal and on the symptoms of pain.

Mader and Love [9] reported control of *P. aeruginosa* infection in their patient when adjunctive HBOT was added to the treatment regimen. Also, Gilain et al. [10] found that the addition of HBO as a complementary treatment led to the regression of clinical signs and resolution of infection.

Tisch et al. [11] found, over a period of more than 5 years, that 16 of 22 patients treated on the basis of a multimodal

Figure 8



Ear discharge after 2 months.

Table 5 Results after 2 months of treatment

Results after 2 months of treatment	Group A	Group B
Number of patients	28	15
Clinical examination [n (%)]		
Ear discharge		
No	8 (28.5)	14 (93.3)
Mild	12 (42.9)	1 (6.7)
Moderate	6 (21.4)	0 (0)
Profuse	2 (7.2)	
Pain severity (score) [n (%)]		
0 (no pain)	8 (28.5)	14 (93.3)
1 (mild pain)	15 (53.6)	1 (6.7)
2 (moderate pain)	5 (17.9)	0 (0)
3 (severe pain)	0 (0)	0 (0)

Table 6 Ear discharge after 1 and 2 months of treatment

Group	Group A (28 patients)				Group B (15 patients)				P
	No	Mild	Moderate	Profuse	No	Mild	Moderate	Profuse	
After 1 month	0	8	14	6	12	2	1	0	<0.001
	0%	28.6%	50%	21.4%	80%	13.3%	6.7%	0%	
After 2 month	8	12	6	2	14	1	0	0	<0.001
	28.6%	42.9%	21.4%	7.2%	93.3%	6.7%	0%	0%	

concept remained free from recurrences. Narozny *et al.* [12] have confirmed the role of HBO as a valuable, beneficial, and supporting classical treatment method in the treatment of bacterial-caused malignant otitis externa. Shupak *et al.* [13] treated two patients with extensive necrotizing otitis externa by hyperbaric oxygenation, followed by complete resolution, with no recurrence.

Heiden [14] confirmed in his study that multimodal therapy, with the inclusion of HBOT, enabled a reduction in mortality compared with earlier case reports without HBOT.

In the study of Saxby *et al.* [15], 70% of patients were considered cured of their disease, being disease free at follow-up. HBOT confers minimal morbidity, but its role in malignant external otitis (MOE) remains uncertain. The high mortality of MOE despite a maximal therapeutic intervention highlights the need for more effective treatment protocols.

Conclusion

The addition of HBOT to medical treatment is highly effective and has led to marked improvements in patients and the time required to achieve control of infection in these patients.

Acknowledgements

Conflicts of interest

None declared.

References

- 1 Karaman E, Yilmaz M, Ibrahimov M, Hacıyev Y, Enver O. Malignant otitis externa. *J Craniofac Surg* 2012; 23:1748–1751.
- 2 Carfrae MJ, Kesser BW. Malignant otitis externa. *Otolaryngol Clin North Am* 2008; 41:537–549.
- 3 Kindwall E, Whelan H. *Hyperbaric Medicine Practice*. 2nd ed. Flagstaff, AZ: Best Publishing Company; 2004:chap 1, 18, 19, 20, 25, 29, 30.
- 4 Feldmeier J. *Hyperbaric oxygen 2003: indications and results – The Hyperbaric Oxygen Therapy Committee Report*. Kensington, Maryland: Undersea and Hyperbaric Medical Society Inc.; 2003.
- 5 Riseman JA, Zamboni WA, Curtis A, Graham DR, Konrad HR, Ross DS. Hyperbaric oxygen therapy for necrotizing fasciitis reduces mortality and the need for debridements. *Surgery* 1990; 108:847–850.
- 6 Davis JC, Gates GA, Lerner C, Davis MG Jr, Mader JT, Dinesman A. Adjuvant hyperbaric oxygen in malignant external otitis. *Arch Otolaryngol Head Neck Surg* 1992; 118:89–93.
- 7 Kaide CG, Khandelwal S. Hyperbaric oxygen: applications in infectious disease. *Emerg Med Clin North Am* 2008; 26:571–595.
- 8 Pilgramm M, Frey G, Schumann K. Hyperbaric oxygenation – a sensible adjunctive therapy in malignant external otitis. *Laryngol Rhinol Otol (Stuttg)* 1986; 65:26–28.
- 9 Mader JT, Love JT. Malignant external otitis. Cure with adjunctive hyperbaric oxygen therapy. *Arch Otolaryngol* 1982; 108:38–40.
- 10 Gilain L, Labroue M, Aidan D, Ragu MP, Planquart X, Peynegre R. Value of hyperbaric oxygen therapy in the treatment of malignant otitis externa. Apropos of a case. *Ann Otolaryngol Chir Cervicofac.* 1993; 110:50–54.
- 11 Tisch M, Lorenz KJ, Harm M, Lampl L, Maier H. The treatment of necrotizing otitis externa with a combination of surgery, antibiotics, specific immunoglobulins and hyperbaric oxygen therapy. Results of the Ulm Treatment Concept. *HNO* 2003; 51:315–320.
- 12 Narozny W, Kuczkowski J, Stankiewicz C, Kot J, Mikaszewski B, Przewozny T. Value of hyperbaric oxygen in bacterial and fungal malignant external otitis treatment. *Eur Arch Otorhinolaryngol* 2006; 263:680–684.
- 13 Shupak A, Greenberg E, Hardoff R, Gordon C, Melamed Y, Meyer WS. Hyperbaric oxygenation for necrotizing (malignant) otitis externa. *Arch Otolaryngol Head Neck Surg* 1989; 115:1470–1475.
- 14 Heiden C. Malignant otitis externa: experience with hyperbaric oxygen therapy. *Diving Hyperb Med* 2010; 40:182.
- 15 Saxby A, Barakate M, Kertesz T, James J, Bennett M. Malignant otitis externa: experience with hyperbaric oxygen therapy. *Diving Hyperb Med* 2010; 40:195–200.
- 16 Sheikh AY, Gibson JJ, Rollins MD, Hopf HW, Hussain Z, Hunt TK. Effect of hyperoxia on vascular endothelial growth factor levels in a wound model. *Arch Surg* 2000; 135:1293–1297.
- 17 Knighton DR, Halliday B, Hunt TK. Oxygen as an antibiotic. The effect of inspired oxygen on infection. *Arch Surg* 1984; 119:199–204.
- 18 Knighton DR, Fiegel VD, Halverson T, Schneider S, Brown T, Wells CL. Oxygen as an antibiotic. The effect of inspired oxygen on bacterial clearance. *Arch Surg* 1990; 125:97–100.
- 19 Park MK, Myers RA, Marzella L. Oxygen tensions and infections: modulation of microbial growth, activity of antimicrobial agents, and immunologic responses. *Clin Infect Dis* 1992; 14:720–740.
- 20 Phillips JS, Jones SEM. Hyperbaric oxygen as an adjuvant treatment for malignant otitis externa (Cochrane Review). In: *The Cochrane Library*, Issue 1, 2006. Oxford.