

Kimura's disease of head and neck: a rare case presentation

Talha A. Qureshi^a, Moghira I. Siddiqui^a, Mohammad U. Tariq^b

Departments of ^aOtolaryngology-Head & Neck Surgery ^bHistopathology, Aga Khan University, Karachi, Pakistan

Correspondence to Talha A. Qureshi, MBBS, Department of Otolaryngology-Head & Neck Surgery, Aga Khan University, Stadium Road, Karachi 74800, Pakistan
Tel: +92 303 913 6047; fax: +92 21 3493 4294, 3493 2095;
e-mail: talha.ahmed@aku.edu

Received 23 November 2014

Accepted 5 December 2014

The Egyptian Journal of Otolaryngology

2015, 31:73–75

Kimura's disease (KD) is a rare, unusual occurrence, predominantly seen in Asian men, and poses a diagnostic challenge, often manifesting with allergic, eosinophilic hyperplasia, and nonspecific lymphadenitis. A 39-year-old man presented with mobile, well circumscribed, facial and neck swelling. His earlier biopsy showed a reactive lymph node hyperplasia on ultrasound neck and was suggestive of lipomatosis. As definitive diagnosis could not be made, the patient was planned for excision and biopsy. Subsequent histopathology demonstrated eosinophilic infiltration of lymphoid follicles and expansion of interfollicular area with interfollicular eosinophilic abscess formation and capillary venule proliferation. This was quite interesting as the previously diagnosed case of nonspecific lymphadenitis based on biopsy later turned out to be a rare occurrence of KD. Furthermore, because of other systemic symptoms (pedal edema and eye irritation), which probably reflected generalized manifestations of KD, the patient was referred to a rheumatologist after diagnosis, where he was effectively managed with immunotherapy and steroids.

Keywords:

eosinophilic infiltrate, head and neck swelling, Kimura's disease, lymphoid hyperplasia

Egypt J Otolaryngol 31:73–75

© 2015 The Egyptian Oto - Rhino - Laryngological Society
1012-5574

Introduction

Kimura's disease (KD) is a chronic inflammatory condition that was first described in 1937 in China, and is a condition mainly affecting young to middle-aged men of Asian origin. The lesion in KD is generally considered self-limiting, and the male-to-female ratio is 3.5 : 1 [1]. Furthermore, the pathology is often associated with eosinophilia and elevated serum immunoglobulin E levels [2,3]. KD has histopathological features of lymphoid tissue hyperplasia, and lymphoid follicles have significant eosinophilic infiltration, fibrosis, and capillary venule proliferation [1]. Importantly, KD assumes unique importance as it may pose a problem in differential diagnosis. Here, we present an interesting case with facial and neck swellings that was previously diagnosed as nonspecific lymphadenitis and later proved out to be KD.

Case presentation

A 39-year-old man presented with complaints of right-sided cheek swelling, along with another swelling in the right submandibular region, at the Otolaryngology-Head & Neck Surgery Clinic of the Aga Khan University Hospital. He had multiple swellings all over his body, including the abdomen, left thigh, and back. Right cheek and neck swellings were the largest, measuring 2 × 2 and 3 × 3 cm, respectively, and had been increasing in size for the last 2 years. Two years ago, he had undergone incisional biopsy of the submandibular neck swelling that showed reactive lymph node hyperplasia with nonspecific lymphadenitis. At presentation at our clinic, the

patient also complained of mild swelling of his feet and irritation in his eye. The research was approved by ethical committee of the university and the signed consent letters got from the patients.

On presentation, the swellings were mobile, nontender, and well circumscribed. Ultrasound of the neck and fine needle aspiration cytology of both the swellings were advised. However, fine needle aspiration cytology was inconclusive and reported it to be a reactive lymphoid tissue, and ultrasound neck was suggestive of lipomatosis, possibly angiolipoma. Hence, the patient was planned for surgical excisional biopsy of both lesions for definitive diagnosis as well as management. As the masses appeared benign, were neither big nor too distantly apart, and did not encase any important structures, their excision during invasive biopsy seemed ideal, and the patient also wanted the masses removed for cosmetic reasons. Hence, the patient underwent excision of both the right facial and cervical masses utilizing a single incision with subsequent histopathology. Intraoperatively, the masses were felt to be soft to firm swellings, approximately sized 2 × 3 and 3 × 4 cm from the facial and submandibular region, respectively.

Histopathological diagnosis

The right cervical lesion comprised three tan to gray brown, nodular tissue pieces, with the largest measuring 3.3 × 2.6 × 2.5 cm and others measuring 2.6 × 2.2 cm. The cut surfaces were tan pink, fleshy, soft, and homogenous. However, the facial lesion comprised a single, tan to gray brown, irregular tissue

piece measuring $3.5 \times 1.5 \times 1.4$ cm. The cut surface was gray white to brown, fleshy soft, with hemorrhage.

Microscopically, both the lesions revealed altered lymph node architecture showing prominent lymphoid follicles with germinal centers (Fig. 1). Interfollicular expansion was noted (Fig. 1), which exhibited eosinophilic infiltrate/abscess and proliferation of postcapillary endothelial venules (Figs. 2 and 3). Interfollicular areas also showed lymphocytes and histiocytes admixed with the predominant eosinophilic population (Figs 2 and 3).

Course of treatment

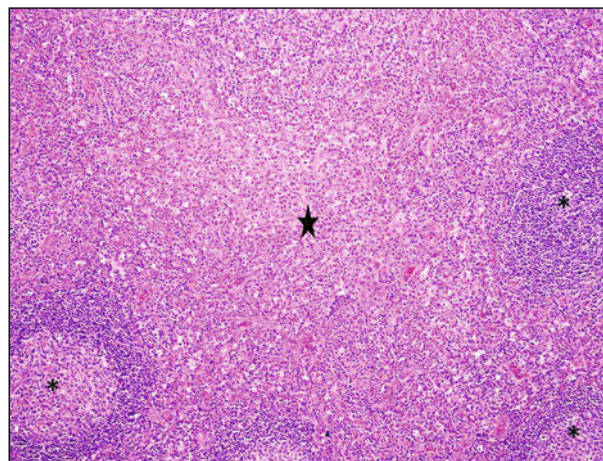
The patient was referred to the rheumatologist for a possible generalized involvement of KD and causal management of pedal edema and eye irritation. The patient was later managed effectively with immunotherapy and steroids for his systemic symptoms.

Discussion

KD is a disease of young to middle-aged male patients, with majority of them aged between 20 and 40 years [1–3]. The cause of KD remains idiopathic; the proposed theories for the cause of KD includes dysfunction and interference with immune regulation, atopic reaction to continuous stimulus of antigen of a virus, arthropod [3], and neoplasm. Candida has also been hypothesized as a source of antigemia, but no direct evidence exists in terms of presence of hyphae or spores [2,3]. Clinical features of KD may include a solitary or multiple lymphadenopathy (67–100% cases), the former being more frequent [2,3]. Salivary gland involvement is commonly seen [2,3]. Other features include the involvement of subcutaneous single or multiple nodules, mainly located at the head or neck area in the preauricular, parotid, or submandibular region [2,3]. The diagnosis of KD remains challenging and can be confirmed only by histological study. Fine needle aspiration may be helpful and facilitates in ruling out other differentials but is not diagnostic for KD. Confirmatory diagnosis depends on the final histopathology of excised specimen [2,3].

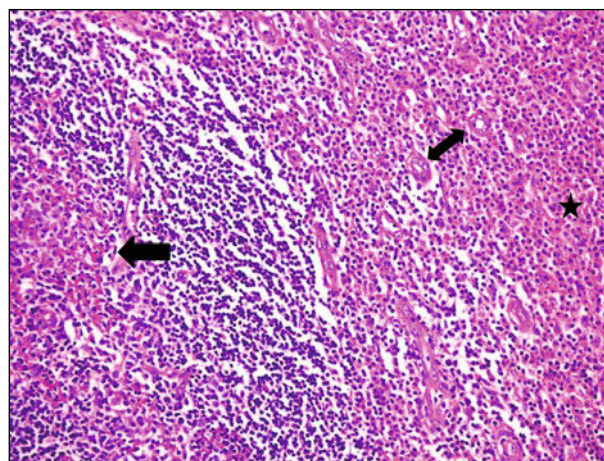
Imaging modalities such as ultrasound, computerized tomography, and MRI may aid in the diagnosis and staging of the disease, along with lymph node involvement and progression of the disease. Because of uncommon occurrence, clinicians and radiologists are not completely aware of diagnostic imaging findings of KD, often leading to unwanted investigations [4]. Hence, it is important to understand

Figure 1



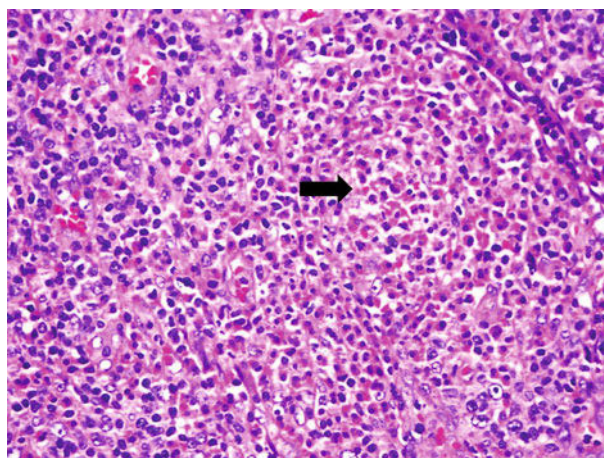
Lymphoid follicles with prominent germinal centers (asterisks on both sides) and expansion of interfollicular areas by eosinophilic infiltrate (star in center) ($\times 100$).

Figure 2



Germinal center with eosinophilic infiltrate (single head arrow), interfollicular areas with eosinophilic infiltrate (star), and postcapillary endothelial venules (double head arrow) ($\times 200$).

Figure 3



Eosinophilic abscess formation (arrow head) in the interfollicular region ($\times 400$).

that KD is characterized by an abnormal proliferation of vascular endothelium and lymphoid follicles, with peripheral eosinophilia. KD could be a type of hypersensitivity reaction due to a marked, infiltrative presence of eosinophilia [3]. The lymphoid infiltrates in KD demonstrate obvious lymphofollicular hyperplasia, germinal center vascularization, eosinophil infiltration, abscess formation, and existence of mild to moderate vascular proliferation [5]. Hodgkin's disease may also be suspected due to the presence of giant cells and polymorphous eosinophil infiltrates; however, the absence of Reed–Sternberg cells distinguishes both the conditions [6].

Because of rarity of the pathology and limited research on management, the treatment of KD remains controversial. Surgical excision is the first-line treatment; however, extensive and radical approach is often not taken because of lack of evidence of malignant transformation. Recurrence rate is reported as high as 25% [2,3]. However, systemically administered steroids have good effects on the management and control of the disease, typically prednisolone. Cyclosporine may be considered a therapy for KD due to its effect on T-helper 2 (Th2) lymphocytes [7]. Radiotherapy can be considered in cases of steroid-resistant lesions, but due to unavoidable side effects, including secondary malignancies, should be evaluated in terms of risk versus benefit ratio [8].

Our case was interesting because initial biopsy indicated nonspecific lymphadenitis, whereas the ultrasonographic picture was suggestive of lipomatosis. However, excisional biopsy and its histopathological analysis later suggested it to be a rare case of KD.

Furthermore, as the patient was possibly having systemic manifestations of KD (irritation in eyes and mild pedal edema), he was referred to the rheumatologist and patient's symptoms were effectively managed with immunotherapy and steroids after the diagnosis was correctly established.

Acknowledgements

Qureshi TA: concept, acquisition, and interpretation of the case, along with preparation and drafting of the manuscript; Siddiqui MI: interpretation of the case and manuscript review; Usman M: interpretation of the case along with histopathological input.

Conflicts of interest

There are no conflicts of interest.

References

- 1 Hobeika CM, Mohammed TH, Johnson GL, Hansen K. Kimura's disease: case report and review of the literature. *J Thorac Imaging* 2005; 20:298–300.
- 2 Chen H, Thompson LD, Aguilera NS, Abbondanzo SL. Kimura disease: a clinicopathologic study of 21 cases. *Am J Surg Pathol* 2004; 28:505–513.
- 3 Tseng CF, Lin HC, Huang SC, Su CY. Kimura's disease presenting as bilateral parotid masses. *Eur Arch Otorhinolaryngol* 2005; 262:8–10.
- 4 Goldenberg D, Gatot A, Barki Y, Leiberman A, Fliss DM. Computerized tomographic and ultrasonographic features of Kimura's disease. *J Laryngol Otol* 1997; 111:389–391.
- 5 Sun QF, Xu DZ, Pan SH, Ding JG, Xue ZQ, Miao CS, *et al.* Kimura disease: review of the literature. *Intern Med J* 2008; 38:668–672.
- 6 Yuen HW, Goh YH, Low WK, Lim-Tan SK. Kimura's disease: a diagnostic and therapeutic challenge. *Singapore Med J* 2005; 46:179–183.
- 7 Aneko K, Aoki M, Hattori S, Sato M, Kawana S. Successful treatment of Kimura's disease with cyclosporine. *J Am Acad Dermatol* 1999; 4:893–894.
- 8 Chang AR, Kim K, Kim HJ, Kim IH, Park CI, Jun YK. Outcomes of Kimura's disease after radiotherapy or non-radiotherapeutic treatment modalities. *Int J Radiat Oncol Biol Phys* 2006; 65:1233–1239.