

# Dorsal nasal deformity: an unusual initial presentation of nasal schwannoma

Ahmed S. Elhamshary, Medhat H. Mansour, Kamal Ebeid, Mostafa I. Ammar

Department of Otorhinolaryngology-Head & Neck Surgery, Tanta University Hospital, Tanta, Egypt

Correspondence to Ahmed S. Elhamshary, MSc, Mostafa Fahmy Street 41, Tanta 31111, Gharbeya, Egypt  
Tel: +20 403 322 990;  
e-mail: ahmedelhamshary@yahoo.com

Received 21 September 2014

Accepted 30 September 2014

The Egyptian Journal of Otolaryngology  
2014, 30:367–370

Nasal schwannomas are very rare neoplasms. We present the case of a 54-year-old woman who had dorsal nasal deformity and partial right-sided nasal obstruction over 5 years. Computerized tomography scan of the nose and paranasal sinuses revealed a soft tissue mass in the anterior part of the right nasal cavity with expansion of the overlying nasal bony wall. Complete endoscopic excision of this mass was performed revealing benign schwannoma with no recurrence over 3 years of follow-up. According to the best of our knowledge, this case is the first reported case of a nasal schwannoma presenting with dorsal nasal deformity in the English literature. This case highlights the importance of thorough endoscopic nasal examination in every patient presenting with a dorsal nasal deformity as well as the consideration of nasal schwannoma in the differential diagnosis of a dorsal nasal deformity.

## Keywords:

nasal deformity, neurilemmoma, schwannoma

Egypt J Otolaryngol 30:367–370

© 2014 The Egyptian Oto - Rhino - Laryngological Society  
1012-5574

## Introduction

Schwannomas or neurilemmomas are neurogenic tumors arising from Schwann cells of the neural sheath of the peripheral, cranial, or autonomic nerves [1]. Olfactory and optic nerves cannot give rise to schwannomas because they lack Schwann cells in their sheaths. Between 25 and 35% of all schwannomas occur in the head and neck region. However, fewer than 4% of head and neck schwannomas involve the nasal cavity and paranasal sinuses [2]. Clinically, these tumors usually present like other benign nasal masses with nonspecific symptoms. In a retrospective review of patients with sinonasal schwannomas, headache was the most common chief complaint, followed by unilateral nasal obstruction and epistaxis [3]. In this article, we describe our reported case of a nasal schwannoma presenting initially with dorsal nasal deformity.

## Case report

A 54-year-old woman presented with a 5-year history of progressive dorsal nasal deformity. Three years later, she developed partial right-sided nasal obstruction. No history of nasal trauma was reported. Physical examination revealed that bony dorsal nasal deformity (diffuse prominence of the right lateral bony wall of the nasal pyramid) can be seen and felt (Fig. 1). Nasal endoscopy revealed a pink firm polypoid mass in the right nasal cavity, which originated from the lateral nasal wall very close to the nasal valve angle and anterior to the middle turbinate. Examination data were otherwise irrelevant.

Computerized tomography (CT) scan of the nose and paranasal sinuses showed a rounded soft tissue mass (21×18×16 mm) in the anterior part of the right nasal cavity expanding the overlying lateral bony wall of the nasal pyramid. There was no evidence of bone destruction (Fig. 2).

Preoperative punch biopsy was taken from the mass under local anesthesia revealing schwannoma. As schwannomas can be multiple and bilateral when associated with neurofibromatosis type 2 (NF2) and they are characteristic of NF2, thorough neurologic examination with formal audiologic testing and a gadolinium-enhanced MRI of the brain with thin cuts through internal auditory canals have been performed excluding the presence of vestibular schwannomas, meningiomas, and gliomas. A spinal MRI has not been requested because there were no signs or symptoms suggestive of myelopathy. Ophthalmologic examination was performed to rule out the presence of posterior subcapsular lenticular opacities.

After exclusion of the diagnostic criteria for NF2, the patient was scheduled for endoscopic excision of the mass under general anesthesia. First, uncinectomy with middle meatal antrostomy was performed to expose the mass completely. Thereafter, complete tumor excision including an adequate margin of the surrounding mucoperiosteum was carried out. Finally, frontal sinustomy was performed to allow drilling of the frontal process of maxilla to remove any tumor remnants at the site of attachment.

Histopathological examination of the excised specimen came up with a final diagnosis of benign schwannoma. The examination revealed a soft tissue tumor formed of alternating zones of compact spindle cells arranged in interlacing fascicles (Antoni A) and loose hypocellular zones (Antoni B). The nuclei in the more cellular areas were arranged in a palisaded pattern (Verocay bodies). No evidence of malignancy was found (Fig. 3). Immunoreactivity staining of the tumor cells for S-100 protein was intensely positive (Fig. 4).

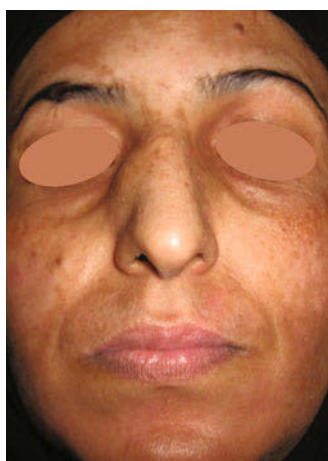The postoperative treatment consisted of antibiotics and nasal douches with endoscopic debridement to remove any nasal crustations during the follow-up visits, which were scheduled once per week for 2 months, and then every 4 months up to 3 years, with no endoscopic evidence of tumor recurrence over the

3-year follow-up. No complications were reported during or after the operation. A signed informed consent has been obtained from the patient for the publication of photographs and data.

### Discussion

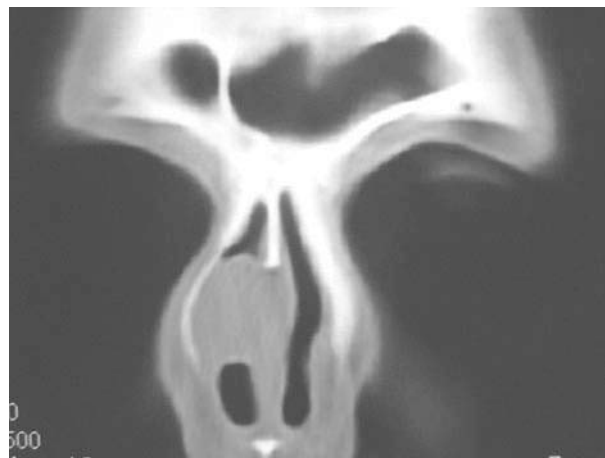Nasal schwannomas are very uncommon neoplasms. They have been postulated to arise from the ophthalmic or maxillary divisions of the trigeminal nerve, the sympathetic fibers from the carotid plexus or the parasympathetic fibers from the sphenopalatine ganglion [4]. However, it is often impossible to identify the nerve of origin at the time of surgery, as was the case in our patient [3].

Figure 1



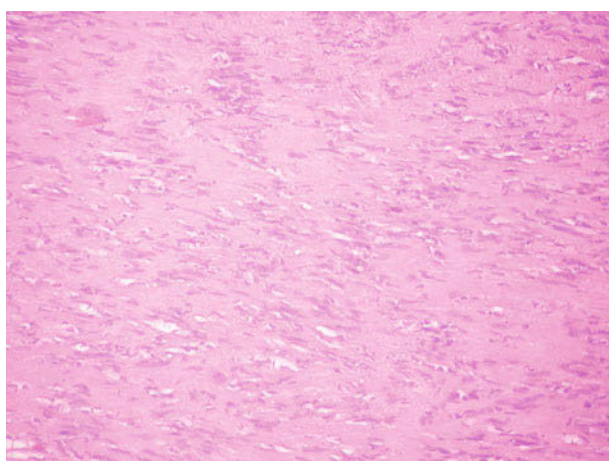
Dorsal nasal deformity of the right lateral wall of the nasal pyramid.

Figure 2



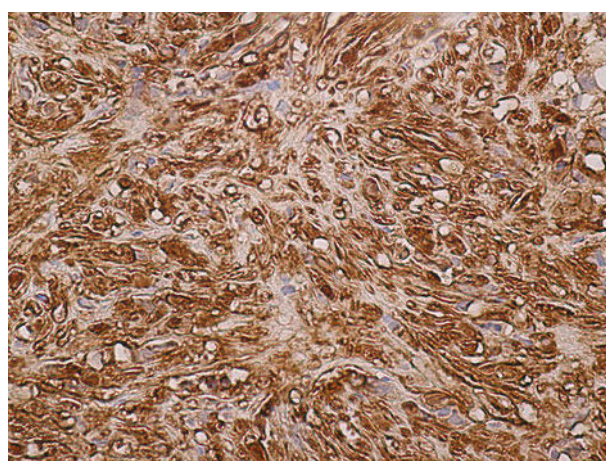
Preoperative computed tomographic scan (coronal view) shows a rounded mass in contact with the nasal septum and expanding the overlying nasal bone.

Figure 3



Histopathological section (hematoxylin-eosin staining, original magnification x200).

Figure 4



S-100 protein immunohistochemical staining (original magnification x400).

Sinonasal schwannomas are manifested with vague and nonspecific symptoms and signs depending on the location and size of the tumor. They are benign slow-growing lesions and invade adjacent structures by bony erosion and direct extension [4]. They rarely undergo malignant transformation. The most common clinical presentations are unilateral nasal obstruction, mucopurulent nasal discharge, hyposmia, facial pain, and recurrent epistaxis. Other less common presentations are exophthalmos, epiphora, or cranial nerve palsies, which may occur with sphenoid schwannomas [5]. As documented in previous reports [6,7] and in our reported case, nasal schwannomas are usually described as polypoid masses of hard to elastic consistency on endoscopic examination. They may be tan-white or red [6].

CT scan is usually sufficient for delineating the extent of benign schwannomas and outlining the bony margins to rule out the invasion [1]. However, MRI is useful for the delineation of intracranial or intraorbital tumor extension and compared with CT, MRI can better evaluate the cause of opacified sinuses (e.g. tumor or inflammation) [8]. In a retrospective review of 12 cases, the characteristic CT and MRI finding of sinonasal schwannoma was a well-defined round, tubular, or partially lobulated soft tissue mass, most frequently an expansile mass with pressure remodeling of the adjacent bony walls. The tumors were isodense on CT scans and predominantly isointense on T1-weighted MR images and isointense to hyperintense on T2-weighted MR images, compared with the brain stem. Mild contrast enhancement on CT scans and marked enhancement on MR images were noted in most of the tumors with characteristic cystic or hemorrhagic degenerative changes especially in large ancient schwannomas [9].

Schwannomas were first described as a pathologic entity by Verocay [10] in 1908. In 1920, Antoni [11] described the histological aspect of this tumor distinguishing two alternating histological patterns: Antoni type A (fasciculated pattern) and type B (reticular pattern). Antoni type A areas are composed of compact spindle cells arranged in short or interlacing fascicles. Areas of nuclear palisading with nuclear alignment in rows are known as Verocay bodies. Antoni type B areas are composed of few spindle cells loosely arranged in a fibrillar myxoid stroma [3]. Intense immunoreactivity staining of the tumor cells for S-100 protein is characteristic of schwannomas (particularly in Antoni type A tissues) due to the high density of Schwann cells [12].

Complete surgical excision is the definitive treatment for schwannomas because of the benign nature of

these tumors and their resistance to radiotherapy. Recurrences are rare after total removal. The surgical approach is determined according to the location and extent of the lesion [3]. Endoscopic endonasal approaches have been successfully implemented in many reports [2–5] to achieve complete excision of the lesion with the advantages of no external scar, shorter hospital stay, and less blood loss, when compared with traditional approaches [3]. Traditional approaches such as lateral rhinotomy, lateral rhinotomy with external ethmoidectomy, Caldwell–Luc, and midface degloving approaches have been used depending on the location and extent of the tumor. Some extensive intracranial tumors require craniotomy [5,7].

Nasal deformity is a very rarely reported presentation of nasal schwannomas. According to a literature review, few cases of nasal tip schwannoma [13,14] presenting as nasal tip deformity and only one case of neurilemmoma of the nasal dorsum [15] in a child presenting as dorsal midline nasal mass have been reported. As far as we know, our patient represents the first reported case of an intranasal schwannoma that initially presents with a bony dorsal nasal deformity. Therefore, the clinician must always have a high index of suspicion with thorough assessment and examination of every patient presenting with dorsal nasal deformity to ensure that this tumor is not missed.

---

## Acknowledgements

### Conflicts of interest

There are no conflicts of interest.

---

## References

- 1 Younis RT, Gross CW, Lazar RH. Schwannomas of the paranasal sinuses. Case report and clinicopathologic analysis. *Arch Otolaryngol Head Neck Surg* 1991; 117:677–680.
- 2 Pasquini E, Sciarretta V, Farneti G, Ippolito A, Mazzatenta D, Frank G. Endoscopic endonasal approach for the treatment of benign schwannoma of the sinonasal tract and pterygopalatine fossa. *Am J Rhinol* 2002; 16:113–118.
- 3 Suh JD, Ramakrishnan VR, Zhang PJ, Wu AW, Wang MB, Palmer JN, Chiu AG. Diagnosis and endoscopic management of sinonasal schwannomas. *J Otorhinolaryngol Relat Spec* 2011; 73:308–312.
- 4 Hegazy HM, Snyderman CH, Fan CY, Kassam AB. Neurilemmomas of the paranasal sinuses. *Am J Otolaryngol* 2001; 22:215–218.
- 5 Cakmak O, Yavuz H, Yucel T. Nasal and paranasal sinus schwannomas. *Eur Arch Otorhinolaryngol* 2003; 260:195–197.
- 6 Dharia A, Karmody CS, Rebeiz EE. Schwannoma of the nasal cavity. *Ear Nose Throat J* 2007; 86:230–231. 243
- 7 Berlucchi M, Piazza C, Blanzuoli L, Battaglia G, Nicolai P. Schwannoma of the nasal septum: a case report with review of the literature. *Eur Arch Otorhinolaryngol* 2000; 257:402–405.
- 8 Dublin AB, Dedo HH, Bridger WH. Intranasal schwannoma: magnetic resonance and computed tomography appearance. *Am J Otolaryngol* 1995; 16:251–254.
- 9 Kim YS, Kim HJ, Kim CH, Kim J. CT and MR imaging findings of sinonasal schwannoma: a review of 12 cases. *Am J Neuroradiol* 2013; 34:628–633.

- 10 Verocay J. Multiple tumors than systemic disease on the nervous system. Festschrift for Chiari. Vienna and Leipzig, Germany: W. Brauriuller; 1908: 378–415.
- 11 Antoni NRE. About spinal cord tumors and neurofibromas. Munich: JF Bergmann publishing house; 1920: 413–423.
- 12 Hillstrom RP, Zarbo RJ, Jacobs JR. Nerve sheath tumors of the paranasal sinuses: electron microscopy and histopathologic diagnosis. Otolaryngol Head Neck Surg 1990; 102:257–263.
- 13 Fujita K, Yuzuriha S, Noguchi M. 'Cyrano de Bergerac' nose deformity caused by the schwannoma of the nasal tip. J Plast Reconstr Aesthet Surg 2006; 59:1252–1254.
- 14 Morrison MP. Nasal tip schwannoma. Ear Nose Throat J 2010; 89: E28–E29.
- 15 Josephson GD, Patel SA, Duckworth L, Kress M, Goldstein J. Neurilemmoma presenting as a midline nasal mass in a pediatric patient. Ear Nose Throat J 2010; 89:221–223.