

# Microdebrider intracapsular tonsillotomy versus conventional extracapsular tonsillectomy

Sherif I. Gabr, Khaled A. Harhash, Mahmoud S. El Fouly, Ahmed A. Kamel, Mostafa M. Eldwebes

Department of Otorhinolaryngology,  
Kasr El Ainy School of Medicine,  
Cairo University, Cairo, Egypt

Correspondence to Ahmed A. Kamel, MD,  
Department of Otorhinolaryngology,  
Kasr El Ainy School of Medicine,  
Cairo University, Cairo 11562, Egypt  
Tel: +20 100 684 6264; fax: 22738896;  
e-mail: kamel\_ent@yahoo.com

**Received** 17 November 2013

**Accepted** 04 January 2014

**The Egyptian Journal of Otolaryngology**  
2014, 30:220–224

## Objective

The aim of the study was to evaluate the efficiency of microdebrider intracapsular tonsillotomy compared with conventional extracapsular tonsillectomy.

## Patients and methods

The study included 40 patients assigned to undergo tonsillectomy. Patients were divided randomly into two equal groups: group A included 20 patients who underwent microdebrider intracapsular tonsillotomy and group B included 20 patients who underwent conventional extracapsular tonsillectomy. Items of comparison between the two groups included time of operation, estimated blood loss, postoperative pain, rate of postoperative hemorrhage, tonsillar fossa healing, swallowing, and complications rate.

## Results

Regarding intraoperative blood loss, the conventional group had significantly lower blood loss ( $P < 0.05$ ). The microdebrider group showed significantly less pain and better swallowing function ( $P < 0.05$ ) than the conventional group. There were no significant differences in operative time or wound healing. No postoperative complications such as recurrence or hemorrhage were detected in either group.

## Conclusion

Microdebrider intracapsular tonsillotomy is an effective method to remove tonsillar tissue. There was significantly less pain and better swallowing function compared with the conventional extracapsular tonsillectomy group.

## Keywords:

comparison, extracapsular, intracapsular, microdebrider, tonsillectomy

Egypt J Otolaryngol 30:220–224

© 2014 The Egyptian Oto - Rhino - Laryngological Society  
1012-5574

## Introduction

Although tonsillectomies historically rank as one of the most common surgical procedures performed, these numbers have steadily declined with the advent of antibiotics since the middle of the 20th century. By 1959, the incidence of tonsillectomy reached its all-time height of 1.4 million operations per year [1].

When performed for the proper indications, tonsillectomies have been shown to improve the patients' quality of life. One such indication is sleep-related breathing disorders attributed to hypertrophic nasopharyngeal lymphoid tissue [2].

In recent years, many new surgical approaches have been explored to refine the art of tonsil removal. Cold dissections with knife, scissors, or snare have been the traditional instruments for tonsillectomies. Electrocautery dissection with its advantage of improved hemostasis has since replaced cold dissection techniques for most surgeons. Direct contact between the tissue and electrodes generates local temperatures of 400–600°C [3].

Not surprisingly, this increased thermal damage to the surrounding tissues from electrocautery results in more postoperative pain, odynophagia, and associated dehydration [4].

Two innovative alternatives used in practice today include the coblator and microdebrider. Both of these techniques can be used to perform intracapsular tonsillectomies, removing ~90% of the tonsillar tissue while leaving a thin rim laterally, thus avoiding disruption of the tonsillar capsule. It is commonly believed that this buffer zone of tissue prevents damage to the surrounding pharyngeal muscles, thereby reducing the severity and duration of postoperative pain [5].

Tissue reduction with the microdebrider is achieved by mechanically shaving the tonsillar tissue from the inferior medial pole proceeding superior laterally, preserving the tonsillar capsule along with a thin rim of tonsillar tissue. No significant heat is generated, thus avoiding any thermal damage to the surrounding tissue [6].

The goal of the present study was to compare outcomes of microdebrider intracapsular tonsillectomy with

those achieved with the conventional extracapsular tonsillectomy.

## Materials and methods

### Patients

Forty children (17 boys and 23 girls ranging from 3 to 10 years) were included in this study. Inclusion criteria include all indications for tonsillectomy. Exclusion criteria were only patients who either had peritonsillar abscess, tumors, or if the patients took preoperative antinociceptive drugs such as paracetamol.

Informed consent was taken from all patients after approval of the study by the ethical committee. All procedures and patient care were performed at ENT Department, Kasr Al Aini Hospital, Cairo University during the period from January 2012 to January 2013.

### Study design

The study was designed as a prospective randomized controlled study. Patients enrolled in this study were randomly allocated into two groups. Group A (20 patients) underwent surgery using the microdebrider intracapsular tonsillectomy method, whereas group B (20 patients) underwent conventional extracapsular tonsillectomy.

### Surgical technique

#### Group A (20 patients)

After general anesthesia using sevoflurane for induction and maintenance, fentanyl 1 µg/kg and paracetamol preparation in the form of peralgan 15 mg/kg intravenous infusion were given for analgesia. The patient was placed in the Rose position. The jaw was opened using a Boyle–Davis mouth gag (Downs Surgical, UK), which was then suspended by Draffin pods (Downs Surgical, UK). The Stryker microdebrider (Hummer TPS Leibinger Shaver; Dearborn Heights, MI, USA) was used with a 3.5-mm straight aggressive blade for intracapsular tonsil removal. We began with the left tonsil with the microdebrider – set to 3000 rpm in oscillating mode – in the right hand. The microdebrider (shaver) was used to resect the tonsil, moving from the inferior to superior pole; this helped prevent blood from obscuring visualization of the anterior and posterior pillars. Dissection proceeded from a medial to lateral direction until the plane of the pillars was reached. At this point, it was generally helpful to further stabilize and control the anterior pillar to maximize tissue removal and minimize injury to mucosa. A Hurd elevator (Downs Surgical, UK) was particularly helpful in this circumstance, as it could also help to medialize the remaining tonsil tissue,

making dissection easier. Dissection was carried down to but not through the capsule of the tonsil. The use of a mirror could facilitate dissection of the superior pole. Care was taken to avoid inadvertent injury to the uvula, which could occur rapidly given the suction associated with the microdebrider. After dissection was completed, hemostasis was achieved using bipolar cauterization of the bleeding points; if bleeding did not stop, then silk suturing was to be performed. The contralateral tonsil was then dissected in an identical manner. Once the procedure was completed, the pharynx was irrigated with sterile normal saline and the mouth gag was allowed to relax. After approximately 1 min, the mouth gag could be reopened and hemostasis could be confirmed. A suction catheter was then passed under direct vision and the hypopharynx was suctioned free of any blood or irrigation fluid that may cause postextubation laryngospasm. The mouth gag was removed and the patient was turned over to anesthesia personnel for extubation.

#### Group B (20 patients)

This group included patients who underwent tonsillectomy using the conventional cold dissection technique. The technique was performed as follows. The anterior pillar was incised with scissors over the superior pole. The appropriate peritonsillar plane was identified and the tonsil was dissected to the lower pole using Henke's dissector (Downs Surgical, UK). The lower pole was ligated using a silk suture and the tonsil was cut with the cold scissors. Hemostasis was achieved using bipolar cauterization of the bleeding points; if bleeding did not stop, then silk suturing is to be performed.

Continuous monitoring of the patients after discharge was carried out by their parents. Postoperative follow-up visits were performed after 1 week, 2 weeks, 1 month, and 3 months. All patients received the same dosage of analgesics for 1 whole week after surgery. In addition, all patients received the same postoperative antibiotics for 5 days.

### Assessment parameters

To compare between the microdebrider and conventional techniques, several operative and postoperative parameters were assessed. Operative data included operative time and estimated blood loss. Postoperative data included postoperative pain, swallowing, wound healing, and complication rate. Operative time was measured in minutes from mouth gag placement to removal. Estimated blood loss was calculated by subtracting the volume of irrigation (debrider+syringe) used from suction canister fluid at the end of the procedure. Pain during recovery was assessed using the

Wong-Baker Faces (Oklahoma City, OK, USA) Pain Rating Scale. A score of 0 means 'no pain', whereas a score of 10 is 'maximal pain'. Postoperative pain was recorded and retrieved 2 weeks postoperatively. Regarding swallowing, the parents were instructed to advance diet as tolerated. The rate of diet advancement from liquid diet to semisolids to solids was recorded until the 7th postoperative day. Wound healing was assessed during the follow-up visit on the 7th and 14th postoperative day, respectively. Any local intraoperative or postoperative complications such as bleeding or infection were documented. In addition, medical complications such as chest infection, dehydration, or nutritional deficiencies were documented (Fig. 1).

### Statistical analysis

Statistical presentation and analysis of the present study were carried out using SPSS v.16 (IBM, Armonk, NY, USA). Descriptive statistics were carried out for all variables, including obtaining mean, SD, and range. The independent samples Student's *t*-test was used for statistical analysis for all our parametric variables. *P* value of 0.05 or less was considered significant, and a *P* value of 0.001 or less was considered highly significant.

## Results

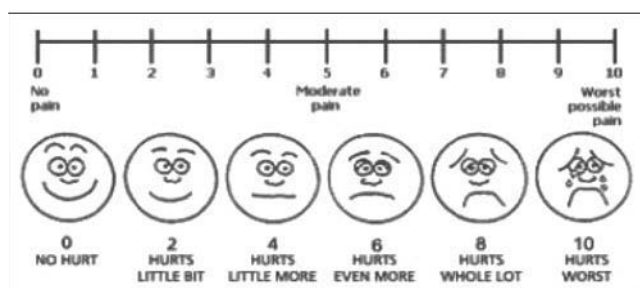
### Demographic data

Regarding the overall patient population, there were 17 boys and 23 girls ranging in age between 3 and 10 years. In group A, there were eight boys and 12 girls. Patients ranged in age between 3 and 10 years, with a mean age of  $6.05 \pm 2.45$  years. However, in group B there were nine boys and 11 girls. Patients ranged in age between 3 and 10 years, with a mean age of  $5.40 \pm 2.58$  years. There was no statistical difference in the ages of both groups ( $P = 0.420$ ).

### Operative time

The mean score for the operative time was 24.50 min in group A as compared with 26 min in group B ( $P = 0.225$ ).

Figure 1



Face Pain Scale [7].

### Intraoperative blood loss

The mean score for the blood lost during the operation was 40.25 ml in group A as compared with 25.00 ml in group B ( $P = 0.006$ ) (Fig. 2).

### Postoperative pain

The mean Faces Pain Rating Scale scores for group A patients were 6.50, 5.90, 4.50, 3.70, 2.70, 1.50, 0.70, 0.00, 0.00, and 0.00 in the first 10 postoperative days, respectively. The mean scores for group B patients were 8.60, 7.10, 6.50, 5.10, 4.50, 3.40, 2.60, 1.50, 0.25, and 0.05 in the first 10 postoperative days, respectively (Fig. 3).

### Swallowing

The mean swallowing scores for group A patients were 1.30, 1.35, 1.95, 2.45, 2.80, 2.95, and 3 in the first 7 postoperative days, respectively. The mean scores for group B patients were 0.70, 1.05, 1.35, 1.90, 2.35, 2.75, and 3 in the first 7 postoperative days, respectively (Fig. 4).

### Wound healing

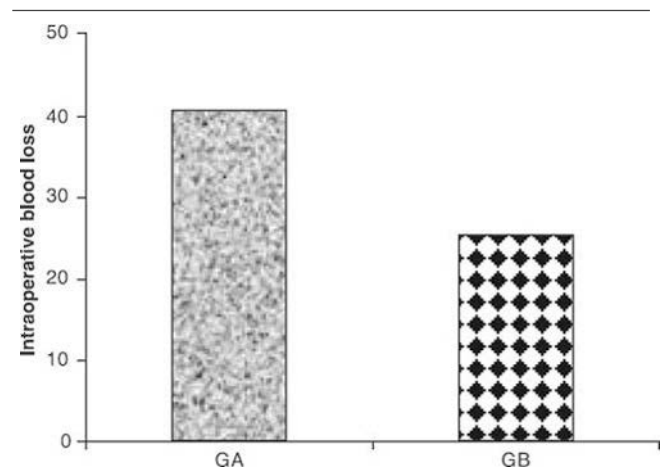
On the 7th postoperative day, the mean percentage of normal pink mucosal lining was found to be 70% of the tonsillar bed in group A as compared with 65% in group B ( $P = 0.195$ ).

On the 14th postoperative day, the mean percentage of normal pink mucosal lining was found to be 95% of the tonsillar bed in group A as compared with 90% in group B ( $P = 0.693$ ).

### Complications

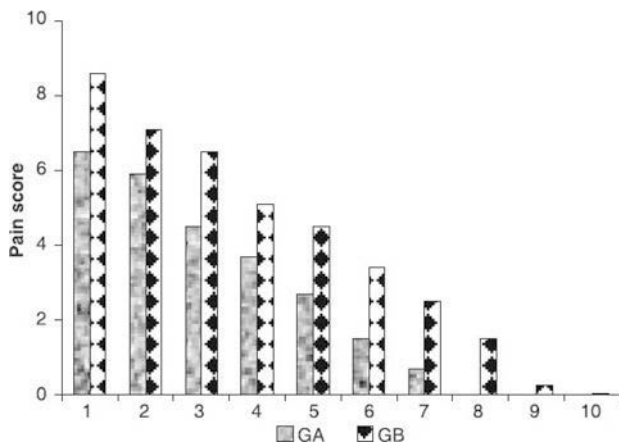
No medical or surgical complications were encountered in either of the two groups.

Figure 2



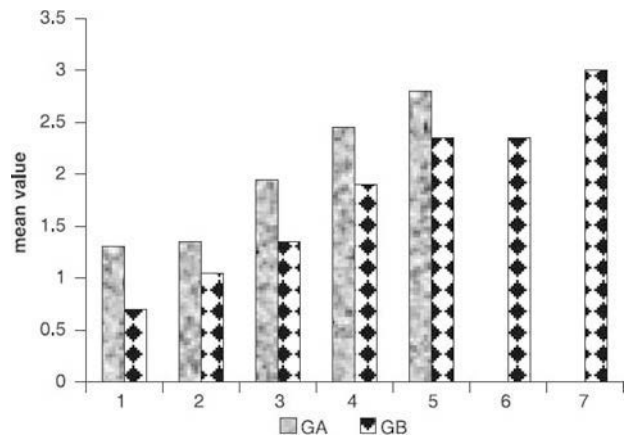
Comparison between the microdebrider intracapsular tonsillectomy (group A) and the conventional extracapsular tonsillectomy (group B) with respect to the operative blood loss.

Figure 3



Comparison between the microdebrider intracapsular tonsillectomy (group A) and the conventional extracapsular tonsillectomy (group B) with respect to the pain score from day 1 to day 10.

Figure 4



Comparison between the microdebrider intracapsular tonsillectomy (group A) and the conventional extracapsular tonsillectomy (group B) with respect to the swallow score from day 1 to day 7.

## Discussion

This prospective, randomized study demonstrates a significant decrease in postoperative pain measured on a validated pain scale and a better swallowing function when microdebrider intracapsular tonsillectomy is performed compared with the conventional extracapsular tonsillectomy.

The tonsillar fossa is bounded anteriorly by the palatoglossal arch (anterior pillar) and posteriorly by the palatopharyngeal arch (posterior pillar). The superior pharyngeal constrictor muscle comprises the lateral boundary. A potential space, the peritonsillar space, bridged by multiple blood vessels and loose areolar connective tissue, separates the lateral constrictor musculature from the so-called tonsillar capsule. This capsule is composed of modified pharyngobasilar fascia with several identifiable folds medially and perforating vessels entering laterally. Fingers of fibrous tissue accompany these vessels and extend deep into the tonsil. As a result, the capsule is densely adherent to the tonsil, making surgical dissection between the two virtually impossible [8].

Given this anatomy, two options exist for tonsillar dissection: extracapsular (in the peritonsillar space) or intracapsular (removing tonsillar tissue medial to the capsule). When extracapsular dissection is performed, the lateral muscular wall of the pharynx is traumatized with a subsequent inflammatory healing response and superinfection by oral bacterial flora. These processes are believed to contribute significantly to post-tonsillectomy pain. If the tonsillar capsule is left undisturbed, it may act as a barrier to such inflammation and infection of the pharyngeal musculature, thereby reducing postoperative pain. Evidence published to date supports this contention [9].

In this study, we used the Wong-Baker Faces Pain Scale, which is a validated pain scale consisting of six faces with expressions ranging from happy to sad. Each face is given a number from 0 to 10. The microdebrider group showed significant less pain in all days postoperatively compared with the conventional group.

Several studies addressed the issue of postoperative pain after tonsillectomy, comparing the intracapsular with the extracapsular tonsillectomies using different surgical techniques. Koltai *et al.* [10] stated that partial tonsillectomy was significantly better than total tonsillectomy with less pain during recovery on days 1–3, days 4–6, days 7–9, and days 9+. Lister *et al.* [11] showed that microdebrider intracapsular tonsillectomy is significantly less painful compared with electrosurgical extracapsular tonsillectomy. Derkay *et al.* [12] and Bitar and Rameh [13] found that children who underwent microdebrider tonsillectomy experienced statistically and clinically significant less pain during the perioperative period.

Return to normal swallowing means earlier recovery and earlier return to normal life and activities. In this study, the return of swallowing function to normal was measured by the type of food that can be easily administered. Clear fluid diet intake was a measure of significant discomfort, whereas the return to normal solid diet was the desired outcome. This outcome was achieved slightly more than 1 day earlier in the microdebrider group.

Koltai *et al.* [10] found that total tonsillectomy patients are about 50% slower to return to normal diet than partial tonsillectomy patients. Mixon *et al.* [14] showed that patients receiving total tonsillectomy

by electrocautery had longer mean time to return to solid food than those receiving total tonsillectomy by harmonic scalpel or subcapsular tonsillectomy by microdebrider.

The amount of wound healing was measured by the percentage of normal mucosal lining covering the tonsillar bed on the 7th and 14th day postoperatively. It was found that there is no significant difference between the two groups regarding wound healing.

Reviewing the literature, no studies were presented with respect to wound healing comparing the two groups.

In this current study, there was no postoperative bleeding or postoperative regrowth or recurrence of symptoms in either the microdebrider or the conventional groups. This can be expected with relatively small number of patients enrolled.

Regarding the blood loss in this current study, the estimated blood loss was 40.25 ml in the microdebrider group as compared with 25 ml in the conventional group. This reflects a significant difference between the two methods in favor of the conventional group.

Mixon *et al.* [14] and Bitar and Rameh [13] showed higher blood loss when the microdebrider was used. However, Koltai *et al.* [10] and Derkay *et al.* [12] showed no significant difference in blood loss between the two methods.

In this current study, operative time was measured in minutes from mouth gag placement to removal. We found no significant difference between the two groups regarding surgical time.

The mean score for the operative time was 24.5 min in the microdebrider group as compared with 26 min in the conventional group.

Derkay *et al.* [12] and Bitar and Rameh [13] reported no significant difference in the operative time. However, both studies used electrocautery for conventional extracapsular tonsillectomy. Mixon *et al.* [14] and Wilson *et al.* [15] in their study comparing different techniques for tonsillectomy found that microdebrider partial tonsillectomy had significantly shorter operative time compared with others.

The use of microdebrider partial tonsillectomy is competing with the conventional total tonsillectomy in many aspects. Comparison in different parameters

showed some advantages for the microdebrider method over the conventional method. These advantages include more rapid recovery with respect to pain and swallowing.

According to our data and statistical analysis, we found microdebrider intracapsular tonsillectomy to be a comfortable, safe, and effective procedure to treat children with tonsillitis. It is quite rewarding during the immediate postoperative period and the improvement seems to last for a prolonged period.

## Acknowledgements

### Conflicts of interest

None declared.

## References

- Grundfast KM, Wittich DJ Jr. Adenotonsillar hypertrophy and upper airway obstruction in evolutionary perspective. *Laryngoscope* 1982; 92:650–656.
- Darrow DH, Siemens C. Indications for tonsillectomy and adenoidectomy. *Laryngoscope* 2002; 112:6–10.
- Maddern BR. Electrosurgery for tonsillectomy. *Laryngoscope* 2002; 112:11–13.
- YuShan LW, David MM, Augustine LM. Comparison of three common tonsillectomy techniques: a prospective randomized, double-blinded clinical study. *Laryngoscope* 2009; 119:162–170.
- Timms MS, Temple RH. Coblation tonsillectomy: a double blind randomized controlled study. *J Laryngol Otol* 2002; 116:450–452.
- Koltai PJ, Solares CA, Mascha EJ, Xu M. Intracapsular partial tonsillectomy for tonsillar hypertrophy in children. *Laryngoscope* 2002; 112:17–19.
- Wong D, Baker C. Pain in children: comparison of assessment scales. *Pediatr Nurs* 1988; 14:9–17.
- Janfaza P, Nadol JB, Galla RJ, Fabian RL, Montgomery WW. *Surgical anatomy of the head and neck*. Philadelphia, PA: Lippincott Williams & Wilkins; 2001.
- C. Arturo Solares, Jeffery A. Koempel, Keiko Hirose, Tom I. Abelson, James S. Reilly, Steven P. Cook, *et al.* Safety and efficacy of powered intracapsular tonsillectomy in children: a multi-center retrospective case series. *Int J Pediatr Otorhinolaryngol* 2005; 69:21–26.
- Peter J. Koltai, C. Arturo Solares, Jeffery A. Koempel, Keiko Hirose, Tom I. Abelson, Paul R. Krakovitz, *et al.* Intracapsular tonsillar reduction (partial tonsillectomy): reviving a historical procedure for obstructive sleep disordered breathing in children. *Otolaryngol Head Neck Surg* 2003; 129:532–538.
- Lister M, Cunningham M, Benjamin B, Williams M, Tirrell A, Schaumberg D. Microdebrider tonsillotomy vs electrosurgical tonsillectomy: a randomized, double-blind, paired control study of postoperative pain *Arch Otolaryngol Head Neck Surg*. 2006; 132:599–604.
- Derkay C, Darrow D, Welch C, Sinacori J. Post-tonsillectomy morbidity and quality of life in pediatric patients with obstructive tonsils and adenoid: microdebrider vs electrocautery *Otolaryngol Head Neck Surg* 2006; 134:114–120.
- Bitar MA, Rameh C. Microdebrider-assisted partial tonsillectomy: short- and long-term outcomes. *Eur Arch Otorhinolaryngol* 2008; 265:459–463.
- Mixon C, Weinberger P, Austin M. Comparison of microdebrider subcapsular tonsillectomy to harmonic scalpel and electrocautery tonsillectomy. *Am J Otolaryngol* 2007; 28:13–17.
- Wilson YL, Merer DM, Moscatello AL. Comparison of three common tonsillectomy techniques: a prospective randomized. *Laryngoscope* 2009; 119:162–170.