

Starplasty: A new design for pediatric tracheostomy

Mostafa I. Ammar, Amr I. Elkawa, Ahmed S. Elhamshary, Kamal Ebeid

Department of Otolaryngology, Tanta University, Tanta, Egypt

Correspondence to Mostafa I. Ammar, MSc, Department of Otolaryngology, Tanta University, El Geish Street 64, 6th floor apartment No. 605, Tanta 31211, Egypt.
Tel.: +20 403140409; mobile: +20 1003911442; e-mail: mostafaammar@med.tanta.edu.eg

Received 01 November 2013

Accepted 24 November 2013

The Egyptian Journal of Otolaryngology
2014, 30:183–187

We are describing a new design of pediatric tracheostomy planned for long periods of time. The procedure entails creating a mature tracheo-cutaneous track through three dimensions Z-plasty design. This technique showed superiority to other currently available techniques in reducing the incidence of tracheostomy complications, specially serious hypoxemia after accidental decannulation. However, this is on the expense of persistence of tracheo-cutaneous fistula after decannulation.

Keywords:

starplasty; pediatric tracheostomy, complications

Egypt J Otolaryngol 30:183–187

© 2014 The Egyptian Oto - Rhino - Laryngological Society
1012-5574

Introduction

Since described by Chevalier Jackson on the eve of the last century [1], the surgical technique of tracheostomy has not witnessed a major change for about ten decades. However, there has been a paradigm shift in the indication for the pediatric tracheostomy from relieving upper airway obstruction to enhancing safety of prolonged ventilatory support planned for many premature neonates and chronically ill infants and children [2,3]. This is obviously attributed to the declining frequency of serious upper respiratory tract infections, with development, standardization, and popularization of the vaccination programs against *Haemophilus influenzae* and *Corynebacterium diphtheriae* together with increased efficacy of antibiotic therapy and safety of endotracheal intubation. Meanwhile, the evolution in pediatric intensive care unit (ICU) care effectively improved the survival of low and extremely low birth weight premature infants, full-term infants born with congenital anomalies, and neurologically impaired infants [4,5]. For many patients who require mechanical ventilation for extended periods, tracheostomy is needed to reduce the incidence of subglottic and tracheal stenosis associated with prolonged intubation, to facilitate bronchial hygiene, to minimize the need for sedation and systemic corticosteroid exposure, and to allow relatively safe attempts of oral feeding or weaning from ventilation assistance [6,7]. Infants with congenital anomalies of head and neck regions would also need tracheostomy with or without minimal respiratory support. Noticeably, recent change in indication for pediatric tracheostomy included patients who tend to be tracheostomized for longer periods of time or even not to be decannulated at all [2].

Complications of tracheostomy include early and late complications [8]. Early complications may be intraoperative hemorrhage or injury to critical anatomic structures, the most important of which is

pleural domes damage leading to pneumothorax or pneumomediastinum [3]. Early postoperative period may also witness serious events including accidental dislodgement, blockage of the tracheostomy tube, or peristomal infection and granulations [4,9]. Interstitial air leakage still can occur even with no pleural trauma because of the design of the tracheostomy techniques that allow direct access of air from the tracheal fenestrae to the facial planes confluent with parietal pleura, leading to pneumothorax or subcutaneous emphysema with positive pressure ventilation [4,10,11]. Late drawbacks of tracheostomy (after 7 days) may be tracheal stenosis, suprastomal collapse, or persistent tracheocutaneous fistula (TCF) after decannulation. It seems that pediatric population in recent tracheostomy settings may be more liable to certain complications. Small calibers of pediatric tracheostomy cannulas are associated with higher risk for obstruction, and more suction maneuvers are usually needed. Accidental displacement of tracheostomy cannula from a fresh track may be life threatening in an infant in clinical environments where caregivers lack the expertise to deal with such situation. With poor illumination, improper positioning, narrow, deep surgical field, and loss of anatomic differentiations in a fresh wound, replacement of the tube is difficult with a risk of passing it into a false track [4,9].

Many surgeons introduced different technical modifications to reduce mortality because of the most concerned complication of tracheostomy, accidental decannulation, in a child in an ICU unit. Anchoring the tracheal wall, on both sides of vertical tracheal incision, to the cervical skin with two silk stay sutures is the most commonly advocated technique to keep the tracheal incision readily open and to facilitate emergency replacement of the tube [12]. The same can be carried out with inferiorly based flap of the tracheal wall, with an advantage of better control of reinsertion of the tube in the right track [13–15]. A wide access for

reintubation was also proposed by resecting a part of the tracheal cartilage to create a circular window in the anterior tracheal wall [16]. However, partial excision of the tracheal cartilage and the flap techniques have been suspected, with no solid evidence, to predispose to delayed tracheal stenosis or suprastomal collapse, which may lead to decannulation failure [14,17].

In this study, we are describing an alternative design for pediatric tracheostomy, first depicted by Koltai [4], based on creating an immediately mature TCF by constructing continuous circumferential mucocutaneous suture line between the cervical skin and the tracheal mucosa through a three-dimensional Z-plasty [4]. ‘Starplasty’ tracheostomy seems to be more fitting for recent pediatric tracheostomy settings by avoiding the majority of drawbacks of other techniques. This technique has been adopted as the standard of care for infants and children intended for tracheostomy for more than 2 months in the department of Otolaryngology — Head and Neck Surgery, Tanta University Hospitals, with initial promising results.

How I do it?

Operative settings

The procedure is performed under general anesthesia with endotracheal intubation. The neck is extended by placing a roll under the shoulders, and the head is stabilized using a doughnut. The cricoid cartilage and the sternal notch are marked.

X-shaped skin incision line

An X-shaped skin incision line is marked (about 1 × 1 cm), centered over a point midway between the cricoid cartilage and the suprasternal

notch, and infiltrated with 1 ml of 1% lidocaine with 1 : 100 000 epinephrine solution. The length of the X arms can be increased for patients more than 1 year old. The incision is made through the skin and the subcutaneous tissue (Fig. 1).

Triangular skin flaps

Triangular skin flaps are raised with further undermining of the skin for about 1 cm beyond the incision. The flaps are then reflected and the subcutaneous fat is removed carefully using cold methods (Fig. 2).

Strap muscles

The strap muscles are incised in the midline and retracted laterally, the thyroid isthmus is incised and ligated if encountered, and the trachea is exposed. The tracheal fascia is dissected from the tracheal wall.

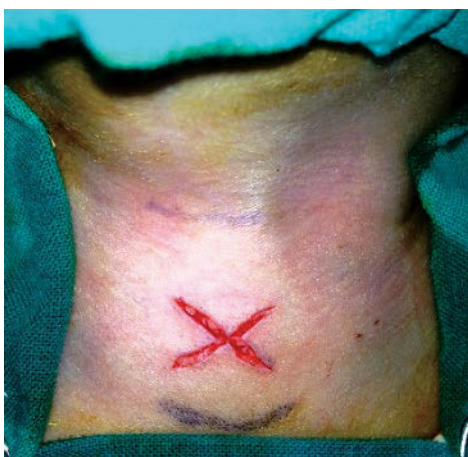Plus (+) shaped incision

On the anterior tracheal wall, plus (+) shaped incision is made with the center opposing and the limbs nearly equal to that of the skin X incision lines (Fig. 3).

The skin flaps are intercalated into the tracheal wall flaps

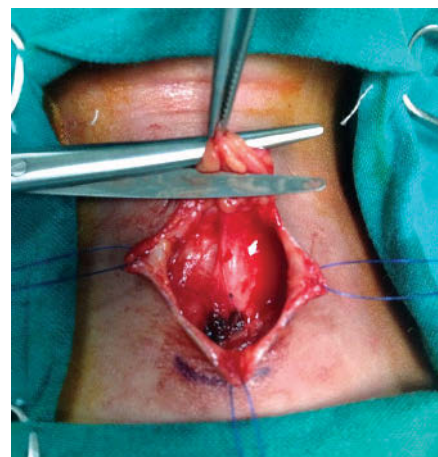
The skin flaps are intercalated into the tracheal wall flaps using half mattress sutures between the apices of the skin flaps and the troughs of the tracheal flaps and between the apices of the tracheal flaps and the troughs of the skin flaps. Absorbable 5-0 sutures are used starting from the skin flap to the tracheal wall and then back through the skin flap (Fig. 4). This creates a star-shaped stoma with a continuous zigzag mucocutaneous junction completely isolating the tracheocutaneous track from the subcutaneous tissue of the neck (Fig. 5).

Figure 1



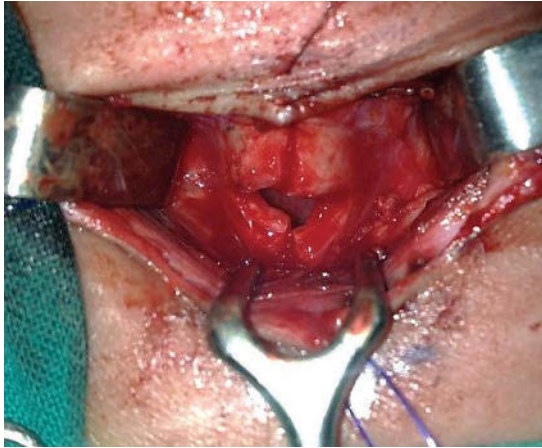Skin incision.

Figure 2



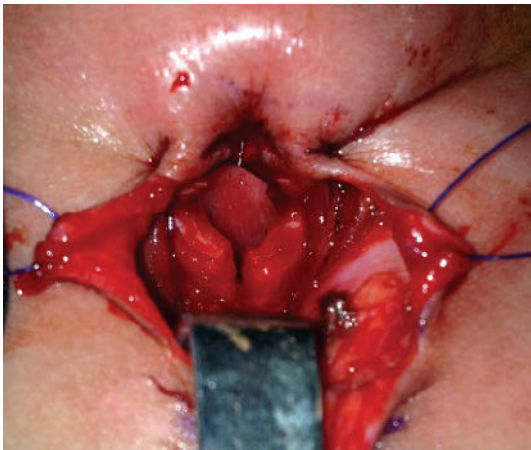
Defatting of the skin flaps.

Figure 3



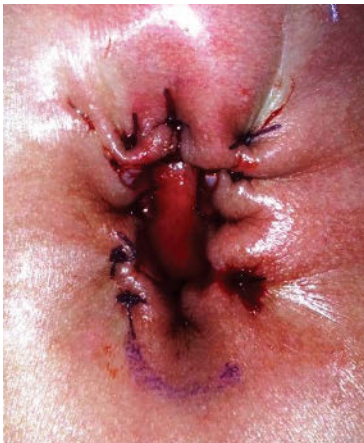Tracheal incision.

Figure 4



Interdigitating skin flaps with tracheal wall flaps.

Figure 5



The star-shaped stoma.

The appropriate size tracheostomy tube

An appropriate size tracheostomy tube can be easily inserted after pulling back the endotracheal tube

under vision. Antibiotic-impregnated bulky dressing is inserted between the stoma and the flanges of the tracheostomy tube, which is secured by soft ribbons around the neck without sutures.

Evaluation of the technique

The fundamental idea of Starplasty is creating a mature track for the tracheostomy tube, which allows secure reintubation and complete separation of the subcutaneous tissue planes of the neck from the airflow and tracheal secretions. This is proposed to decrease tracheostomy-related morbidity and mortality in children and infants on prolonged ventilatory support. Although scarce, the currently available evidence suggests that, among other known techniques, Starplasty may be the most convenient technique for this category of patients. Starplasty does not require special expertise and takes about 30 min to complete.

'Maturation' of the tracheostoma has been considered 'an extra safety measure' performed to facilitate reinsertion of inadvertently dislodged tube, which may be fatal [18]. Many surgeons used stay sutures from the tracheal cartilage to the dermis to secure the track and approximate the tracheal fenestrae to the surface of the neck [9,18,19]. Others used flap techniques [13–15]. Stoma maturation was found effective in preventing serious consequences of accidental decannulation [18,19]. It has also been advisable to reduce peristomal granulation tissue formation, which was considered 'a routine finding' after pediatric tracheostomy and may be a cause of recurrent bleeding, bronchitis, or failure of decannulation [20,21]. However, the persistence of TCF remains a considerable risk of stoma maturation.[4] In a retrospective medical chart review, Colman *et al.* found that stoma maturation in pediatric tracheostomy is associated with a lower rate of accidental decannulation with airway emergency and a higher rate of persistent TCF when compared with the traditional technique; however, these findings were not statistically significant [9].

In our practice, we anecdotally reported that the design of Starplasty provides an immediately mature track for the tracheostomy tube, which enhances the confidence and ability of ICU personnel, novice or trained, to reinsert or replace the tube in case of accidental slippage or total blockage without need for special instrumentation or expert call. Many authors, as well, found that patients who underwent Starplasty had lower incidence of serious hypoxemia with accidental decannulation [4,10,11,22], reflecting the safety of Starplasty as a maturation technique. However, it was, not surprisingly, reported to be

associated with significantly higher rate of persistent TCF after decannulation, which may reach up to 100% [4,11]. As persistent TCF fistula is usually associated with speech, swallowing, and social and hygiene problems [23,24], surgical closure of the fistula is mandated in patients once tracheostomy is no longer needed [25].

'Isolation' of the tracheocutaneous track from the surrounding neck planes is proposed to lower the incidence of surgical emphysema, pneumothorax, wound infection, and granulation. The incidence of pneumothorax and subcutaneous emphysema after pediatric tracheostomy (about 3–6%) was found to be attributed to the surgical design rather than surgical trauma [2,13,14,16,17,26]. Specially, in infants with noncuffed tracheostomy tubes, air under positive pressure can dissect through the fascial planes that may be in continuity with the pleural cavity. This complication was reduced to 0% in published studies on Starplasty so far [4,10,22]. Isolation of the tracheostomy wound from the tracheal secretions was also found to lower the rate of wound infection from 0–15% reported in literature [27] to 0–2.8% reported in Starplasty patient published cohorts [4,10,11]. The presence of a continuous circumferential suture line with no incision lines on both sides of the track minimizes the wound care needed but does not substitute it [4].

Long-term complications of tracheostomy, such as tracheal stenosis and suprastomal collapse of the anterior tracheal wall, may lead to decannulation difficulties and dependence on tracheostomy cannula even after eliminating the initial indication for tracheostomy [21]. Although the underlying mechanisms of such complications are not completely understood, tracheal stenosis is believed to be related to chondritis at the tracheostomy site when compared with the surgical technique [11]. Suprastomal collapse may also be the result of infection along with prolonged pressure on the anterior tracheal wall by tracheostomy tube [4]. These complications were not reported in long-term follow-up in any of the Starplasty published series [4,11,22]. This may be attributed to the low infection rate and special geometrical design, which protects the tracheal wall from direct compression and maintains tendency of the tracheal cartilage to retain previous anatomy after decannulation [4].

Overall tracheostomy-related mortality reported in literature ranges from 1 to 3% [12,14,17,26], whereas no incidence was reported with Starplasty [4,10,11,22]. Although this may reflect the safety of the technique, an incidence above 0% may be obtained with larger studies.

Conclusion

We recommend considering Starplasty design for pediatric tracheostomy for infants and children expected to remain cannulated for 2 months or more. The technique is easy, not technically demanding, and can be performed in about 30 min. On the basis of our limited experience and published reports, Starplasty is a safe and an effective technique in reducing the incidence of serious complications of tracheostomy in pediatric population, especially death due to accidental decannulation. We wish to solidify these recommendations with a case series after accumulating a proper sample size. The only drawback that is apparently outweighed by many advantages is the persistence of TCF after decannulation, which dictates surgical removal.

Acknowledgements

Conflicts of interest

None declared.

References

- Jackson C. Tracheotomy. *The Laryngoscope* 1909; 19:285–290.
- de Trey L, Niedermann E, Ghelfi D, Gerber A, Gysin C. Pediatric tracheotomy: A 30-year experience. *Journal of pediatric surgery* 2013; 48:1470–1475.
- Cochrane LA, Bailey CM. Surgical aspects of tracheostomy in children. *Paediatric respiratory reviews* 2006; 7:169–174.
- Koltai PJ. Starplasty: a new technique of pediatric tracheotomy. *Archives of otolaryngology — head & neck surgery* 1998; 124:1105–1111.
- Overman AE, Liu M, Kurachek SC, Shreve MR, Maynard RC, Mammel MC, et al. Tracheostomy for infants requiring prolonged mechanical ventilation: 10 years' experience. *Pediatrics* 2013; 131:e1491–e1496.
- Keszler M. State of the art in conventional mechanical ventilation. *Journal of perinatology: Official journal of the California Perinatal Association* 2009; 29:262–275.
- Estournet-Mathiaud B. Tracheostomy in chronic lung disease: Care and follow-up. *Pediatric pulmonology* 2001; 23:135–136.
- Line WS, Jr., Hawkins DB, Kahlstrom EJ, MacLaughlin EF, Ensley JL. Tracheotomy in infants and young children: The changing perspective 1970–1985. *The Laryngoscope* 1986; 96:510–515.
- Colman KL, Mandell DL, Simons JP. Impact of stoma maturation on pediatric tracheostomy-related complications. *Archives of otolaryngology — head & neck surgery* 2010; 136:471–474.
- Eliashar R, Gross M, Attal P, Hocwald E, Sichel JY. "Starplasty" prevents tracheotomy complications in infants. *International journal of pediatric otorhinolaryngology* 2004; 68:325–329.
- Solares CA, Krakovitz P, Hirose K, Koltai PJ. Starplasty: Revisiting a pediatric tracheostomy technique. *Otolaryngology — head and neck surgery: Official journal of American Academy of Otolaryngology-Head and Neck Surgery* 2004; 131:717–722.
- Wetmore RF, Handler SD, Potsic WP. Pediatric tracheostomy. Experience during the past decade. *The Annals of otology, rhinology, and laryngology* 1982; 91:628–632.
- Gilmore BB, Jr., Mickelson SA. Pediatric tracheotomy. Controversies in management. *Otolaryngologic clinics of North America* 1986; 19:141–151.
- Hotaling AJ, Robbins WK, Madgy DN, Belenky WM. Pediatric tracheotomy: A review of technique. *American journal of otolaryngology* 1992; 13:115–119.
- Waki EY, Madgy DN, Zablocki H, Belenky WM, Hotaling AJ. An analysis of the inferior based tracheal flap for pediatric tracheotomy. *International journal of pediatric otorhinolaryngology* 1993; 27:47–54.
- Hewlett AB, Ranger D. Tracheostomy. *Postgraduate medical journal* 1961; 37:18–21.
- Gaudet PT, Peerless A, Sasaki CT, Kirchner JA. Pediatric tracheostomy and associated complications. *The Laryngoscope* 1978; 88:1633–1641.

- 18 Craig MF, Bajaj Y, Hartley BE. Maturation sutures for the paediatric tracheostomy — an extra safety measure. *The Journal of laryngology and otology* 2005; 119:985–987.
- 19 Park JY, Suskind DL, Prater D, Muntz HR, Lusk RP. Maturation of the pediatric tracheostomy stoma: Effect on complications. *The Annals of otology, rhinology, and laryngology* 1999; 108:1115–1119.
- 20 Carter P, Benjamin B. Ten-year review of pediatric tracheotomy. *The Annals of otology, rhinology, and laryngology* 1983; 92:398–400.
- 21 Prescott CA. Peristomal complications of paediatric tracheostomy. *International journal of pediatric otorhinolaryngology* 1992; 23:141–149.
- 22 Pucher B, Szydowski J, Ryglewicz M, Grzegorowski M. ["Starplasty" tracheotomy in children of Pediatric ENT Department of Poznan University of Medical Sciences]. *Otolaryngologia polska The Polish otolaryngology* 2013; 67:100–104.
- 23 Bressler KL, Kaiser PC, Dunham ME, Holinger LD. Primary closure of persistent tracheocutaneous fistula in children. *The Annals of otology, rhinology, and laryngology* 1994; 103:835–837.
- 24 Keenan JP, Snyder GG, 3rd, Lehmann WB, Ruiz JW. Management of tracheocutaneous fistula. *Archives of otolaryngology* 1978; 104:530–531.
- 25 Sautter NB, Krakovitz PR, Solares CA, Koltai PJ. Closure of persistent tracheocutaneous fistula following "Starplasty" tracheostomy in children. *International journal of pediatric otorhinolaryngology* 2006; 70:99–105.
- 26 Tucker JA, Silberman HD. Tracheotomy in pediatrics. *The Annals of otology, rhinology, and laryngology* 1972; 81:818–824.
- 27 Kremer B, Botos-Kremer AI, Eckel HE, Schlondorff G. Indications, complications, and surgical techniques for pediatric tracheostomies — an update. *Journal of pediatric surgery* 2002; 37:1556–1562.