

Effectiveness of modified cautery-assisted palatal stiffening operation in controlling snoring

Ussama A. Naseer, Badawy Khalifa, Ahmed Nassar

ENT Department, Cairo University, Cairo, Egypt

Correspondence to Ahmed Nassar, MD, ENT Department, Cairo University, Cairo, 94503, Egypt

Tel: +20 122 290 3321; Fax: 0223595174; e-mail: ahmednassar_79@hotmail.com

Received 14 June 2013

Accepted 02 December 2013

The Egyptian Journal of Otolaryngology
2014, 30:147–150

Objective

The aim of the study was to assess the effectiveness of modified cautery-assisted palatal stiffening operation (CAPSO) to treat snoring.

Patients and methods

Fifty patients with simple snoring underwent the modified CAPSO; patients underwent polysomnography, preoperatively and at 3 months postoperatively.

Results

All patients had improvement in their snoring, and the patients and their sleep partners were satisfied with the result at 3 months postoperatively.

Conclusion

The modified CAPSO technique has shown promising and encouraging results in a small cohort of patients with simple snoring.

Keywords:

apnea, cautery-assisted palatal stiffening operation, snoring

Egypt J Otolaryngol 30:147–150

© 2014 The Egyptian Oto - Rhino - Laryngological Society
1012-5574

Introduction

Snoring is a widespread symptom affecting about 50% of the adult population. Primary snoring without sleep-disordered breathing is not harmful in itself. However, as snoring often causes social embarrassment and marital disharmony, affected patients consult their physicians for treatment [1].

The primary therapeutic aim of all available therapies is a reduction in the duration and intensity of snoring to a tolerable degree without harming the patient. Apart from conservative treatments that require patient compliance to be successful, various kinds of surgical procedures exist, with techniques for the soft palate being the most widespread. All these procedures intend to reduce palatal flutter, the major cause of nonapneic snoring. Uvulopalatopharyngoplasty (UPPP) and laser-assisted uvulopalatoplasty (LAUP) are well known but associated with a significant morbidity. Furthermore, these treatments are invasive, destructive, painful, and irreversible to a certain extent. UPPP even requires general anesthesia.

Therefore, both patients and physicians prefer a minimally invasive and less painful procedure as a primary option for the treatment of snoring [1].

Snoring is caused by the vibration of the structures in the oral cavity and oropharynx – namely the soft palate, uvula, tonsils, base of tongue, epiglottis, and pharyngeal walls. Most authorities would concur that over 80% of snoring is due to palatal flutter,

caused by vibration of the uvula and the soft palate. Hence, it would be conceivable that techniques to stiffen the palate would be beneficial in reducing snoring [2].

The palatal stiffening operation was first introduced by Ellis in 1994 [3] and improvised by Mair and Day in 2000 [4]. Both authors utilized cautery to stiffen the palate. The original cautery-assisted palatal stiffening operation (CAPSO) procedure was based on stripping a ‘diamond-shaped’ area of the mucosa off the soft palate and uvula, with the aid of cautery under local anesthesia [2].

Although good results were reported, the procedure produced a stellate puckered scar on the soft palate that resulted in tenting of the lateral pharyngeal walls, and therefore narrowing of the lateral distance between the tonsillar pillars. These anatomic manifestations may explain why some patients did not have any clear benefit from the procedure [2].

Several of the newer methods involve the use of expensive implants or sophisticated equipment. The ideal technique would be an office-based procedure that would require no special equipment or implants and would achieve effective results in a reliable and predictable manner [2].

The aim of this study was to evaluate the efficacy of modified CAPSO in controlling snoring and mild sleep apnea.

Patients and methods

The study included 50 patients presenting with snoring in El Kasr El Eini Hospital, Cairo University, who were aged more than 18 years, had BMI less than 33, tonsil size grades 1 and 2, elongated uvula, all Mallampati grades, minimal base of tongue collapse (<25%) as seen on Muller's maneuver, and were simple snorers. Exclusion criteria were patients with large tonsils (grades 3 and 4), history of tonsillectomy, obstructive sleep apnea (OSA), BMI more than 33, and nasal obstruction.

Clinical assessment including a thorough physical examination, nasoendoscopy, and overnight attended polysomnography was performed.

Complete history taking from patient and sleep partner was carried out.

Examination included height, weight, neck circumference, BMI, blood pressure, and assessment of the nasal cavity, posterior nasal space, oropharyngeal area, soft palatal redundancy, uvula size and thickness, tonsillar size, and Mallampati grade.

Flexible nasoendoscopy was performed for all patients, and collapse during a Muller's maneuver was graded for the soft palate, lateral pharyngeal walls, and base of the tongue on a five-point scale.

Monitoring during polysomnography included an electroencephalogram, electro-oculogram, electromyogram of the chin, ECG, body position, nasal and oral airflow, thoracic and abdominal effort, limb movement, pulse oximetry, and snoring sound level.

Complete sleep staging was performed, and polysomnographic variables evaluated included sleep parameters, sleep time, sleep latency, sleep efficiency, rapid eye movement and nonrapid eye movement events, arousals, respiratory events apnea hypopnea index (AHI), oxygen desaturation, snoring level, body position, and limb movements.

- (1) For topical anesthesia of the palatal region, a total volume of 3 ml of 1 : 100 000 adrenaline and 2% xylocaine was injected into three sites of the soft palate.
- (2) Using a guarded needle-tip Bovie electrocautery device, an uvulectomy was performed.
- (3) Bilateral vertical trenches were created on either side of the uvula through both soft palatal arches through the mucosa and muscle.
- (4) A horizontal rectangular strip of mucosa was removed from the soft palate (50 mm in length, 7 mm in width) down to the muscle layer.
- (5) Hemostasis was achieved with electrocautery.

Figure 1 shows the steps of the procedure.

Informed consent from all patients and ethical approval from the ethical committee (Cairo University) were obtained.

Results were assessed after 3 months of the procedure.

The outcome measures included subjective improvement in snoring on the basis of the visual analog scale (VAS) and improvement in sleepiness as indicated by the Epworth scale. Objective changes were presented by the polysomnographic findings.

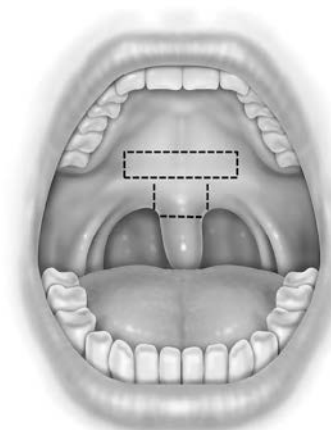
Results

Fifty patients were chosen to undergo the modified CAPSO procedure for management of their snoring. Of the 50 patients, 29 were men and 21 were women, with a mean age of 40.2 years (range 28–53 years). The mean BMI was 29.8 (range 26.2–32.6). All patients were classified as Friedman stage II and III, with tonsil size 0, 1, or 2.

The mean operative time was 12.5 min (range 10–15 min). There were no complications; specifically, there were no patients with velopharyngeal incompetence, fistula, or primary or secondary hemorrhage. All patients (50/50) had improvement in their snoring, and the patients and their sleep partners were satisfied with the result at 3 months postoperatively. The VAS showed gradual reduction in the snoring intensity with time, ranging from a preoperative level of 10–3 (range 1–5) at 90 days postoperatively.

Objective polysomnographic success was noted in 40 (80%) patients.

Figure 1



Steps of modified cautery-assisted palatal stiffening operation.

The lowest oxygen saturation improved from 88.3 to 92.5%.

Improvements were seen in the Epworth scale, which decreased from 12 to 9 postoperatively.

Subjectively, many patients felt that during night, they experienced more dreams during their sleep and much less choking sensation and gasping for air. Pain was the most common complaint. The procedure itself was painless; however, the VAS revealed significant pain, which reached a maximum on day 2 (mean 8.6; range 7.3–9.1). The pain score improved to a mean of 2.2 (range 1.8–3.6) at day 14. Most patients consumed all of their prescribed analgesics.

Figures 2 and 3 show postoperative results.

Discussion

Stiffening the soft palate to diminish extensive snoring is not a new idea. As early as 1852, surgeons from the UK performed midline intrapalatine resection of the soft palate mucosa and muscle with primary closure to achieve tightening of the soft palate. In 1943, Strauss [5] described a palatal ‘flutter ratio’ and proposed placing a scar along the soft palate to stiffen the floppy palate.

The application of office-based laser technology to surgery for snoring and mild OSA led to the introduction of LAUP in the middle to late 1980s. Since then, controversies have arisen, especially with respect to its efficacy. Kamani [6], who is credited with the introduction of LAUP, published data showing remarkable results for its use as treatment for both snoring and OSA. Similar short-term results were published by other authors using either a single-stage

or multiple-stage LAUP procedure [7]. Published data tend to contradict earlier results with patients showing poorer results or results that worsened with time [8].

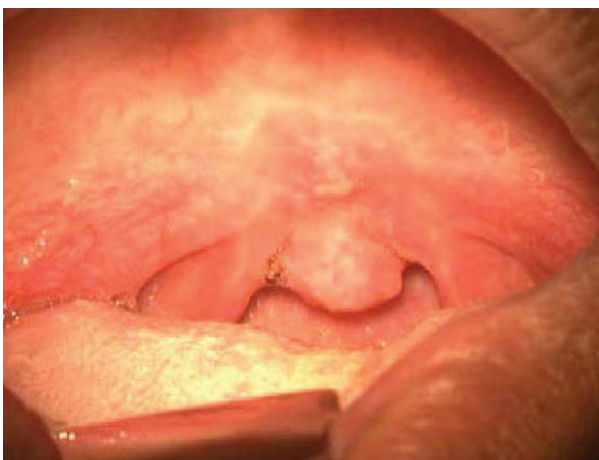Patient selection is prudent; patients who are simple snorers and patients with mild obstructive sleep apnea, with palatal flutter and/or obstruction, with small tonsils, and BMI less than 33 will be benefited from the modified CAPSO technique.

Mair and Day [4] reported a 77% success rate for reduction in snoring in 206 patients, at 1 year, who underwent the CAPSO.

Wassmuth *et al.* [9] showed in a study that CAPSO provides an equally effective surgical option compared with UPPP or LAUP for the treatment of snoring. The advantages of CAPSO include avoidance of general anesthesia, hospitalization, and expensive laser systems. A single 10-min clinic procedure virtually eliminates the bleeding and velo-pharyngeal incompetence (VPI) morbidity often associated with treatment of obstructive sleep apnea syndrome (OSAS) at the palatal level [9].

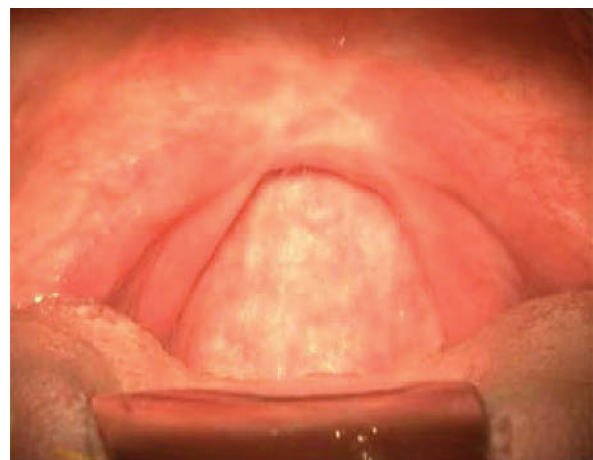We achieved promising results in a small cohort of simple snorers and in patients with mild OSA. Not only were there improvements in the VAS for snoring, but also most of the sleep partners were happy with the reduction in snoring intensity at 90 days after the procedure. Subjectively, many patients reported improvements in daytime sleepiness and felt that they were no longer tired during the day. The frequency of choking sensation and gasping at night had also reduced. We believe that the results reflect the scarring and fibrosis of the soft palate and the ‘pull’ of the scar superiorly that shortens and stiffens the soft palate. The effect is also enhanced by the shortening of the soft

Figure 2



Postoperative results.

Figure 3



Postoperative results.

palate, which increases the anteroposterior distance of the velopharynx.

There are a number of advantages of this procedure. It is anatomically sound (because it causes scarring superiorly), and it can be performed as an office-based procedure on an outpatient basis. The procedure is brief, has low cost, and does not require expensive implants. It is performed in a single session with excellent results and a low complication rate. The main disadvantage is the amount of pain incurred during the postoperative period; this is overcome adequately with narcotic and non-narcotic medication.

Conclusion

The modified CAPSO technique has shown promising and encouraging results in a small cohort of patients with simple snoring and mild OSA.

It is a single office procedure that does not rely upon expensive laser systems or generators and handpieces.

Acknowledgements

Conflicts of interest

None declared.

References

- 1 Maurer JT. Palatal implants for primary snoring: Short- and long-term results of a new minimally invasive surgical technique. In: Friedman M, (editor). *Sleep apnea and snoring: surgical and non-surgical therapy*. Elsevier Saunders; 2009. 169–175.
- 2 Pang KP, Terris DJ. Cautery-assisted palatal stiffening operation. In: Friedman M, (editor). *Sleep apnea and snoring: surgical and non-surgical therapy*. Elsevier Saunders; 2009. 159–164.
- 3 Ellis PDM. Laser palatoplasty for snoring due to palatal flutter: a further report. *Clin Otolaryngol Allied Sci* 1994; 19:350–351.
- 4 Mair EA, Day RH. Cautery-assisted palatal stiffening operation. *Otolaryngol Head Neck Surg* 2000; 122:547–555.
- 5 Strauss JF. A new approach to the treatment of snoring: a preliminary report. *Arch Otolaryngol* 1943; 38:225–229.
- 6 Kamami Y-V. Outpatient treatment of sleep apnea syndrome with CO2 laser: laser-assisted UPPP. *J Otolaryngol* 1994; 23:395–398.
- 7 Neruntarat C. Laser-assisted uvulopalatoplasty: short-term and long-term results. *Otolaryngol Head Neck Surg* 2001; 124:90–93.
- 8 Ryan CF, Love LL. Unpredictable results of laser assisted uvulopalatoplasty in the treatment of obstructive sleep apnoea. *Thorax* 2000; 55:399–404.
- 9 Wassmuth Z, Mair E, Loube D, Leonard D. Cautery-assisted palatal stiffening operation for the treatment of obstructive sleep apnea syndrome. *Otolaryngol Head Neck Surg* 2000; 123:55–60.