

Morphological and electron microscopic effects of mitomycin C inhalation in experimentally induced laryngeal fibrosis in dogs

Mohamed T. El Tabbakh^a, Mohsen Mohamed Hassan Mostafa Zagholol^c,
Adel R. Hinnis^d, Zinab Abdel-Hady^b

^aOtolaryngology — Head and Neck Surgery Department, ^bHistology Department, Faculty of Medicine, ^cSurgery, Radiology and Anesthesiology Department, Faculty of Veterinary Medicine, ^dPathology Department, Suez Canal University, Ismailia, Egypt

Correspondence to Mohamed T. El Tabbakh, MD, Otolaryngology — Head and Neck Surgery Department, Faculty of Medicine, Suez Canal University, 41522, Egypt
Tel: +20 100 510 8110; +20 643 208 543;
e-mail: abolobna2@gmail.com

Received 27 June 2013

Accepted 02 December 2013

The Egyptian Journal of Otolaryngology
2014, 30:126–131

Purpose

This study was carried out to investigate the morphological and ultrastructural effects of mitomycin C in the inhalational form on induced laryngeal tissue injuries and fibrosis.

Materials and methods

This study was carried out on 17 cross-breed clinically healthy dogs. Three dogs were included in a normal control group. The rest of the 14 dogs were subjected to induction of laryngeal fibrosis and assigned randomly to two equal groups: one treated with inhalational mitomycin C and the other was an untreated control group. Tissue biopsies were studied after H&E and Masson's trichrome stains, whereas other pieces were examined by electron microscopy.

Results

Epithelial ulceration with marked inflammatory infiltration, edema, and congestion was evident in all experimented dogs. There was a significant difference in epithelial hyperplasia between the treated and the untreated groups; it was markedly reduced in the treated group. The untreated group showed extensive well-organized fibrosis that was significantly increased compared with the other groups. Results were confirmed by electron microscopy.

Conclusion

Inhalation of mitomycin C has a potent antifibrotic effect through decreasing the activity of fibroblast evident by the decrease in both the size of fibroblast and the density of the intrafibroblast endoplasmic reticulum.

Keywords:

electron microscope, inhalational mitomycin C, laryngeal fibrosis

Egypt J Otolaryngol 30:126–131

© 2014 The Egyptian Oto - Rhino - Laryngological Society
1012-5574

Introduction

Although many strategies had been used in the treatment of laryngotracheal stenosis, there are no 100% standard methods that can be used for the treatment of such a disabling and potential fatal disease, which affects breathing, phonation, and sometimes the swallowing process [1]. Using less invasive surgery and decreasing the incidence of restenosis and formation of another cicatricial tissue are the main goals of any method of intervention in the treatment of such an incapacitating disease [2]. The use of mitomycin C as an antiproliferative drug helped postpone restenosis of the fibrosed laryngotracheal lesion when applied topically for a longer duration; even when applied topically twice, 3–4 weeks apart, restenosis occurs after 3–5 years [3]. The idea of topical application seems attractive, but the need for general anesthesia and repeated direct laryngoscope and bronchoscope limit the number of topical applications to a degree that the effect of mitomycin C is limited to a few months to years, with the resultant restenosis and reappearance of symptoms [4]. The idea of using topical mitomycin C in the inhalational form could serve two purposes at the same time: one is topical application and second is the multiple easy exposures to the effect of mitomycin C without the need for general anesthesia. Thus, there may be a possibility of

maintaining the effect of the surgical intervention for a prolonged time with regular exposure to inhalational mitomycin C in the form of nebulizer settings [5].

Despite the potential benefit of the inhalational method, systemic side effects from the repeated exposure to mitomycin are still poorly studied in the literature [6]. Published experimental studies on inhalational mitomycin on a canine model concluded that there are no local or systemic toxic effects of using inhalational mitomycin at a concentration of 0.5 mg/ml in a 1 ml saline solution for inhalational settings after 14 and 28 days, respectively [7]. Thus, in the current study, we used the same protocol for topical mitomycin application and we focused on the detailed pathological changes that occur after mitomycin C applications in order to identify the morphological and ultrastructural effects of mitomycin C on the affected laryngeal tissue using an electron microscope in addition to the usual H&E stain and Masson's trichrome stain.

Materials and methods

Design

This study was carried out on 17 cross-breed clinically healthy dogs (nine males and eight females) of varying

body weights from 13 to 18 kg; their age ranged from 2.5 to 3.5 years. Three dogs were included in a normal control group. The rest of the 14 dogs were subjected to induction of laryngeal fibrosis and followed up for 2 weeks according to Spector *et al.* [3] until clinical and endoscopic assessment of laryngeal fibrosis was performed. Then, the dogs were assigned randomly to two equal groups: one group was treated with inhalational mitomycin C and the other one was left untreated. After another 2 weeks, all dogs were euthanized, and larynxes were excised and processed for histopathological and electron microscopic examination of the lesions.

Animals' preparation

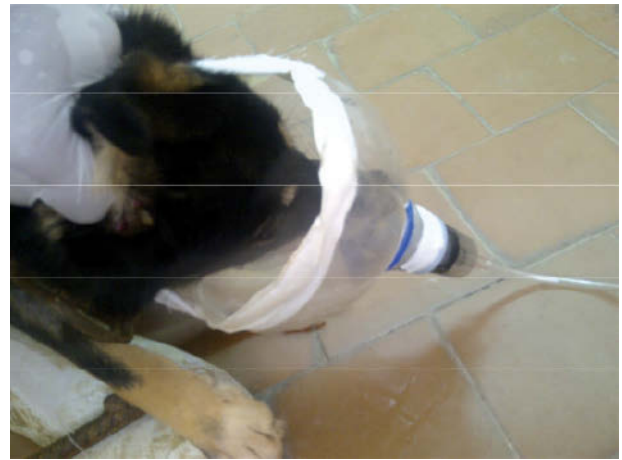Animals were housed in the animal house of the Surgery, Radiology and Anesthesiology Department, Faculty of Veterinary Medicine, Suez Canal University. The animals were maintained under controlled conditions and received human care in compliance with the guidelines of the Scientific Ethical Committee, Faculty of Veterinary Medicine, Suez Canal University. All dogs were fasted overnight before operations, and then premedicated with an intramuscular injection of chlorpromazine hydrochloride at a dose of 1 mg/kg. General anesthesia was induced by an intravenous injection of thiopental sodium 2.5% at a dose of 20 mg/kg body weight until the main reflexes had subsided. Larynxes of the operated dogs were exposed to a monopolar diathermy injury at four equally spaced sites (at 12, 3, 6, and 9 o'clock, respectively) anterior, posterior, right, and left midcordal by hitting the former sites for a 5 s duration with a power of 70% [8]. Intravenous fluids for the first 24 h as well as tramadol hydrochloride (Tramal) 100 mg and cefotaxime (Cefotax) 0.5 g/12 h were administered intramuscularly for 3 and 5 successive postoperative days, respectively. Dogs were observed for signs of tracheal obstruction, stridor, tachypnea, and changes in parking sound for 2 weeks postoperatively.

The drug and method of treatment

The mitomycin C used in this study was in the injection form that is available commercially (Kyowa; Biochem Pharmaceutical Industries Ltd, Mumbai, India) at a concentration of 10 mg. The dose was prepared as 1 ml mitomycin C of 0.5% concentration mixed with 1 ml distilled water, placed in a solution container of a portable nebulizer model (Porta-Neb; Medi-Aid, Evergreen Industries, Wigan, UK); the nebulizer was modified by attaching the tube to a container that fits the dog's head (Fig. 1).

The treatment sessions were three times per week for 2 successive weeks. Dogs were euthanized to obtain

Figure. 1



The modified container attached to the nebulizer apparatus to fit the dog's head.

specimens for histopathological assessment of the laryngeal lesions for both the treated and the untreated group.

Histopathology

Specimens (from the experimented dogs at the end of the experiment as well as from the normal dogs) were taken from the vocal cords as well as from grossly detected lesions, fixed in 10% neutral-buffered formalin solution, and prepared for light microscopic examination by processing through graded alcohols and embedding in paraffin blocks. Thick sections (5 μ m) were cut and stained by H&E, Masson's trichrome.

Sections were examined by light microscopy for evidence of pathological changes and degree of fibrosis in the study groups.

Quantitative measurements were carried out using the image analyzer (Super eye; Heidi Software) to measure the epithelial thickness in H&E-stained sections, the optical density, and the color area percentage of the green color (collagen fibers) in Masson's trichrome-stained sections. The image analyzer was calibrated for distance and color before use. Thirty fields, at least, were captured and analyzed for each group.

Electron microscope

Small tissue pieces from the vocal cords and laryngeal lesions of each animal were excised for electron microscopy. It was trimmed in the presence of glutaraldehyde into pieces a few millimeters in thickness. These specimens were immediately fixed in a 2.5% glutaraldehyde solution at 4°C for 24 h, and then washed overnight in several changes of 0.1 mol/l

sodium phosphate buffer, pH 7.4, at 4°C. They were later postfixed in 2% osmium tetroxide in 0.1 mol/l sodium phosphate buffer, pH 7.4, at room temperature. Specimens were dehydrated in ascending grades of cold ethanol and propylene oxide then embedded in Spurr's resin. Ultrathin sections (50 nm) were prepared on a Reichert—Jung ultracut microtome and subsequently stained for 10 min with 3% aqueous uranyl acetate and for 10 min in lead citrate. Sections were then examined and photographed using a Philips 400 transmission electron microscope.

Results

Clinically, animals survived well until the end of the experiment without recorded mortality. The symptom started one day after induction of the laryngeal injury. The parking sound of the dog becomes progressively lower and complete loss of the parking sound after 2 days. Endoscopic examinations showed massive interarytenoid adhesions and posterior web formation (Fig. 2).

Histopathological findings

Examination of H&E-stained sections from the normal control group showed a normal vocal cord that had a unique multilayer structure (Fig. 3a). The most superficial layer was nonkeratinized stratified squamous epithelium (Fig. 3b). This layer is extremely thin, about 5–9 cells thick (Fig. 3c), and this confers the vocal folds the glistening white appearance observed during a laryngoscopic examination. The mean epithelial thickness in this group was 7.342 ± 1.014 (Table 1). Deep to this layer is the lamina propria,

which is composed of three layers. The superficial layer of the lamina propria consists of loose fibrous components and extracellular matrices that can be compared with soft gelatin. The intermediate layer of the lamina propria is primarily made up of elastic fibers, whereas the deep layer of the lamina propria is primarily made up of collagenous fibers and these two layers of the lamina propria comprise the vocal ligament. Deep to the deep lamina propria is the vocalis muscle. This muscle makes up the bulk of the vocal fold. The untreated group showed extensive epithelial hyperplasia with markedly increased epithelium thickness (Fig. 4a–c). The mean epithelial thickness in this group was 15.472 ± 0.0157 (Table 1). A section from the treated group showed epithelial ulceration with massive inflammatory infiltration and edema of the lamina propria. Hypervascularity, congestion, and mild epithelial hyperplasia were also observed in the same group (Fig. 4d). The mean epithelial thickness in this group was 9.123 ± 0.0148 (Table 1).

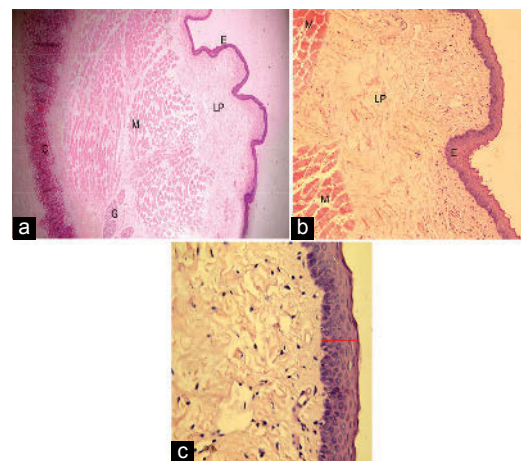
Table 1 Mean and SD of epithelial thickness in the experimental groups

Groups	Mean \pm SD
Control	7.342 ± 1.014
Untreated	$15.472 \pm 0.0157^*$
Treated	$9.123 \pm 0.097^*$

*Statistically significant compared with the normal group; $P < 0.01$.

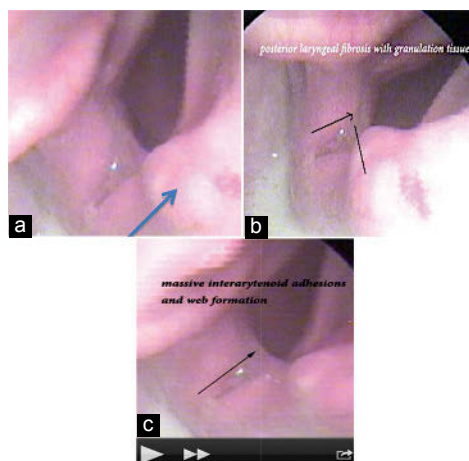
*Statistically significant compared with the untreated group; $P < 0.001$.

Figure 3



Photomicrograph of the control group. (a) Normal multilayered structure of the vocal cord with epithelial covering (E) and lamina propria (LP) with a few mixed glands (G). Deep to lamina propria, vocalis muscles (M) and cartilage (C) were also observed supporting the wall of the larynx (H&E $\times 100$); (b) of previous section magnification showed mucosa of normal vocal cord composed of stratified squamous nonkeratinized epithelium (E), lamina propria (LP), and vocalis muscles (M), which makes up the bulk of the vocal cord (H&E $\times 100$); (c) higher magnification of the previous section showed stratified squamous nonkeratinized epithelium, which was very thin, formed of 5–9 cell thick E (H&E $\times 400$).

Figure 2



Endoscopic images showed fibrosis, adhesions, and posterior web formation after initial induction of fibrosis in the experimental dogs (arrows point to the granulation tissue formation).

With Masson's trichrome stain, the control group showed a normal vocal cord with fine delicate collagen fibers in the lamina propria (Fig. 5a). The mean color area percentage of collagen in this group was 0.13 ± 1.014 (Table 2). The mean optical density of collagen in this group was 0.05 ± 1.014 (Table 3). The mitomycin C-treated group showed a mild increase in collagen fibers in the lamina propria (Fig. 5b). The mean color area percentage (Table 2) and the mean optical density of collagen (Table 3) in this group were 0.17 ± 0.097 and 0.07 ± 0.097 , respectively. The untreated group showed extensive well-organized fibrosis that completely replaced the lamina propria (Fig. 5c). The mean color area percentage (Table 2) and the mean optical density of collagen (Table 3) in this group were 0.26 ± 0.0157 and 0.13 ± 0.0157 , respectively.

Table 2 Mean and SD of color area percentage of green collagen in the different experimental groups

Groups	Mean \pm SD
Normal	0.13 ± 1.014
Untreated	$0.26 \pm 0.0157^*$
Treated	$0.17 \pm 0.097^*$

*Statistically significant compared with the normal group; $P < 0.01$.

*Statistically significant compared with the untreated group; $P < 0.001$.

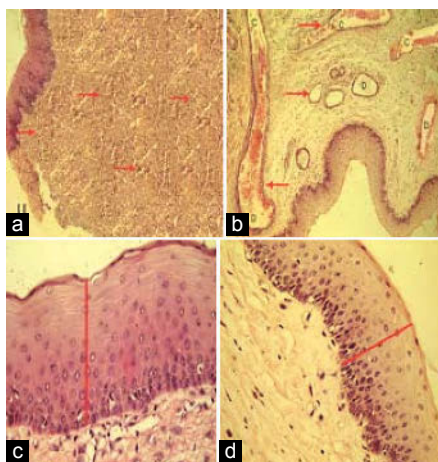
Table 3 Mean and SD of optical density of green collagen in the different experimental groups

Groups	Mean \pm SD
Normal	0.05 ± 1.014
Untreated	$0.13 \pm 0.0157^*$
Treated	$0.07 \pm 0.097^*$

*Statistically significant compared with the normal group; $P < 0.01$.

*Statistically significant compared with the untreated group; $P < 0.001$.

Figure 4

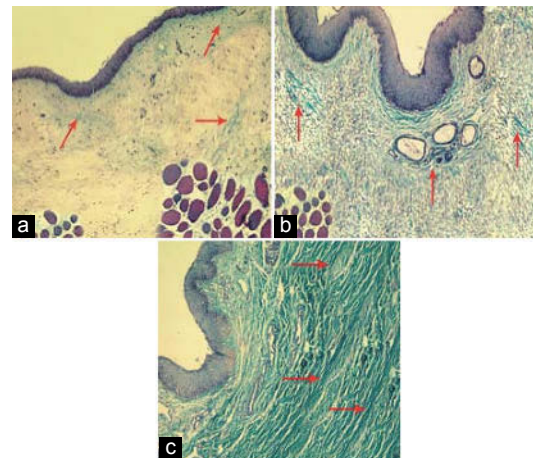


Untreated group showed (a) epithelial ulceration (U) with massive inflammatory infiltration (red arrows) and edema of the lamina propria (black arrows); (b) hypervascularity (arrows), congestion (c), and capillary dilatation (d); (c) showed extensive epithelial hyperplasia with massive increased epithelium thickness (e); (d) mitomycin C-treated group showed mild epithelial hyperplasia with mildly increased epithelium thickness (f) (H&E $\times 100$).

Electron microscopy

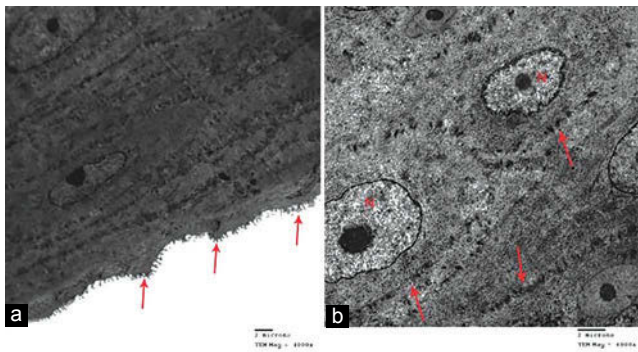
The electron microscopic study, in normal dogs, showed normal vocal cord epithelium with juxtaposed cells and distal prominent microvilli (Fig. 6a). Detailed structure of the epithelium showed cells with an open face, elongated nucleus, and visible nucleolus. Cells were attached to each other by firm intercellular junctions (Fig. 6b). Electron microscopic observations of the untreated group confirmed the results obtained from light microscopy. A constant ultrastructural finding in all specimens in this group was hyperplastic epithelium with intercellular junction enlargement (Fig. 7a). The space between them was filled by amorphous material, damaging the natural contact between them, pushing them apart, and altering the desmosome structure (Fig. 7b). Extensive fibrosis was also observed associated with marked proliferation of fibroblasts (Fig. 7c). Active fibroblast had a large rounded appearance associated with an open face nucleus and distended with well-developed rough endoplasmic reticulum (RER). Also, it was heavily surrounded by extensive dense collagenous bundles in the superficial layer of the lamina propria (Fig. 7d). The treated group did not show a major ultrastructural difference from the control group apart from a mild increase in epithelial thickness with mild enlargement of the intercellular junction (Fig. 8a) without alteration in the desmosome structure (Fig. 8b). This group also showed a marked reduction in fibrosis with marked inhibition of fibroblast proliferation (Fig. 8c) compared with the untreated group. Fibroblasts were fewer in number, associated with a significant change in shape, where it became more spindle like with a dense nucleus and

Figure 5



(a) Control group showed a normal vocal cord with delicate fine collagen fibers in the lamina propria (arrows); (b) mitomycin C-treated group showed a mild increase in collagen fibers in the lamina propria (arrows) (Masson's trichrome $\times 100$); (c) untreated group showed extensive well-organized fibrosis that completely replaced the lamina propria (arrows).

Figure. 6



Electromicrograph of the control group showed (a) normal vocal cord epithelium with juxtapsed cells and distal microprojections (arrows) ($\times 4000$). (b) Detailed structure of the epithelium showed cells with an open face, elongated nucleus (N), and a visible nucleolus. Cells were attached to each other by firm intercellular junctions (arrows) ($\times 6000$).

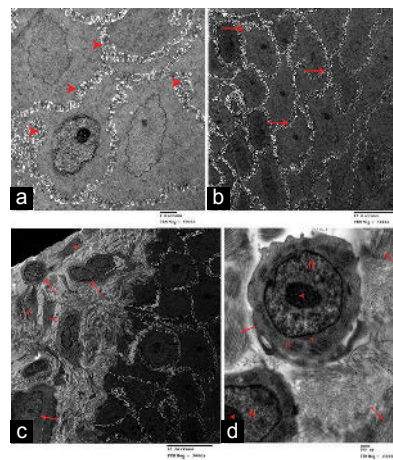
less marked RER. Less collagen bundles were observed surrounding the fibroblast (Fig. 8d).

Discussion

The effect of mitomycin C as a topical antifibrotic agent has been studied extensively in the last few years, especially in the field of ophthalmic surgery [9]. The use of a diluted solution of mitomycin C was the most common applied procedure. The commercially available mitomycin C has a concentration of 10 mg, used as an alkylating antineoplastic drug that prevents proliferation of cells by DNA disruption, types of vulnerable cells including the bone marrow and fibroblast [5]. In the laryngotracheal fibrosis, the use of inhalational mitomycin C is of interest, its benefits being that it is the least invasive, repeated applications are possible, a short duration of therapy is sufficient, and the need for general anesthesia is minimized during laryngobronchoscopic procedures [4]. In a study of inhalational mitomycin C in a canine model, it was used as adjunctive therapy to improve the results of surgical intervention after initial induced injury [7]. In the current study, we used mitomycin C as a single modality for the treatment of laryngeal fibrosis without a previous surgical intervention. The evaluation includes both light and electron microscopic examination aiming to identify the morphologic and ultrastructural effects of mitomycin C. It was found that there was marked fibrosis and synechia in the larynx of dogs, especially in the posterior interarytenoid area. This was documented clinically by endoscopic assessment, results that were in agreement with those reported by Spector *et al.* [3].

In the H&E stain, it was found that the epithelium thickness was significantly increased in the untreated

Figure. 7

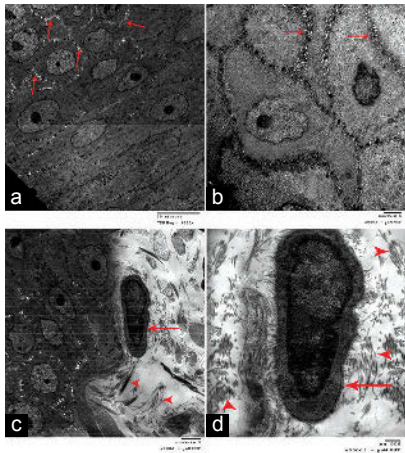


Electromicrograph of the untreated group showed (a) vocal cord with hyperplastic epithelium and enlargement of intercellular junctions (arrows) ($\times 3000$). (b) Higher magnification of the previous section showed fluid-filled gaps between cells (arrowheads) altering the desmosome structure ($\times 6000$). (c) Marked fibrosis (arrowheads) associated with marked fibroblast proliferation (arrows) ($\times 3000$). (d) Active fibroblast had a large rounded appearance with an open face nucleus (N), a visible nucleolus (arrowheads), distended with well-developed rough endoplasmic reticulum (R), and heavily surrounded by extensive dense collagenous bundles in the superficial layer of the lamina propria (arrows) ($\times 15\ 000$).

group in comparison with the model group, whereas the treated group showed a mild increase in the epithelium thickness; similar findings were reported by Spector *et al.* [10]. In Masson's trichrome stain, the color density of collagen areas of the untreated group was significantly increased compared with the control group; however, the treated group showed a marked decrease in the collagen areas compared with the untreated group. Both the results above show that there changes occurred in the epithelium thickness and collagen fiber formation after the exposure to inhalational mitomycin C. These results are in agreement with the results of Fattah *et al.* [4], who used inhalational mitomycin C as adjuvant therapy to surgical intervention. Also, these results are in agreement with the results of Cortés de Miguel *et al.* [5], who applied a local mitomycin C solution to humans with laryngotracheal stenosis as adjuvant therapy to surgery.

Electron microscopy results confirmed the light microscope changes detected in this study as the untreated group showed marked disturbance of the cell junctional areas with deposition of amorphous materials and changes in desmosome shape. There was also extensive fibrosis with deposition of collagen. The fibroblast became actively hypertrophied, with well-developed endoplasmic reticulum with a dense collagenous bundle surrounding it. Most of these changes disappeared in the treated group, which showed mild changes compared with the control group in the

Figure 8



Electron micrograph of the treated group showed (a) vocal cord epithelium with mild enlargement of intercellular junctions (arrows) ($\times 3000$); (b) detailed structure of intercellular junctions showed no change in the desmosome structure (arrows) ($\times 6000$); (c) marked reduction in fibrosis (arrowheads) associated with fewer numbers of fibroblast (arrows) ($\times 6000$); (d) fibroblast had a spindle shape (arrows) with a dense nucleus and less marked rough endoplasmic reticulum (R). Fewer collagen bundles (arrowheads) were observed surrounding the fibroblast ($\times 15\ 000$).

form of mild hypertrophy of the intercellular junction and the fibroblast became less active, with a spindle shape with less prominent RER. These results were in agreement with the results of Garrett *et al.* [6], who found that there was a significant decrease in the fibrosis in the submucosa in the vocal folds of a treated canine model, with decreased number and activity of fibroblast.

Conclusion

Inhalational mitomycin C seems to have a potent antifibrotic effect on the larynx when applied 2 weeks

after the initial injury with short inhalational periods of time. It could exert its effect through decreasing the activity of the fibroblast evident by the decrease in the size of fibroblasts and density of the intrafibroblast endoplasmic reticulum.

Acknowledgements

Conflicts of interest

None declared.

References

- Smith ME, Elstad M. Mitomycin C and the endoscopic treatment of laryngotracheal stenosis: are two applications better than one? *Laryngoscope* 2009; 119:272–283.
- Roh JL, Yoon YH. Prevention of anterior glottic stenosis after bilateral vocal fold stripping with mitomycin C. *Arch Otolaryngol Head Neck Surg* 2005; 131:690–695.
- Spector JE, Huang S, Werkhaven JA, Sanders D, Spector NC, Reinisch L. Prevention of anterior glottic restenosis in a canine model with topical mitomycin-C. *Ann Otol Rhinol Laryngol* 2001; 110:1007–1010.
- Fattah HA, Hamza A, Gaafar A, Hamza M, Mourad Z. Inhalation mitomycin-C in the management of laryngeal fibrosis: rationale, benefits and pitfalls. *Int Congress Ser* 2003; 1240:831–837.
- Cortés de Miguel S, Cabeza Barrera J, Gallardo Medina M, Cassini Gmez De Cdz LF, Salmern-Garca A, Rodriguez Lucas F. Topical endotracheal mitomycin C as a complementary treatment for endoscopic treatment of recurrent laryngotracheal stenosis. *Farm Hosp* 2011; 35:32–35.
- Garrett CG, Soto J, Riddick J, Billante CR, Reinisch L. Effect of mitomycin-C on vocal fold healing in a canine model. *Ann Otol Rhinol Laryngol* 2001; 110:25–30.
- Fang R, Sun J, Wan G, Sun D. Comparison between mitomycin C and chitosan for prevention of anterior glottic steno after CO₂ laser cordectomy in dogs. *Laryngoscope* 2007; 117:2057–2062.
- Eliashar R, Davros W, Eliachar I, Gramlich T, Esclamado R, Moffett K, Strome M. Evaluating laryngotracheal stenosis in a canine model with virtual bronchoscopy. *Ann Otol Rhinol Laryngol* 2000; 109:906–912.
- Karmel M. Rethinking mitomycin C. Tips from glaucoma and refractive surgeons on ways to get the most out while minimizing complications. 2013. Available at: <http://www.aao.org/publications/eyenet/200503/feature.cfm>. [Last accessed date on 2013 Feb 4].
- Spector JE, Werkhaven JA, Spector NC, Huang S, Page RN, Baranowski B, *et al.* Preservation of function and histologic appearance in the injured glottis with topical mitomycin-C. *Laryngoscope* 1999; 109:1125–1129.