

Evaluation of the efficacy of recurrent laryngeal nerve identification utilizing the Zuckerkandl tubercle

Sherif K. Mohamed, Tamer S. Sobhy

Department of Otorhinolaryngology — Head & Neck Surgery, Ain Shams University, Cairo, Egypt

Correspondence to Sherif K. Mohamed, MD, PhD, Department of Otorhinolaryngology — Head & Neck Surgery, Ain Shams University, Abbasya Square, Cairo - 11471, Egypt
Tel: +20 111 237 8000;
e-mail: sheriflina@gmail.com

Received 30 April 2013

Accepted 25 August 2013

The Egyptian Journal of Otolaryngology
2014, 30(1):34-37

Introduction

Recurrent laryngeal nerve identification is an essential step in thyroid surgery for preserving the patients' voice and thus their quality of life. Methods of dissection and identification are adopted according to the surgeon's preference.

Objective

The aim of the study was to demonstrate the efficacy of recurrent laryngeal nerve identification using the Zuckerkandl tubercle as an anatomical landmark in comparison with the usual inferosuperior dissection of the tracheoesophageal groove.

Patients and methods

Four-hundred patients undergoing thyroidectomy were enrolled in a prospective comparative study. They were divided into two equal groups, each group being subjected to a specific technique.

Results and conclusion

There was a nonsignificant statistical difference between the two techniques, thus validating the efficacy of Zuckerkandl tubercle as an anatomical landmark for identification of the recurrent laryngeal nerve.

Level of evidence

Ib.

Keywords:

recurrent laryngeal nerve, thyroid, vocal fold

Egypt J Otolaryngol 30(1):34-37

© 2014 The Egyptian Oto - Rhino - Laryngological Society
1012-5574

Introduction

Historically, thyroid surgery has been fraught with complications. Injury to the recurrent laryngeal nerve (RLN), superior laryngeal nerve, or the parathyroid glands may result in profound lifelong consequences for the patients [1]. In-depth knowledge of the anatomical relations and variations in the thyroid and parathyroid glands, as well as of the vascular supply and laryngeal nerves, is the cornerstone of safe thyroid or parathyroid surgeries [1]. Visualization of the RLN is absolutely essential for good surgical outcomes because many authors report decreased incidence of vocal cord paresis with visualization [2].

Visual identification of the RLN during thyroid surgery has been shown to be associated with lower rates of RLN palsy but does not guarantee success against an outcome of postoperative vocal cord paralysis [3]. RLN palsy is still being reported with a permanent palsy rate of 1–2% and a temporary palsy rate of up to 5–6%. Furthermore, most RLN palsy injuries are not recognized intraoperatively. RLN injury can result from transection, clamping, stretching, electrothermal injury, ligature entrapment, or ischemia [3]. Paresis of the RLN is a serious complication that may prevent the affected individual from continuing his or her profession. There are two major problems in RLN

palsy: inability to visualize the cord movement directly during operation; and the anatomical integrity of the RLN, which does not indicate intact function [4].

Theoretically, the surgical anatomy of the RLN has been clarified but the nerve anatomical variations could lead to difficulty during surgery [5]. Different surgical landmarks have been proposed for locating the RLN, but none of them are universally accepted. These include Simone's triangle, its relation with the inferior thyroid artery, and its relation with the inferior pole of the thyroid gland. Alternatively, traction maneuvers or intraoperative electrophysiological monitoring have also been proposed as a means of avoiding RLN injury [6].

The Zuckerkandl tubercle (ZT) is an anatomic landmark that can be used for the identification of the RLN intraoperatively. It is located between the superior and inferior poles, pointing toward the tracheoesophageal groove [7].

The ZT is a lateral or posterior projection from the lateral thyroid lobe, which indicates the point of embryologic fusion of the ultimobranchial body and principal median thyroid process [8]. Sheahan and Murphy [9] reported that ZT is a critical anatomical landmark in thyroid surgery, being present in most of the thyroid lobes, especially in the larger ones. They

believed that adequate recognition and dissection of the ZT is essential for successful thyroid surgery [9].

Aim of work

The aim of the study was to demonstrate the efficacy of RLN identification using the ZT as an anatomical landmark in comparison with the usual inferosuperior dissection of the tracheoesophageal groove.

Patients and methods

Four hundred patients undergoing thyroid surgery during the period from April 2003 to June 2011 were included in our prospective comparative cohort study. Written informed consent was obtained from all patients. Approval of the ethical committee was taken with no conflict of interest or financial or professional issues.

Assessment of vocal cord mobility was carried out not earlier than 2 weeks preoperatively. Patients with paralyzed vocal folds or recurrent thyroid lesions were excluded from the study.

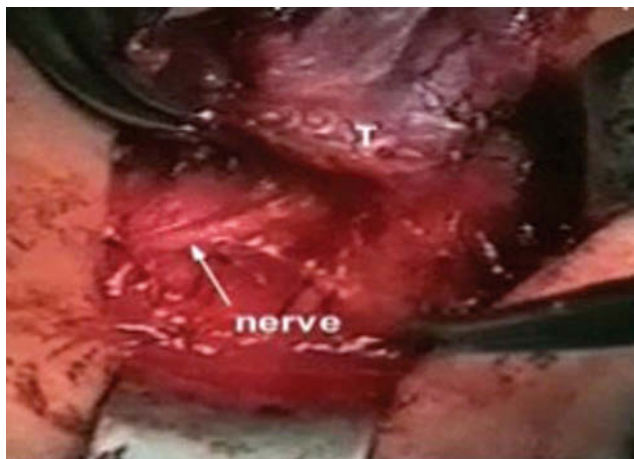
Patients were preoperatively randomized into two independent groups according to the technique of RLN identification that would be used. Surgery was performed by two surgeons with each surgeon performing one technique.

Group A included 200 patients. Complete visualization of the RLN was achieved by inferosuperior dissection of the tracheoesophageal groove.

Group B included 200 patients. Identification of the RLN was achieved using the ZT while it was pointing toward the RLN. During surgery, the ZT was specifically inspected on the lateral portion of the thyroid lobe. The ZT is located between the superior and inferior poles of the thyroid gland pointing to the tracheoesophageal groove. The nerve lies in front when the ZT is very small or when there is only thickening of the lateral edge of the thyroid lobes; more frequently the nerve runs in a tunnel deep behind the tubercle, as shown in Figure 1. Patients who were discovered to have no ZT intraoperatively were excluded and were replaced by others who had ZT.

Because the relation between the ZT and the RLN is fairly constant, medial retraction of the ZT is achieved by blunt dissection or by dividing a few small vessels, enabling the surgeon to follow the nerve from its nearest position to the larynx where it is more vulnerable if unexposed.

Figure 1



Showing the Zuckerkandl tubercle at the posterolateral portion of the thyroid lobe pointing to the recurrent laryngeal nerve.

The tunnel, within which the RLN runs, must be opened at the top, dissecting the superior parathyroid gland from the end of the tubercle.

The status of the RLN was evaluated through fiberoptic laryngeal examination of the vocal fold mobility immediately postoperatively and the next morning to document the status of the RLN.

For the affected (paralyzed) RLN, follow-up was performed every week initially for the first month and then every 4 weeks until recovery. Permanent dysfunction is considered when paralysis persists for more than 12 months postoperatively.

Results

The data collected were revised, coded, tabulated, and analyzed using the statistical package for social science (SPSS 15.1; SPSS Inc., Chicago, Illinois, USA) for Windows. The Student *t* test, the χ^2 -test, and the Fisher exact test were used for comparison between groups.

Our study population that included 400 patients comprised 362 (90.5%) women and only 38 (9.5%) men, who were divided equally in both groups.

A total of 166 patients (41.5%) had benign nontoxic pathology (76 in group A and 90 in group B). Malignant thyroid disease was found in 148 patients (37%) (76 in group A and 72 in group B). Toxic thyroid disease was found in 86 patients (21.5%) (48 in group A and 38 in group B).

The total number of patients who underwent total thyroidectomy was 282 (70.5%) (146 in group A and

136 in group B) and 118 (29.5%) underwent partial thyroidectomy (54 patients in group A and 64 in group B).

In the immediate postoperative period there were 18 RLN affections after surgery: eight sides in group A (4.0%) and 10 sides in group B (5%). There was no significant statistical difference between the two groups.

During the follow-up period, five sides showed recovery out of eight in group A and seven sides showed recovery out of 10 in group B, with no significant statistical difference between the two groups as shown in Table 1.

Discussion

For decades, there was controversy over whether identification of the laryngeal nerve can lower the rate of RLN palsy or whether such attempts in fact have a deleterious effect on preservation of the nerve's function. In experienced hands, however, it has repeatedly been shown that identification of the nerve is not accompanied by an increased rate of nerve palsy [10]. Recently, analysis of the data concerning more than 7500 patients in a large, prospective multicenter study has shown that identification of the RLN reduces the risk of RLN palsy by 1–6-fold [11].

Sheahan and Murphy [9] reported that ZT is a critical anatomical landmark in thyroid surgery and is present in most thyroid lobes. They also believed that recognition and dissection of the ZT is essential for successful thyroidectomy. However, there is little mention of the ZT in surgical textbooks or papers. This shortage of information is particularly notable when considering the amount of literature on thyroidectomy [9].

Asgharpour *et al.* [6] denied the use of ZT as a surgical landmark for the identification of the RLN as they stated that the most constant relationships are those with Berry's ligament, inferior constrictor muscle, and

the distance to the thyroid cartilage inferior horn, or the inferior rim of the cricothyroid joint.

Altorjay *et al.* [5] stated that palpation following surgical manipulation of the upper lobe and picking up the substance for the identification of the RLN proved helpful only in 81.4% of patients. In contrast, in our study use of the ZT as an anatomical landmark for RLN identification led to a positive result in 96% of cases. One should be aware that palpation can lead to false-positive results, meaning that many structures that may in fact be something else can be falsely diagnosed as RLN.

Another point of interest is that Altorjay *et al.* [5] found that the number of false-positive palpation findings on the left side was four times more than that on the right side and, conversely, the number of nonpalpable nerves on the left side was about one-fourth that on the right side. In our study, we did not find any difference in the identification of the RLN using the ZT as a pointer

We do believe that a correct technique of thyroidectomy requires routine direct visualization and identification of the RLN, especially in huge thyroids and in those with retrosternal extension for which safe tracheoesophageal groove dissection for RLN identification is rather difficult. Only careful dissection of the RLN allows its subsequent protection, with less nerve damage. Finally, we have been considering the ZT as a useful anatomical landmark for tracing the RLN during thyroid surgery. We consider this to be an improvement in thyroidectomy because of the almost constant relationship of the tubercle to the nerve at the level where there is a great risk of injury, although it does not guarantee the postoperative outcome of vocal fold palsy.

The usual method of tracing the RLN by dissecting along the entire cervical RLN may result in palsy because of excessive exposure of the nerve. However, the technique of RLN identification using the ZT, thus avoiding the dissection of the actual nerve, might even reduce the incidence of temporary palsy of the RLN, especially in cases of huge goiters.

Table 1 Comparison between the two study groups as regard operative and postoperative data

	N (%)		P value	Significance
	Group A	Group B		
Operation				
Left hemi	26 (13.0)	24 (12.0)	0.528	NS
Right hemi	28 (14.0)	40 (20.0)		
Total	146 (73.0)	136 (68.0)		
Cord affection				
One side	8 (4.0)	10 (5.0)	0.583	NS
No affection	192 (96.0)	190 (95.0)		
Recovery				
Yes	5 (62.5)	7 (70.0)	1.00	NS
No	3 (37.5)	3 (30.0)		

Conclusion

RLN identification is crucial during thyroid surgery. However, the use of intraoperative nerve monitoring is a luxury that cannot be afforded by many centers and hence there is a need for easy nerve identification in a way that the surgeon finds most convenient. Use of the ZT as an anatomical landmark for RLN identification is a convenient nontraditional method; in fact, it is suitable

for dissecting out huge thyroids with retrosternal extension because it allows the surgeon to locate the nerve at the most common site of injury (as it enters the larynx) without injurious dissection of the rather hazardous tracheoesophageal groove in such cases.

Acknowledgements

Conflicts of interest

None declared.

References

- 1 Mohebati A, AR Shaha. Anatomy of thyroid and parathyroid glands and neurovascular relations. *Clin Anat* 2012; 25:19–31.
- 2 Richer SL, GW Randolph. Management of the recurrent laryngeal nerve in thyroid surgery. *Oper Tech Otolaryngol Head Neck Surg* 2009; 20:29–34.
- 3 Chiang FY, Lu IC, Chen HC, Chen HY, Tsai CJ, Hsiao PJ, *et al.* Anatomical variations of recurrent laryngeal nerve during thyroid surgery: how to identify and handle the variations with intraoperative neuromonitoring. *Kaohsiung J Med Sci* 2010; 26:575–583.
- 4 Dralle H, *et al.* Risk factors of paralysis and functional outcome after recurrent laryngeal nerve monitoring in thyroid surgery. *Surgery* 2004; 136:1310–1322.
- 5 Altorjay Á, *et al.* Place and value of the recurrent laryngeal nerve (RLN) palpatory method in preventing RLN palsy during thyroid surgery. *Head Neck* 2009; 31:538–547.
- 6 Asgharpour E, Marañillo E, Sañudo J, Pascual-Font A, Rodriguez-Niedenführ M, Valderrama FJ, *et al.* *Head Neck* 2012; 34(9):1240–1246
- 7 Gravante G, *et al.* The Zuckerkandl tubercle. *Am J Surg* 2007; 193:484–485.
- 8 Yalçın B, Ozan H. Relationship between the Zuckerkandl's tubercle and entrance point of the inferior laryngeal nerve. *Clin Anat.* 2007; 20(6):640–643. Erratum in: *Clin Anat.* 2008; 21(2):222
- 9 Sheahan P, Murphy MS. Thyroid tubercle of Zuckerkandl: importance in thyroid surgery. *Laryngoscope* 2011; 121:2335–2337.
- 10 Gimm O, *et al.* An update on thyroid surgery. *Eur J Nucl Med Mol Imaging* 2002; 29:S447–S452.
- 11 Thomusch O, Machens MA, Sekulla C, Ukkat J, Lippert H, Dralle H, Gastinger I. Multivariate analysis of risk factors for postoperative complications in benign goiter surgery: prospective multicenter study in Germany. *World J Surg.* 2000; 24:1335–1341.