Singh *et al.*
The Egyptian Journal of Otolaryngology (2024) 40:41
https://doi.org/10.1186/s43163-024-00597-2

The Egyptian Journal of Otolaryngology

CASE REPORT

Open Access

Thyroid abscess presenting as a discharging sinus: a case report

Vibha Singh[1], Annanya Soni[1], Arijit Jotdar[1] and Amit Kumar Gupta[2*]

Abstract

Background It is unusual to get an isolated thyroid abscess. Thyroid abscess or acute suppurative thyroiditis accounts for 0.7–1% of all instances of thyroid diseases. The thyroid gland typically has a high level of iodine, a well-enveloped capsule, and resistance to infections. The diagnosis and treatment of this unusual entity are covered in this paper.

Case presentation.

An adult male patient presented with anterior neck swelling for 15 days and pus discharge for 2 days. The neck ultrasound revealed characteristics that could indicate a thyroid abscess. The thyroid function test and other laboratory data were within normal bounds. A neck contrast-enhanced computed tomography scan was performed, and it only revealed a single thyroid abscess and no other abnormalities. After starting the patient on intravenous antibiotics, the abscess was incised and drained. The patient's symptoms got better.

Conclusion In the era of advanced antibiotics incidence of thyroid abscess is extremely rare. Early diagnosis and intervention may improve the outcome of this condition. Knowledge of disease and its potential complications can prevent morbidity.

Keywords Thyroid abscess, Acute suppurative thyroiditis, Sinus

Background

Due to its capsule, healthy circulatory and lymphatic circulation, and iodine content, the thyroid gland is the least likely gland to become infected. Acute suppurative thyroiditis is a life-threatening endocrine emergency that presents as fever, neck pain, and swelling. Even among those with impaired immune systems, acute suppurative thyroiditis (AST) is a rare disease with the incidence being less than 1% of all thyroid diseases [1]. It is most commonly caused by gram-positive organisms like Staphylococcus aureus, haemolytic Streptococcus, or Streptococcus pneumonia, but occasionally it is caused by Haemophilus and Fusobacterium. Infection caused by E. coli in the thyroid has never been reported in the literature. Infection is usually a result of trauma, hematologic seeding from a distant infected site, or direct infection from a deep cervical region. The infection starts in one thyroid lobe, which if left untreated turns into an abscess cavity that breaks through the capsule and extends into the mediastinum or deep neck spaces via fascial planes. On workup usually the patient is euthyroid with normal Erythrocyte sedimentation rate and raised leukocyte count. Diagnosis is usually clinical and management is incision and drainage followed by culture-directed antibiotics.

*Correspondence:
Amit Kumar Gupta
amitonline44@gmail.com
[1] Department of ENT, All India Institute of Medical Sciences, Uttar Pradesh, Raebareli PIN-229405, India
[2] Department of Surgery, All India Institute of Medical Sciences, Uttar Pradesh, Room No 628, Hospital Block, Raebareli PIN-229405, India

Case presentation

A 65-year-old male with no co-morbidities presented to the outpatient department with complaints of anterior neck swelling for 15 days and pus discharge from

the swelling for 2 days. There was no history of any injectable drug intake. On examination, the patient was afebrile and normotensive with no sign of respiratory distress. Systemic examination was normal. There was no evidence of an immunocompromised state. On head and neck examination a 6 × 5 cm midline neck swelling was present just above the suprasternal notch with multiple pus points. The swelling was tender with a raised temperature.

Thyroid profile was normal with serum thyroid stimulating hormone (TSH) of 1.46 IU/ml. Viral markers were negative. Fine needle aspiration (FNA) cytology was suggestive of an infected colloid cyst, ruling out the possibility of anaplastic carcinoma. Pus aspirated was sent for culture. Figure 1 shows the contrast-enhanced computed tomography (CECT) neck, which was suggestive of a well-defined lobulated complex hypodense lesion of size 63 × 60 mm with internal hyperdensities suggestive of debris, cystic areas, and no calcification. The trachea was deviated to the right and retrosternal extension was noted. Routine investigations were sent. Figure 2 shows the chest X-ray with a homogenous soft-tissue density anterior to the trachea, displacing it to the right. The hemoglobin level on admission was 9.5 g/dl with a total leucocyte count (TLC) of 20,500/μL.

Since there was no evident immunocompromised status or other source of infection, such as a urinary tract infection, the underlying etiology of the infection remained unknown. Neither direct laryngoscopy nor a review of neck imaging revealed the presence of a pyriform sinus fistula.

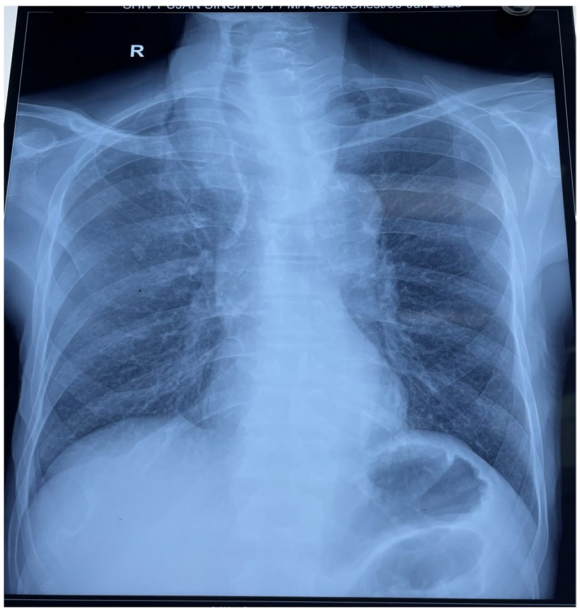

Fig. 2 Chest X-ray showing the inferior extent of pus and tracheal shifting

The patient underwent incision and drainage under local anesthesia and 75 ml of yellowish-green pus was suctioned out (Fig. 3).

The patient was treated empirically with intravenous piperacillin and tazobactam at a dose of 4.5 g thrice a day and metronidazole at a dose of 500 mg three times a day. Cultures of the drained pus yielded Escherichia coli. After a week's course of intravenous antibiotics and daily dressing, the patient improved symptomatically and was discharged home 7 days after admission. The TLC on discharge came down to 6310/μL, with a chest X-ray

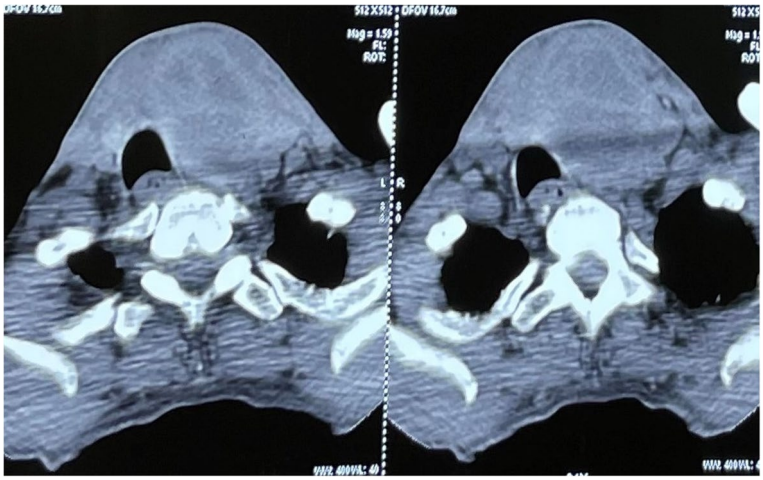

Fig. 1 Large collection within the thyroid gland, shifting the trachea

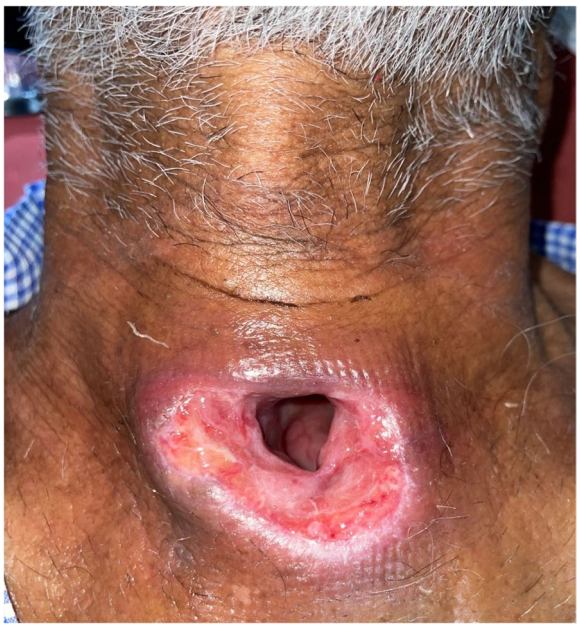

Fig. 3 Thyroid abscess after drainage

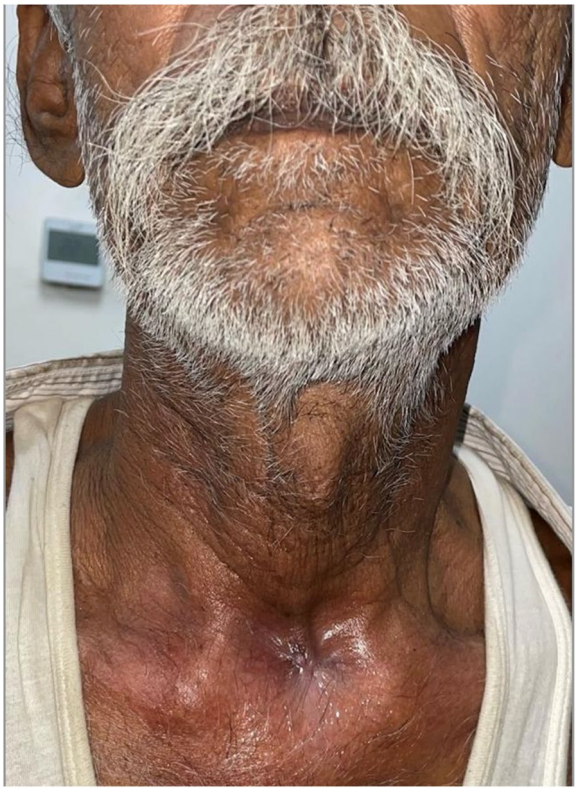

Fig. 4 No residual swelling on 1 month follow-up

showing the return of the trachea to its normal position. On 1 month follow-up, the patient's wound healed completely with no residual swelling (Fig. 4).

Discussion

Acute suppurative thyroiditis is an uncommon form of thyroiditis and its progression to thyroid abscess is rare. Thyroid disease, anatomical anomalies, or immunocompromised conditions may predispose patients to developing thyroid abscesses [2, 3]. The most common cause of thyroiditis in children is a pyriform fistula, while in adults it is immunocompromised status. Idiopathic thyroid abscess is a rare occurrence with few reports [4]. In our case the cause of the abscess is unknown.

The most common causative organism for thyroid abscess is Staphylococcus aureus and Streptococci. Other organisms, though less commonly identified are Aspergillus, Brucella, Klebsiella, Eikenella, Salmonella, and Acinetobacter but often the infection is polymicrobial. Rarely can methicillin-resistant staphylococcus aureus and E. coli-related thyroid abscesses develop [5–7]. Thyroid gland infections caused by Tuberculosis, Salmonella, and Eikonella have also been documented [8, 9]. Upon reviewing the literature, a few cases of acute suppurative thyroiditis caused by E. coli in immunocompromised patients were identified [10, 11].

A thyroid abscess following fine needle aspiration of the thyroid nodule has been reported [4]. The hematogenous spread of infection from urinary tract infection has also been reported [12]. In this case, no source of infection was found.

Acute suppurative thyroiditis is a rare entity, which progresses rapidly and can be fatal if not identified and treated promptly. For an immunocompromised patient or a child presenting with an acute onset anterior neck swelling with fever with an underlying thyroid disease the possibility of acute suppurative thyroiditis should be considered. Ultrasound is the preferred imaging technique for the diagnosis of thyroid diseases as well as it aids in needle aspiration. The use of computed tomography and magnetic resonance imaging in diagnosis has a limited role. If an iodine scan is done, abscess areas may appear cold [13].

Treatment of thyroid abscess is incision and drainage followed by culture-directed antibodies. In the case of pyriform sinus fistulas, chemo cauterization can be done [14].

thyroid abscess secondary to branchial cleft anomalies may require lobectomy [4, 15]. Recurrent and non-responsive cases may require thyroidectomy, though there is an increased risk of parathyroid and recurrent laryngeal nerve injury.

Thyroid abscesses presenting with complications, including mediastinitis, stridor, internal jugular vein thrombosis, sepsis, and death have been reported [4, 16, 17].

Conclusion

The potential morbidity of thyroid abscesses emphasizes the necessity of timely detection and treatment. Although thyroid abscess is a rare diagnosis, it can have serious side effects. Therefore, in order to implement early aggressive care, practitioners must be informed of the diagnosis.

Acknowledgements
None

Authors′ contributions
VS and AS prepared the manuscript and were involved in patient management. AJ did the editing and was involved in patient management, and AKG was involved in patient management and preparing the final draft for submission. All authors read and approved the final manuscript.

Funding
None.

Availability of data and materials
This is a case report, and all the data pertaining to the case report have been included in this published article.

Declarations

Ethics approval and consent to participate
Approval from the Institute Ethics Committee was sought prior to reporting the case. IEC approval no- 2023–19-0th-exp-5-CR dated 19–9-23.The article was prepared in accordance with the Declaration of Helsinki. Written informed consent was obtained prior to the publication of the case report from the patient.

Consent for publication
Written informed consent for publication of the patient's clinical details and clinical images was obtained from the patient.

Competing interests
The authors declare that they have no competing interests.

Received: 10 August 2023 Accepted: 8 March 2024
Published online: 27 March 2024

References

1. Paes JE, Burman KD, Cohen J et al (2010) Acute bacterial suppurative thyroiditis: a clinical review and expert opinion. Thyroid 20:247–255
2. Yu EH, Ko WC, Chuang YC, Wu TJ (1998) Suppurative acinetobacter baumanii thyroiditis with bacteremic pneumonia: Case report and review. Clin Infect Dis 27(5):1286–1290
3. Wang WC, Shen HN (2021) Thyroid Abscess Associated With Pyriform Sinus Fistula. Mayo Clin Proc 96(11):2854–2855. https://doi.org/10.1016/j.mayocp.2021.08.023
4. Lesh R, Hellums R, Pichardo P, Wong J, Pellitteri P, Purdy N, Stavrides K, Haugen TW (2023) Thyroid Abscess: A Case Series and Literature Review. Ear Nose Throat J 1455613221150128. https://doi.org/10.1177/01455613221150128
5. Yedla N, Pirela D, Manzano A, Tuda C, Lo PS (2018) Thyroid abscess: challenges in diagnosis and management. J Investig Med High Impact Case Rep 25(6):2324709618778709. https://doi.org/10.1177/2324709618778709
6. Singh G, Jaiswal R, Gulati N, Campbell GE (2019) A case of idiopathic thyroid abscess caused by Escherichia coli. J Community Hosp Intern Med Perspect 9(2):159–161
7. Paes JE, Burman KD, Cohen J, Franklyn J, McHenry CR, Shoham S, Kloos RT (2010) Acute bacterial suppurative thyroiditis: a clinical review and expert opinion. Thyroid 20(3):247–255. https://doi.org/10.1089/thy.2008.0146
8. Andrés Ortiz-Flores and others (2017) Incidental finding of a primary thyroid tuberculosis. Oxford Medical Case Reports 2017(6):omx022. https://doi.org/10.1093/omcr/omx022
9. Khoo KS, Koh PS, Ng KL (2020) Salmonella thyroid abscess-two case reports. Gland Surg. 9(6):2198–2203. https://doi.org/10.21037/gs-20-474
10. Fassih M, Moujahid E, Abada R, Rouadi S, Mahtar M, Roubal M, Essadi M, El Kadiri MF (2012) Escherichia coli thyroid abscess: report of a case and literature review. Pan Afr Med J 11:42
11. Saksouk F, Salti IS (1977) Acute suppurative thyroiditis caused by Escherichia coli. Br Med J 2(6078):23–24. https://doi.org/10.1136/bmj.2.6078.23-a
12. Sen S, Ramakant P, Paul MJ, Jennifer A (2016) Acute suppurative thyroiditis secondary to urinary tract infection by E. coli: a rare clinical scenario. BMJ Case Rep 2016:bcr2015213231. https://doi.org/10.1136/bcr-2015-213231
13. Pearce EN, Farwell AP, Braverman LE (2003) Thyroiditis. N Engl J Med 348(26):2646–2655. https://doi.org/10.1056/NEJMra021194
14. Miyauchi A, Inoue H, Tomoda C, Amino N (2009) Evaluation of chemocauterization treatment for obliteration of pyriform sinus fistula as a route of infection causing acute suppurative thyroiditis. Thyroid 19(7):789–793. https://doi.org/10.1089/thy.2009.0015
15. Kruijff S, Sywak MS, Sidhu SB, Shun A, Novakovic D, Lee JC, Delbridge LW (2015) Thyroidal abscesses in third and fourth branchial anomalies: not only a paediatric diagnosis. ANZ J Surg. 85(7–8):578–81. https://doi.org/10.1111/ans.12576
16. Fonseca IF, Avvad CK, Sanchez EG, Henriques JL, Leão LM (2012) Acute suppurative thyroiditis with multiple complications. Arq Bras Endocrinol Metabol 56(6):388–392. https://doi.org/10.1590/s0004-27302012000600008
17. Jonas NE, Fagan JJ. Internal jugular vein thrombosis: a case study and review of the literature.Internet J Otorhinolaryngol. 2006;6(2).

Publisher′s Note