

ORIGINAL ARTICLE

Open Access



Acoustic and videoendoscopic effects of temporary vocal fold augmentation in an office-based setting: a quasi-experimental study

Yasmine Sabry^{1*}, Teemu Kinnari², Yehia Ashry¹, Maged Naguib¹ and Ahmed Geneid²

Abstract

Background: Vocal-fold augmentation is a continuously developing treatment modality for glottic insufficiency. Patients with glottic insufficiency attend the phoniatrics clinics with increasing frequency. Glottic insufficiency may be due to vocal-fold paralysis, paresis, atrophy, sulcus vocalis, scarring, and vocal-fold deficiency after laryngeal surgery. A variety of materials exist for injection augmentation. This follow-up study aimed to assess the short-term as well as long-term outcomes of vocal-fold injection with calcium hydroxyapatite (CaHA) in patients with glottic gap 1–3 mm.

Method: This study included 25 patients with glottic insufficiency who underwent injection augmentation with CaHA. All patients were scheduled for voice evaluation using a comprehensive subjective and objective battery of assessments. Assessments were performed before the procedure and after the procedure at 2 months and at 1 year.

Results: Perceptual voice quality assessed with the GRBAS scale improved and the results were stable after 1 year. Shimmer and HNR improved continuously through the follow-up sessions, while jitter and f₀ showed slight improvement after CaHA injection.

Conclusion: Voice improvement after injection of CaHA requires a minimum of 2 months to develop and may last for a long period.

Keywords: Glottal insufficiency, Presbylaryngis, Calcium hydroxyapatite, Acoustic analysis, Office-based

Background

Vocal fold augmentation (VFA) was first described by Breuning in 1911 and has since been an outstanding treatment for glottal insufficiency (GI) [1]. GI is one of the most common presentations in phoniatrics and ENT departments which causes dysphonia, impaired cough, vocal fatigue, and aspiration. One of the major causes of GI is presbylaryngis [2]. As the geriatric population increases, the number of patients suffering from

dysphonia due to vocal-fold atrophy will increase [1]. Another major cause for GI is unilateral vocal fold paralysis (UVFP), especially the iatrogenic form (ex. secondary to thyroid and spinal decompression or endarterectomy surgeries) [3, 4].

VFA has evolved with advancing technology. For example, HD chip-on-tip flexible laryngoscopes and awake in-office techniques have become increasingly used in addition to the standard suspension laryngoscopic technique [1]. Over the past decades, office-based VFA performed under local anesthesia has become more popular, as it provides direct feedback concerning voice quality and vocal-fold closure [5], avoids the risks of general anesthesia, and has cost

*Correspondence: Jasmensabry92@gmail.com

¹ Department of Otolaryngology and Phoniatrics-Head and Neck Surgery, Faculty of Medicine, Suez Canal University, Ismailia, Egypt
Full list of author information is available at the end of the article

and time benefits. Furthermore, an awake trial augmentation allows the patient to observe the degree of improvement and to decide upon further permanent augmentation, thyroplasty, or both [3].

Several injectable materials have been developed to eliminate the side effects of older materials such as Teflon, silicone, and paraffin, which can cause granuloma formation. The injectable material should be inert (to decrease fibrosis), resistant to migration or resorption, easy to use (requires only simple preparation), and should maintain the physical properties of the vocal folds [6]. The sustainability of the augmentation varies according to the injectable. The range of currently used materials is growing and includes hyaluronic acid (HA) (Restylane®), autologous fat or fascia, carboxymethylcellulose, micro-ri- zed acellular dermal matrix (Cymetra®), and calcium hydroxyapatite (CaHA, Radiesse®) [7].

The choice of injected material is determined according to the VFA indication. For example, temporary augmentation is employed in the case of acute unilateral vocal-fold paralysis or paresis, as spontaneous recovery could occur within 6 months post-onset. In this case, collagen, HA, or Radiesse Voice Gel would be the most effective treatment choice [8]. On the other hand, permanent VFA is employed for permanent causes of mild-to-moderate glottal insufficiency, such as vocal-fold atrophy, paralysis, and paresis. In this case, results obtained with CaHA, autologous fat or fascia injections are acceptable [9].

These materials vary in properties and advantages. Both fat and fascia are autologous graft materials that are tolerable in the vocal-fold tissue. However, the duration of autologous fat outcomes is controversial as this is a highly absorbable material. Autologous fascia has a slower absorption rate [10]. One disadvantage of autologous fat augmentation is that it requires direct laryngoscopic administration and hence requires general anesthesia [11]. Although fascia can be injected under local anesthesia by an experienced physician, this is usually reserved for patients with a general condition that does not allow general anesthesia [12].

CaHA is a biocompatible, Food and Drug Administration (FDA)-approved injectable that has a long-lasting effect [13]. CaHA can be injected in an office-based setting while the patient is awake [14].

Several researchers have reported positive short-term results (3–6 months) for CaHA injection. A study performed by Singh and Gupta assessed the short-term acoustic outcomes of VFA with CaHA and revealed significant improvement 3 months after injection [9].

Another study showed gradual improvement until 6 months in an Asian population [6]. However, few long-term studies have been performed to compare the efficacy of CaHA injection to other methods of

augmentation using subjective methods and videostroboscopy [15].

This study assessed the videoendoscopic findings and acoustic characteristics of voice outcomes with CaHA at 2 months and 1 year post-injection among patients with GI due to UVFP or vocal-fold atrophy.

Methods

Study population

This study included 25 patients (15 males and 10 females) who presented with dysphonia due to UVFP or VF atrophy and were treated with VFI using CaHA (RENÚ VOICE®) in the Department of Otorhinolaryngology-Head and Neck surgery of Helsinki University Hospital, Helsinki, Finland. The inclusion criteria were age ≥ 18 years with glottal gap 1–3 mm. The glottal insufficiency caused by unilateral vocal-fold paralysis or vocal-fold atrophy with UVFP of < 1 year duration. Exclusion criteria were hypersensitivity to local anesthetics, and paralysis > 1 year due to any cause. Approval from the research Ethics Committee was issued by Helsinki University Hospital.

Methodology

All patients underwent evaluation before surgical treatment, including laryngovideostroboscopy (LVS), perceptual voice assessment, and acoustic voice analysis. The laryngeal view in quiet respiration and in sustained phonation of the vowel /e/ was documented by videos. The stroboscopic findings were analyzed and subjectively assessed for the glottic closure, the shape of the glottal gap, the vocal folds movements, symmetry, regularity, the presence of mucus and its adhesion as well as the differences in the vocal folds' positions using the institute endoscopic assessing form. The glottic closure, the shape of the glottal gap and symmetry of vibrations are discussed in the in the results' section while other parameters without significant changes are mentioned separately in supplementary tables (Supplementary Tables 1, 2, and 3).

Patients' voices were assessed with the GRBAS scale of the Japanese Society of Logopedics and Phoniatics [16]. The audio of voices was anonymized and randomized prior to the evaluation and two experienced speech therapists assessed them blindly then, the score was averaged.

Objective acoustic voice analysis was performed with Praat version 6.0.19 [17]. Three samples of the sustained /ae/ sound at 60, 70, and 80 db and a mean of the three consistent trials was calculated for each of the parameters assessed. Also, a part of a story—to calculate speaking F0—was used for analysis. All the voice samples were recorded with a microphone at a fixed distance for all patients in a sound-isolating cabin. The average

fundamental frequency, jitter, shimmer, and HNR were calculated.

The same battery of investigations was performed at 2 and 12 months after injection.

Injections were performed with the patient in the sitting position under local anesthesia. The more patent nostril was anaesthetized with nafatsolin followed by a xylocaine spray in the mouth and throat and application of lidocaine 4% over the vocal folds and supraglottic structures. The patient was asked to hold their breath during administration of anesthesia and then phonate “ee” such that the anesthetic spread all over the glottis and supraglottic space. The larynx was completely numb within minutes.

Augmentation was performed in all patients transorally where the patient’s tongue was held out while a syringe with CaHA was introduced through the oral cavity. The needle was designed to be inserted through the pharynx to the larynx appropriately with the help of a flexible nasofibroscope. All injections were performed in deep musculature. The mean injected CaHA volume was 0.45 ± 0.2 ml (in each side in VF atrophy and in the paralyzed side in UVFP); however, each injection volume was specified according to the condition of the vocal folds and the immediate improvement observed during the procedure.

Immediately after injection, patients were observed for 15–30 min for signs or symptoms of respiratory distress, airway compromise, skin hematoma, or epistaxis. As laryngeal anesthetic may increase propensity for aspiration, patients were instructed not to eat or drink for 1–2 h after the procedure. Absolute voice rest for the first 48 h following vocal-fold injection was required to avoid superficial hemorrhage and premature material extrusion. A 1-week sick leave was also required if the patient had a voice-demanding job. No complications were observed after injection.

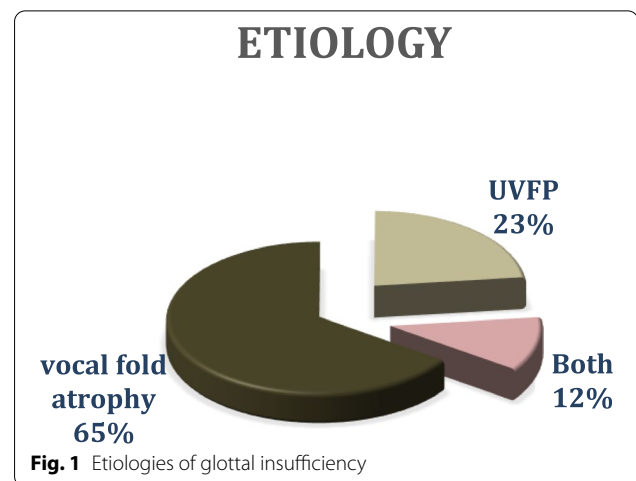
Statistical analysis

Data were analyzed using IBM SPSS software package version 25.0 (Armonk, NY: IBM Corp.). Qualitative data were described using numbers and percentages. The Kolmogorov-Smirnov test was used to verify the normality of distribution. Quantitative data were described using range (minimum and maximum), mean, standard deviation, and median.

Results

General characteristics

The study population consisted of 25 patients (mean age 65.3 ± 17.0 years). Of these, 17 had vocal-fold atrophy, 6 had UVFP, and 2 patients suffered from both (Fig. 1). The patients had no other illnesses; 4 patients were on



thyroxine medication. Pre-injection and 2-month post-injection assessments were performed on 25 patients. Sixteen patients had an additional assessment after 1 year.

Analysis of voice quality

GRBAS scale

Overall, VFA using CaHA in patients with glottal insufficiency improved perceptual voice quality as assessed by the GRBAS scale. The greatest change and best results were obtained for the breathiness “B” (which indirectly describes the degree of glottal closure), which were statistically significant after 2 months ($P = 0.03$) and after 1 year ($P = 0.04$). The grade “G” was also significantly improved after 2 months ($P = 0.001$) and after 1 year ($P = 0.03$) of follow-up. Roughness “R” ($P = 0.03$), astheny “A” ($P = 0.005$), and strain “S” ($P = 0.03$) were significantly changed after 2 months (Fig. 2).

Acoustic analysis

As seen in Table 1, acoustic analysis revealed a statistically significant decrease in shimmer from the pre-injection recording to the post-injection recording after 2 months and further at 1-year post-injection. The harmonic-to-noise ratio (HNR) also improved significantly throughout the observation period and reached maximum improvement at the 1-year follow-up. Fundamental frequency and jitter analysis showed minor improvement after 2 months. Six patients (4 with vocal-fold atrophy and 2 with UVFP) did not have acoustic improvement even though glottic closure improved as observed by laryngoscopy.

Video laryngoscopy

Only 14 patients attended the videoendoscopic follow-up 1 year after injection (Table 2).

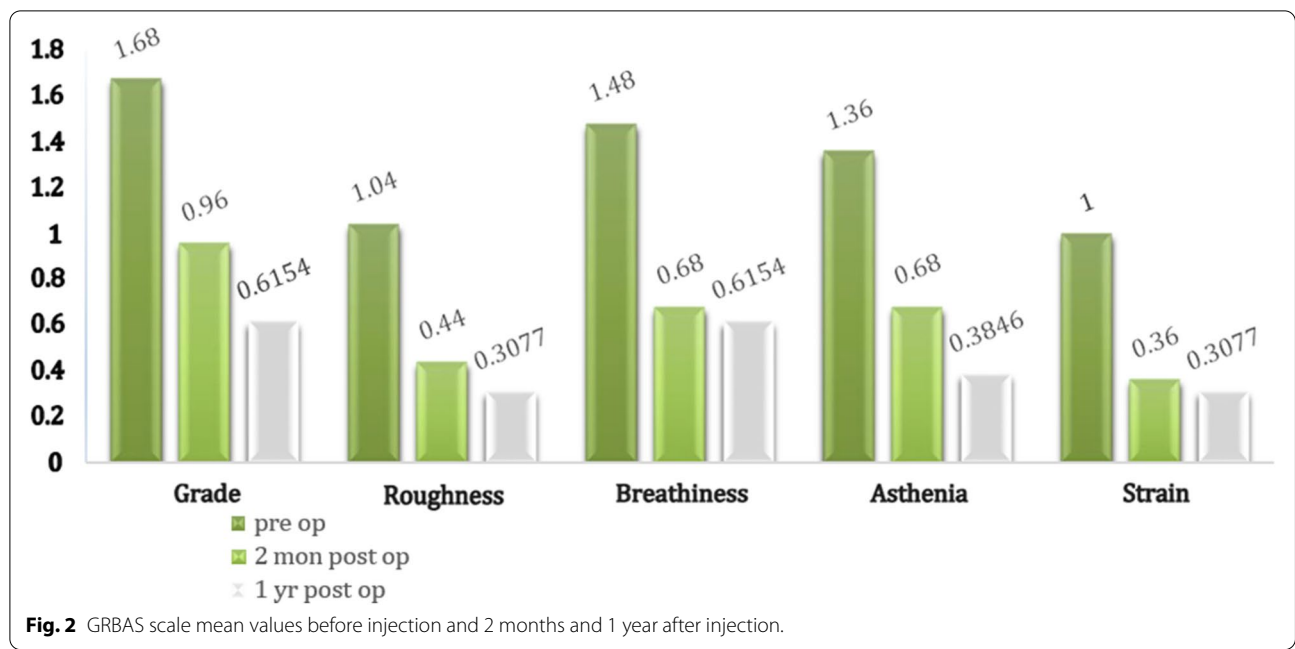


Table 1 Acoustic analysis

	Pre-injection	2 months post-injection	P value	1 year post-injection (16 patients)	P value
Fundamental frequency (F0)			0.32	Pre-injection Post-injection	0.049 ¹
Male	(15) 160.6 ± 65.76	(15) 150.4 ± 58.14		(9) 173.2 ± 83.21	(9) 165.0 ± 73.94
Female	(10) 234.2 ± 36.14	(10) 231.5 ± 39.17		(7) 248.1 ± 34.37	(7) 212.7 ± 19.76
Jitter	1.079 ± 0.89	0.949 ± 0.69	0.25	1.07 ± 0.93	0.64 ± 0.27
Shimmer	5.822 ± 3.015	4.909 ± 3.39	0.047	5.92 ± 3.41	3.936 ± 1.869
HNR	17.692 ± 5.22	19.576 ± 4.88	0.03	17.96 ± 5.812	21.94 ± 3.823

Table 1 shows a comparison between pre-injection and 2 months post-injection for 25 patients and another comparison between pre-injection and 1 year post-injection for the 16 patients who attended the 1 year follow-up assessment. Data are presented as mean values and standard deviation. HNR harmonic-to-noise ratio. Student's paired t test was used

¹ Wilcoxon signed-rank test

Table 2 Glottal closure: assessment of the glottal gap on the base of laryngovideostroboscopy

	Pre	2 months post-injection	1 year post-injection
Straight VF edges	3 (12%)	19 (76%)	8 (57.1%)
Open posterior gap	1 (4%)	0 (0%)	0 (0%)
Irregular glottis during phonation	1 (4%)	0 (0%)	0 (0%)
Curved VFs	9 (36%)	3 (12%)	3 (21.4%)
Glottal incompetence	11 (44%)	3 (12%)	3 (21.4%)
Total	25	25	14

Glottal closure

Before injection, all patients had glottic gaps that improved (completely or partially) immediately during the procedure. Curved-shaped VFs remained in 3 patients, and 3 patients with UVFP partially remained away from each other during adduction (Fig. 3).

Symmetry of vocal fold vibrations

In pre-injection endoscopy, 24% of the patients had asymmetrical VF vibration. During the 2-month follow-up,

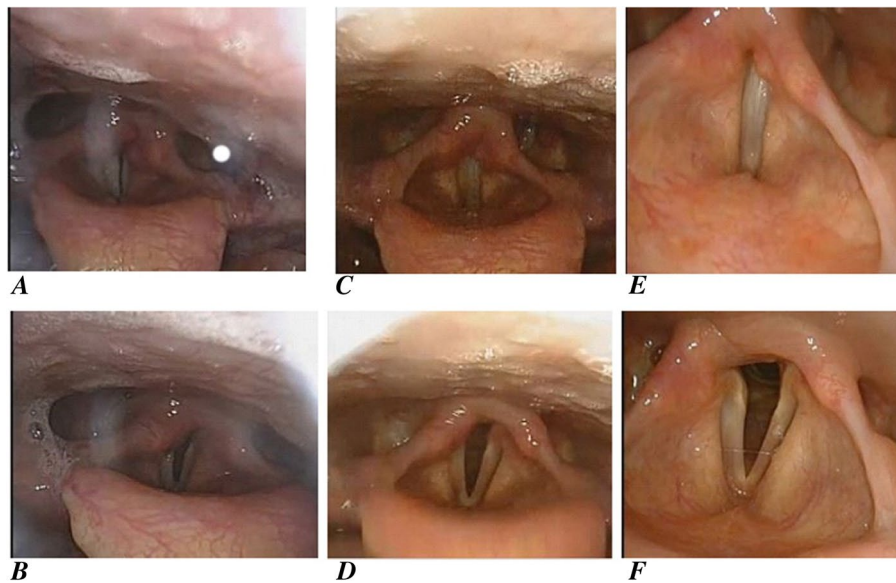


Fig. 3 Case rt vocal-fold paralysis pre- and post-injection. **A, B** The laryngoscopic examination pre-injection, **A** during adduction with evident glottal incompetence and **B** during abduction. **C, D** are from the 2-month follow-up; the glottis is completely closed with resolved glottal incompetence in **C** and during abduction in **D**. **E, F** From the 1-year follow-up visit, indicating that the injection is still effective

this percentage decreased to 8% (only 2 patients with UVFP had asymmetrical vibrations). The outcomes remained the same during the 1-year follow-up.

Discussion

Improving quality-of-life through having a clear recognizable voice has currently become a principal goal for vocal-fold injection. As time passes, both the injectable materials and the injection techniques are evolving [18].

The present study was designed to assess acoustic voice quality and videoendoscopic findings of temporary augmentation with CaHA injection among patients attending the Department of Otorhinolaryngology-Head and Neck Surgery at Helsinki University Hospital who fulfilled the inclusion criteria. Our study included 25 patients who were all treated by vocal-fold augmentation by CaHA via the peroral approach under local anesthesia. The results revealed substantial improvement in glottic closure and gradual improvements in acoustic parameters, especially shimmer and HNR (statistically significant), which continued to peak at 1 year after the procedure, and overall improved perceptual voice quality as assessed by GRBAS scale.

CaHA is one of the synthetic materials used here that is found as an essential component of bone and teeth [13]. Although there has been a case report of an inflammatory response in a patient after CaHA injection [19], clinical studies have shown that CaHA leads to minimal

inflammatory responses and has no signs of toxicity [20, 21].

No immunologic responses or CaHA migration were recorded in a study conducted by Chhetri et al. on histologic changes and mucosal wave vibrations in canine larynges at 12 months after injection [22]. In conjunction with these previous studies, our study revealed that none of our patients experienced acute adverse reactions such as dyspnea, bleeding, hematoma, or allergic reaction to CaHA.

Vocal-fold edge, glottal configuration, and vibratory amplitude are key factors observed during stroboscopy that affect voice quality [18, 19]. A limited number of studies have compared these parameters for CaHA injection. However, some studies revealed statistically significant improvements in these parameters post-injection. For example, a study done by Singh et al. showed complete glottic closure in 91.7% of patients 3 months post-injection [9]. Another one done by Woo et al showed the same results in 73.3% of patients after 3 months as well [18]. Also, a study made in by Hassan et al. showed that patients with unilateral VF immobility and VF atrophy showed improvement of glottal closure, mucosal wave, and amplitude after injection with CaHA without any change in mucosal wave and amplitude 3 months after injection [23].

Our results are consistent with these studies, as 19 patients (76%) and 9 patients (57.1%) had straight VFs after 2 months and after 1 year, respectively.

Differences in GRBAS parameter values before and after injection were statistically significant for each evaluated period, with best outcomes in breathiness. Our results are consistent with an earlier study, where the GRBAS scale of all patients exhibited significant changes in degree of severity (1.8 ± 0.6 pre-injection, 1.5 ± 0.8 1 month after injection, 1.0 ± 0.7 6 months after injection), roughness (0.8 ± 0.6 pre-injection, 0.4 ± 0.5 1 month and 6 months after injection), and breathiness (1.8 ± 0.8 pre-injection, 0.6 ± 0.6 1 month after injection, 0.9 ± 0.6 6 months after injection) [11].

In this study, the parameters for correlates of dysphonia severity (Fundamental Frequency (F0), jitter, shimmer, and HNR) were also tested. F0 is found to be elevated in patients with breathy voice when compared with their age- and sex-matched controls. The jitter increases mainly by the lack of control vocal folds' vibrations while the shimmer value change with the reduction of glottal resistance and mass lesions on the vocal fold. Our study showed statistically significant improvement in shimmer and HNR at the 2-month post-injection follow-up in 19 out of 25 (76%) cases of vocal-fold insufficiency. Although F0 and jitter improved, these were not statistically significant. These data are consistent with Singh et al., who observed improvement in all acoustics parameters in 11 out of 12 cases 3 months post-injection ($P = 0.001$) [9]. Another study revealed statistically significant changes in mean shimmer (10.3 pre-injection to 5.3 2 months after injection) in paralytic patients and in atrophic patients (8.3 to 3.8), and in NHR (0.9 to 0.2) while Jitter changed from 5.2 to 2.2 in patients with UVFP and from 4.8 to 2.2 in patients with VF atrophy [23].

Based on the previous results, CaHA injection effects could last for a long term which is published only in a few number of articles. The sustained effect of injection could be related to the sustained release from the carrier particles and the subsequent resorption of the material. This could be supported with the findings in a study conducted by Shiotani et al. in which minimal absorption of CAHA was observed on computed tomography scans up to 2 years after injection [24]. Another study conducted by Rosen et al. stated that the number of patients that require further treatment after 3 or 6 months of CaHA injection is less than that after 1 year and it was suggested that it could be due to the biologic activity of the injected particles [25].

We investigated possible reasons for why a small proportion of patients did not exhibit acoustic voice improvement after injection. In Helsinki University Hospital, among 400 vocal-fold insufficiency patients treated with VFA (either with CaHA or HA), there were 6 patients who did not improve with strainness increasing. These patients did not have acoustic improvement

even though glottic closure improved as observed by laryngoscope. This may be due to the development of compensatory mechanisms (such as a marked activation of plica ventricularis) in spontaneous speech, due to overactivation of the plica ventricularis. Subsequent treatment depended on waiting for the injected material to resolve and on voice therapy using a resonance tube [personal communications, Geneid A. 2020].

Limitations

The number of UVFP patients was relatively small. We could have benefited from another follow-up assessment at 6-month post-injection. Further, not all patients had their voice quality fully evaluated according to the European Laryngological Society (ELS) protocol in their three visits (pre-injection, 2 months, and 1 year post-injection). The ELS protocol includes perception, videostroboscopy, acoustic analysis, and aerodynamic and subjective rating of voice quality.

Conclusion

This study supports the safety and efficacy of office-based injection for patients with glottal insufficiency due to UVFP or atrophy. CaHA is a stable injectable material that can be effectively used for vocal-fold augmentation with a low complication rate. A minimum of 2 months is required for evident improvement in acoustic parameters of the patient's voice. With CaHA, the improvement may last for a year as assessed by outcomes especially in terms of acoustic correlates of voice. Further investigations on the timing and role of reinjection in patients with poor results are recommended to develop clinical guidelines for these patients.

Abbreviations

CaHA: Calcium hydroxyapatite; ELS: European Laryngological Society; FDA: Food and Drug Administration; GI: Glottal insufficiency; HNR: Harmonic-to-noise ratio; HA: Hyaluronic acid; UVFP: Unilateral vocal fold paralysis; VFA: Vocal fold augmentation; VFs: Vocal folds.

Supplementary Information

The online version contains supplementary material available at <https://doi.org/10.1186/s43163-022-00356-1>.

Additional file 1: Supplementary Table 1. Inflammatory signs. Supplementary Table 2. Mucous-linked. Supplementary Table 3. Vocal folds' movements

Acknowledgements

We thank Elina Tiaho, former phonetician in HUS, for assistance in gathering and translating information from Finnish to English and for her keen interest and generous preparation that made the study possible.

Authors' contributions

YS: Idea conception, design of the work, drafting the work, acquisition of data, data analysis and interpretation and writing the original draft and editing. TK:

Idea conception, design of the work, critically revising the work and supervising. YA: Idea conception, critically revising the work, final approval of the version to be published. MN: Idea conception, supervision and final approval of the version to be published. AG: Idea conception, design of the work, drafting the work, reviewing and supervision and final approval of the version to be published. All authors read and approved the final manuscript.

Funding

The authors received no financial support for the research, authorship, and/or publication of this article.

Availability of data and materials

All data generated or analyzed during this study are included in this article. Further enquiries can be directed to the corresponding author.

Declarations

Ethics approval and consent to participate

This study protocol and patients' consents were reviewed and approved by the Research Ethics Committee of Helsinki University Hospital, approval number: HUS/307/2019. Informed written consent to participate in the study was provided by all participants.

Consent for publication

Not applicable

Competing interests

The authors declare that they have no competing interests.

Author details

¹Department of Otolaryngology and Phoniatrics-Head and Neck Surgery, Faculty of Medicine, Suez Canal University, Ismailia, Egypt. ²Department of Otolaryngology and Phoniatrics-Head and Neck Surgery, University of Helsinki and Helsinki University Hospital, Helsinki, Finland.

Received: 30 May 2022 Accepted: 24 November 2022

Published online: 19 December 2022

References

- Kelly Z, Patel AK, Klein AM (2021) Evaluating safety of awake, bilateral injection laryngoplasty for bilateral vocal fold atrophy. *J Voice* 35(5):789–792
- Miaśkiewicz B, Szkielkowska A, Piłka A, Skarżyński H (2016) Assessment of acoustic characteristics of voice in patients after injection laryngoplasty with hyaluronan. *Otolaryngol Pol* 70(1):15–23
- Sielska-Badurek EM, Sobol M, Jędra K, Rzepakowska A, Osuch-Wójcickiewicz E, Niemczyk K (2017) Injection laryngoplasty as miniinvasive office-based surgery in patients with unilateral vocal fold paralysis - voice quality outcomes. *Wideochir Inne Tech Maloinwazyjne* 12(3):277–284
- Marques JAS, Marronnier A, Crampon F, Lagier A, Marie JP (2021) Early management of acute unilateral vocal fold paralysis: update of the literature. *J Voice* 35(6):924–926
- Sulica L, Rosen CA, Postma GN, Simpson B, Amin M, Courey M et al (2010) Current practice in injection augmentation of the vocal folds: indications, treatment principles, techniques, and complications. *Laryngoscope* 120(2):319–325
- Lee DY, Chung EJ, Kwon SK (2018) Efficacy of calcium hydroxyapatite in vocal fold augmentation for unilateral vocal fold paralysis in Asian. *Journal of the Korean Society of Laryngology, Phoniatrics and Logopedics* 29(2):83–86
- Chhetri DK, Jamal N (2014) Percutaneous injection laryngoplasty. *Laryngoscope* 124(3):742–745
- Lau DP, Lee GA, Wong SM, Lim VP, Chan YH, Tan NG et al (2010) Injection laryngoplasty with hyaluronic acid for unilateral vocal cord paralysis. Randomized controlled trial comparing two different particle sizes. *J Voice* 24(1):113–118
- Singh SK, Gupta SK (2019) Vocal fold insufficiency: how effective is injection laryngoplasty? Short Term Clinical Outcomes. *Indian J Otolaryngol Head Neck Surg* 71(Suppl 1):960–966
- Reijonen P, Leivo I, Nevalainen T, Rihkonen H (2001) Histology of injected autologous fascia in the paralyzed canine vocal fold. *Laryngoscope* 111(6):1068–1074
- Dursun G, Boynukalin S, Ozgursoy OB, Coruh I (2008) Long-term results of different treatment modalities for glottic insufficiency. *Am J Otolaryngol* 29(1):7–12
- Kinnari TJ, Pietarinen P, Geneid A (2018) Vocal fold augmentation under local anaesthesia using autologous fascia. *Clin Otolaryngol* 43(3):989–991
- Koçdor P, Tulunay-Uğur ÖE (2014) Injection laryngoplasty outcomes in vocal fold paralysis using calcium hydroxyapatite. *Kulak Burun Bogaz İhtis Derg* 24(5):271–275
- Lee M, Lee DY, Kwon TK (2019) Safety of office-based percutaneous injection laryngoplasty with calcium hydroxyapatite. *Laryngoscope* 129(10):2361–2365
- Zelenik K, Walderová R, Kučová H, Jančatová D, Komínek P (2017) Comparison of long-term voice outcomes after vocal fold augmentation using autologous fat injection by direct microlaryngoscopy versus office-based calcium hydroxyapatite injection. *Eur Arch Otorhinolaryngol* 274(8):3147–3151
- Hirano M (1981) GRBAS scale for evaluating the hoarse voice & frequency range of phonation. *Clinical examination of voice* 5:83–84
- Boersma PWD (2020) Praat: doing phonetics by computer [Computer program]. 6.0.19 ed
- Woo SH, Son YI, Lee SH, Park JJ, Kim JP (2013) Comparative analysis on the efficiency of the injection laryngoplasty technique using calcium hydroxyapatite (CaHA): the thyrohyoid approach versus the cricothyroid approach. *J Voice* 27(2):236–241
- Tanna N, Zalkind D, Glade RS, Bielamowicz SA (2006) Foreign body reaction to calcium hydroxyapatite vocal fold augmentation. *Arch Otolaryngol Head Neck Surg* 132(12):1379–1382
- Costantino PD, Friedman CD, Jones K, Chow LC, Sisson GA (1992) Experimental hydroxyapatite cement cranioplasty. *Plast Reconstr Surg* 90(2):174–185 discussion 86.
- Belafsky PC, Postma GN (2004) Vocal fold augmentation with calcium hydroxyapatite. *Otolaryngol Head Neck Surg* 131(4):351–354
- Chhetri DK, Jahan-Parwar B, Bhuta SM, Hart SD, Berke GS (2004) Injection laryngoplasty with calcium hydroxyapatite gel implant in an in vivo canine model. *Ann Otol Rhinol Laryngol* 113(4):259–264
- Hassan HE, Eldin ST, Al Kasaby RM (2014) Psycholinguistic abilities in cochlear implant and hearing impaired children. *Egyptian Journal of Ear, Nose, Throat and Allied Sciences* 15(1):29–35
- Shiotani A, Okubo K, Saito K et al (2009) Injection laryngoplasty with calcium phosphate cement. *Otolaryngol Head Neck Surg* 140(6):816–821
- Rosen CA, Gartner-Schmidt J, Casiano R, Anderson TD, Johnson F, Remacle M, Sataloff RT, Abitbol J, Shaw G, Archer S, Zraick RI (2009) Vocal fold augmentation with calcium hydroxyapatite: twelve-month report. *Laryngoscope* 119:1033–1041

Publisher's Note

Springer Nature remains neutral with regard to jurisdictional claims in published maps and institutional affiliations.