

CASE REPORT

Open Access



Cysticercosis of cheek as a rare presentation: case report and review of literature

Shailendra Gautam¹, Monica Patnaik², Hitendra Prakash Singh^{2*}  and Shalini Bhalla³

Abstract

Background: Cysticercosis is caused by parasitic infestation of larval stage of pork tapeworm (*Taenia solium*). It is a result of accidental ingestion of contaminated water and food from eggs of tape worm due to poor sanitation. Pigs serve as intermediate host. The most common sites of cysticercosis are the muscles, heart, and liver but sites such as the tongue, buccal mucosa, cheek, or floor of mouth are rare.

Case presentation: A 10-year-old male patient presented to outpatient clinic of ENT department with gradually progressive swelling of right cheek. Patient has been managed with surgical excision of the cyst.

Conclusion: Cysticercosis can be a differential diagnosis for painless swelling at cheek.

Keywords: Cysticercosis, *Taenia solium*, Cheek cysticercosis

Background

Cysticercosis is a parasitic infestation caused by the larval stage of cestode, Pork tapeworm (*Taenia solium*). *Taenia solium* has a very complex life cycle. It requires two hosts: a primary or definitive host and intermediate host. *Taenia solium*, which is a digenetic endoparasite, lives in small intestine of man and completes its sexual phase of life cycle. Thus, humans serve as only definitive host for adult tape worm [1]. Cysticercosis is very common in developing countries like China, Mexico, India, Africa and Indonesia due to their poor sanitation and close interaction between humans and pigs [2]. Cysticercosis occurs due to consumption of raw or poorly cooked pork because pigs serve as intermediate host. Common sites include brain parenchyma (neurocysticercosis), skeletal muscles, heart muscle, liver and lungs but it is very rare in tongue, buccal mucosa, cheek, lip, floor of mouth, and peritoneum [3–8].

They usually present as painless swelling and can be diagnosed by proper history, clinical examination,

imaging studies followed by surgical removal of the swelling and by histopathological examination.

Case presentation

A 10-year-old male child was presented with the complaint of swelling right side of the cheek since 8 months which was insidious in onset, gradually progressive in size. Swelling was not associated with any pain or fever. There was no history of trauma to cheek, toothache, weight loss, dysphagia, seizures, and loss of consciousness. Patient had mixed type of dietary habits. Patient was on Albendazole tablet 400 mg in three divided doses for 1 week.

On examination, there was a single, firm, nodular swelling measuring 3.0 × 2.0 cm present in right cheek. Swelling was smooth surfaced with well-defined margins and overlying skin was normal. It was nontender, not associated with any rise in local temperature and was freely mobile in all directions but became less mobile when underlying muscle is taut (Figs. 1 and 2). Mouth opening was adequate. On oral cavity examination, color of oral mucosa was normal, oral hygiene was good, and no inflammatory changes were noted around right Stensen's duct. There was no palpable lymphadenopathy.

*Correspondence: drhpsingh77@gmail.com

² Department of Otolaryngology & Head-Neck Surgery, King George's Medical University, Lucknow, Uttar Pradesh, India
Full list of author information is available at the end of the article

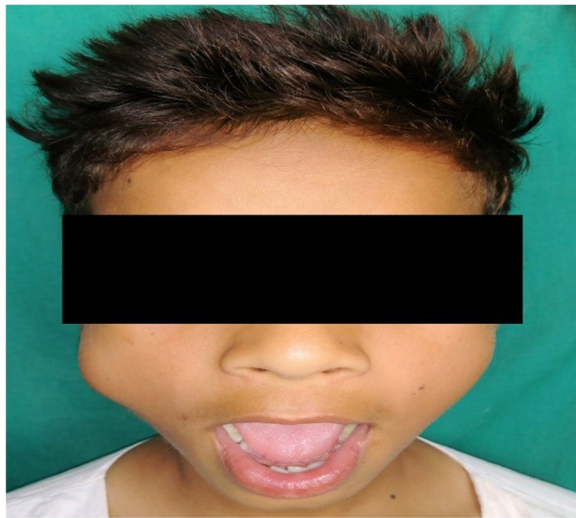

Fig. 1 Swelling on right side of cheek

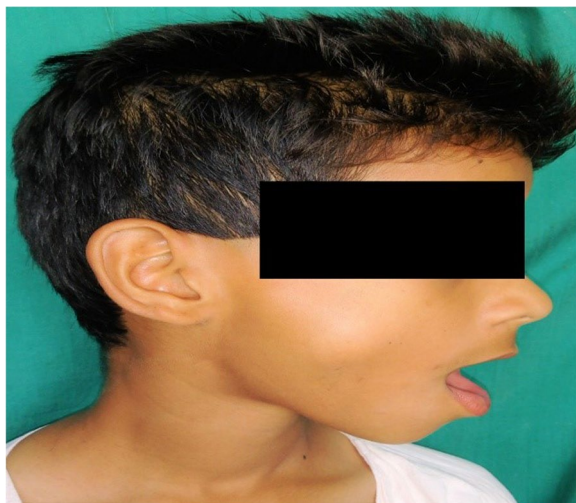

Fig. 2 Swelling as seen from lateral aspect

Routine blood investigations were done, which were unremarkable. On Magnetic Resonance Imaging of the face, there was a mildly thick-walled cystic lesion measuring about 1.2×1 cm in the inferior part of the right masseter muscle with mild perilesional oedema suspicious for a cysticercous cyst.

On fine needle aspiration cytopathology, stained smears showed parenchymatous fragments, cuticular, and hooklets of parasite. Background showed numerous eosinophils, neutrophils, histiocytes, proteinaceous material, and red blood cells suggestive of parasitic cystic lesion (cysticercosis).

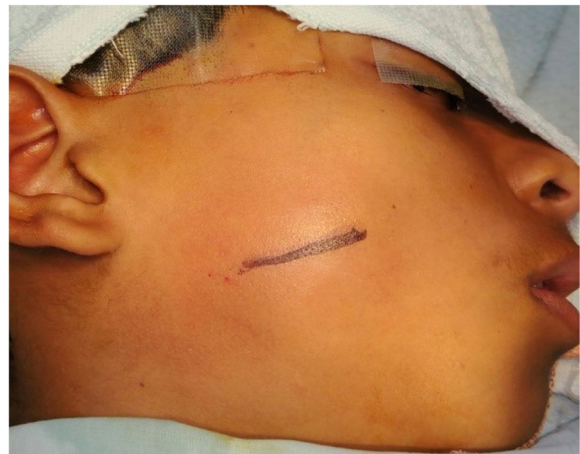

Fig. 3 Incision line over the swelling

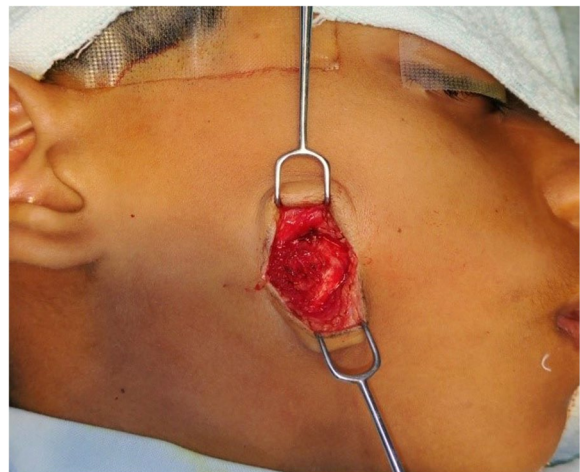


Fig. 4 Showing cyst adhered to Masseter

Surgical excision was planned through external route according to the location of the swelling. After obtaining proper informed consent from the parents, surgical excision was done under general anesthesia using horizontal incision (Fig. 3). A well-defined, capsulated, whitish swelling was visualized. It was found adherent with the masseter muscle (Fig. 4). The swelling was excised completely along with a small cuff of masseter muscle fibres and wound was closed in layers (Figs. 5, 6, and 7). The postoperative period remained uneventful (Fig. 8).

The gross specimen revealed as single grayish white soft tissue piece, measuring $1.0 \times 0.8 \times 0.5$ cm. Swelling was sectioned. Histopathological examination showed predominantly fibro-collagenous and fibro-muscular tissues infiltrated diffusely by plasma-lymphocytic

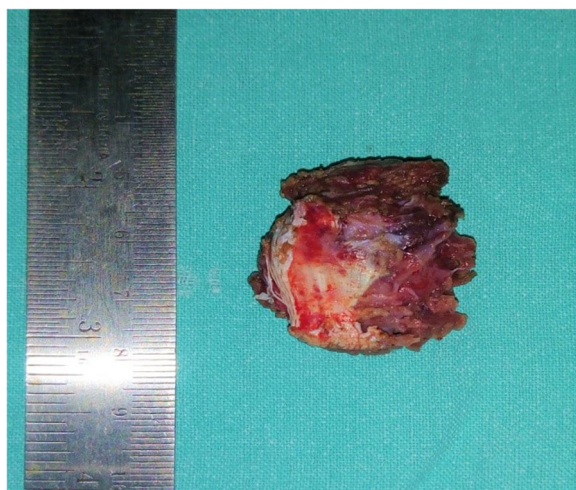


Fig. 5 Excised cyst

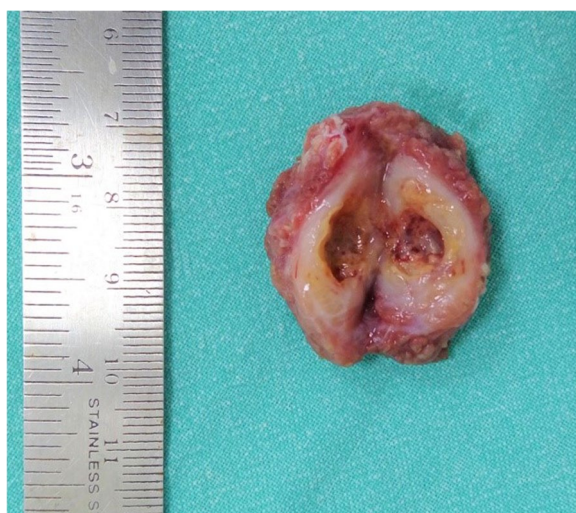

Fig. 6 Cut section of cyst with its cavity

infiltration forming aggregates at places with histiocytic giant cells. Focal area of necrosis surrounded by chronic inflammation with giant cells reaction. Histomorphology was suggestive of resolving cysticercosis (Fig. 9).

Discussion and conclusions

Cysticercosis is a parasitic infestation of larval stage of pork tapeworm (*Taenia solium*). Humans are primary or definitive host while pigs serve as secondary or intermediate host for *Taenia solium*. Humans are the only definitive host as sexual phase occurs in humans, while pigs are the intermediate host as it harbors larval form

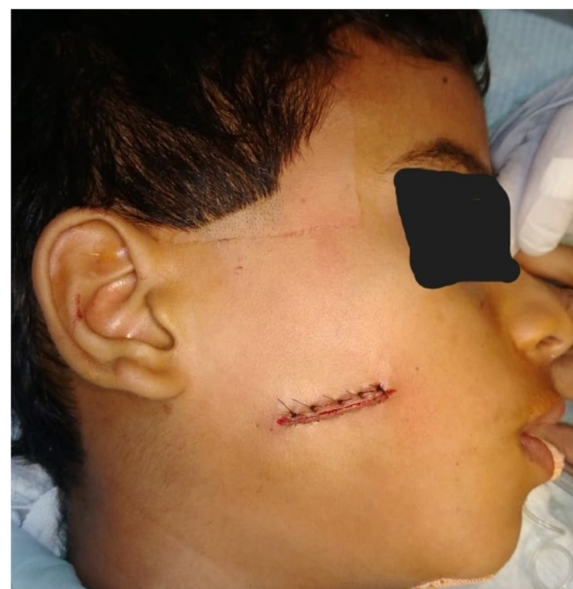

Fig. 7 Immediate post op image of the patient

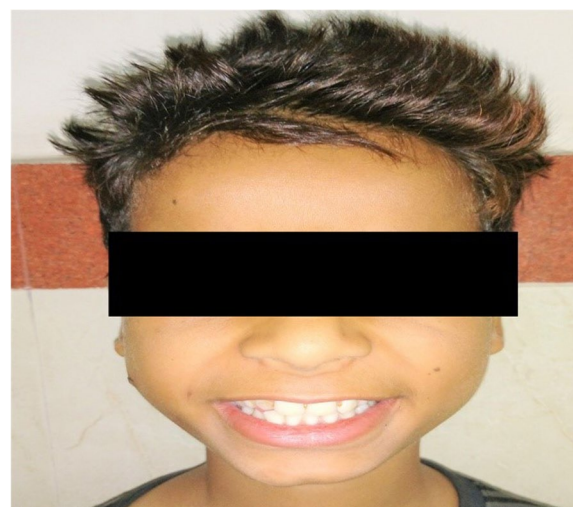

Fig. 8 Image of the patient after 1 month

in it. Human beings develop cysticercosis through fecal or oral contamination with eggs of pork tapeworm. Thus, vegetarians can also be on risk of developing cysticercosis [9]. Infection of tapeworm occurs by ingestion of poorly cooked or uncooked pork which contains encysted larval forms of tape worm (*Taenia solium*). The wall of larva is destroyed by gastric secretions, releasing scolex (head of tapeworm) which passes to the small intestine. It gets attached to the small intestine and develops into adult tapeworm. In 5–12 weeks, adults continuously pass gravid segments containing thick-walled eggs

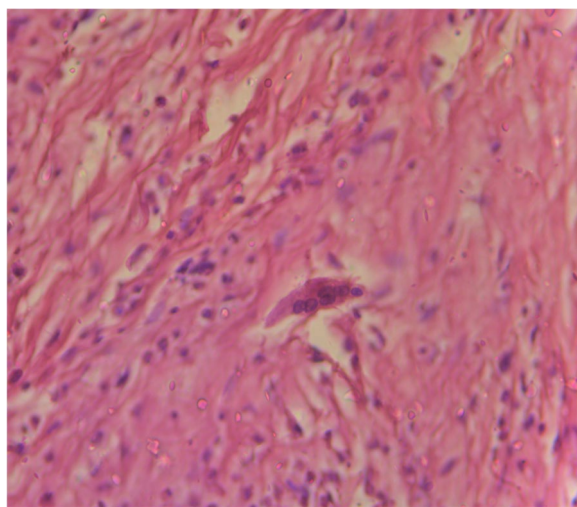


Fig. 9 Histopathological picture

(oncospheres) into feces. Oncospheres remains viable in soil for days to months. When pig or human ingests the eggs, oncospheres are released due to gastric secretions which dissolve its shell. The oncospheres penetrate the wall of small intestine and spread via vascular or lymphatic channels throughout the body and reach the muscles, eye, brain, cheek, and other parts of body [5, 10, 11].

Kumar et al. [12] reported similar cases of cysticercosis of masseter muscle which was diagnosed by ultrasonography and underwent excisional biopsy, which revealed cysticercosis.

Riju et al. [13] also reported similar case of cysticercosis of cheek. Which was diagnosed by ultrasonography followed by surgical excision and histopathology examination which confirmed the diagnosis of cysticercosis.

The differential diagnosis may include lipomas, tubercular lymphadenitis, dermoid cysts, and benign neoplasms of salivary gland, neurofibroma, and epidermal inclusion cysts.

Radiologic imaging (ultrasonography, computed tomography, and magnetic resonance imaging), serology, cytology, and tissue biopsy can be helpful tool for diagnosis of cysticercosis [14].

Treatment depends on symptoms and area involved. No medical or surgical treatment required for inactive disease. Medical management includes anti-helminthics as praziquantel and albendazole. Surgical excision is usually done for isolated skeleton muscles lesions or lesion causing symptoms or for cosmetic issues [3, 5, 9, 10].

Well-defined, nodular swelling of cheek should be considered for diagnosis of cysticercosis. Surgical management has important role for extra cranial and well-defined swelling.

Acknowledgements

None

Authors' contributions

SG and MP have assisted in the surgery and written the first draft of manuscript. HP is the lead surgeon and prepared the final draft of the manuscript in consultation of SB, who also did the HPE examination of the excised specimen. The author(s) read and approved the final manuscript.

Funding

NA

Availability of data and materials

NA

Declarations

Ethics approval and consent to participate

Obtained from Institutional ethics committee, King George's Medical University. Reference no. is not applicable. Written informed consent for the treatment was obtained from the patient's father.

Consent for publication

A written informed consent for publication of the patient's details and images was obtained from the patient's father.

Competing interests

The authors declare that they have no competing interests.

Author details

¹Department of ENT, Prasad Institute of Medical Sciences, Lucknow, Uttar Pradesh, India. ²Department of Otolaryngology & Head-Neck Surgery, King George's Medical University, Lucknow, Uttar Pradesh, India. ³Department of Pathology, King George's Medical University, Lucknow, Uttar Pradesh, India.

Received: 20 May 2022 Accepted: 28 June 2022

Published online: 29 July 2022

References

- Kumar V, Abbas AK, Fausto N (2004) Pathologic basis of disease. In: Robbins SL, Cotran RS (eds) Infectious Diseases, 7th edn. W B Saunders, New York, pp 406–407
- Berkow R (1992) The Merck Manual of Diagnosis and Therapy. In: Beers MH (ed) The nervous system, 16th edn. Merck, Rahway, pp 1274–1275
- Ribeiro ACP et al (2007) Oral cysticercosis case report. *Oral Surg Oral Med Oral Pathol Oral Radiol Endod.* 104:56–58
- Jay A et al (2007) Oral cysticercosis a case report. *Brit J Oral Max Surg.* 45:331–334
- Ramraje S, Bhatia V, Goel. (2011) A solitary intramuscular cysticercosis A REPORT OF two cases. *AMJ* 4:58–60
- Chopra JS, Nand N, Jain K, Mittal R, Abrol L (1986) Generalized muscular pseudohypertrophy in cysticercosis. *Postgrad Med J* 62:299–300
- Fazakerley MW, Woolgar JA, Cysticercosis cellulosae. (1991) An unusual cause of a labial swelling. *Br Dent J* 170:105–106
- Timosca G, Gavriluta L (1974) Cysticercosis of the maxillofacial region. A clinicopathologic study of 5 cases. *Oral Surg Oral Med Oral Path* 37:390–400
- García HH, Gonzalez AE, Evans CAW, Gilman RH (2013) Taenia solium cysticercosis. *Lancet.* 362:547–556
- Park SY, Kong MH, Kim JH, Song KY (2011) Disseminated Cysticercosis. *JKorean Neurosurg Soc* 49:190–193
- Rastogi S, Arora P, Devi P, Wazir SS, Kapoor S (2013) Importance of ultrasonography and magnetic resonance imaging in diagnosis of cysticercosis of temporalis muscle mimicking temporal space infection. *Contemp Clin Dent.* 4:504–508

12. Kumar BD, Dave B, Meghana SM (2011) Cysticercosis of masseter. *Indian J Dent Res.* 22:617
13. Riju JJ, Shiva Kumar AM, Sashikala P (2018) Cysticercosis of Cheek: A CaseReport. *J Microbiol Pathol* 2:109
14. Romero De Leon E, Aguirre A (1995) Oral cysticercosis. *Oral Surg Oral Med Oral Path Oral. Radiol Endod* 79:572–577

Publisher's Note

Springer Nature remains neutral with regard to jurisdictional claims in published maps and institutional affiliations.

Submit your manuscript to a SpringerOpen[®] journal and benefit from:

- Convenient online submission
- Rigorous peer review
- Open access: articles freely available online
- High visibility within the field
- Retaining the copyright to your article

Submit your next manuscript at ► [springeropen.com](https://www.springeropen.com)