

CASE REPORT

Open Access



# Asymptomatic idiopathic submandibular abscess — a diagnostic conundrum

Shreya Agarwal<sup>1</sup> and Nimish Gupta<sup>2\*</sup>

## Abstract

**Background:** Facial and neck abscesses are often seen in patients. Usually, they are linked to a primary source of infection in orofacial, dental, or otolaryngeal region and are associated with the classic signs and symptoms of infection and inflammation. We came across a case of submandibular abscess whose behavior pattern defied the typical trends.

**Case presentation:** A completely asymptomatic boy reported with a huge swelling below the left-side lower jaw, extending onto the neck region. The history of swelling was acute with progressive nature since the last 5–6 days. His clinical examination and the laboratory investigations were quite routine without any deviation from usual. Despite exploring for all probable causes, authors could not find the definitive reason for such unusual presentation.

**Conclusion:** Although the patient was cured with conventional medical and surgical treatment for head and neck space infection, the pathophysiology of such asymptomatic and idiopathic abscess remained a diagnostic dilemma.

**Keywords:** Asymptomatic, Idiopathic, Submandibular abscess

## Background

Abscess in facial regions and in neck is quite commonly seen in otolaryngology and maxillofacial outpatient departments. An obvious swelling with raised temperature, inflamed skin, pain, and restricted function are few of the common symptoms invariably associated with such infections. The apparent cause for such infections is also quite evident on either clinical examinations or on investigations. We wish to discuss a patient whose symptoms, clinical examination, and investigations did not correlate with above dictum and whose unusual presentation although cured remained a topic of curiosity.

## Case presentation

### History and examination

A 10-year-old boy visited the outpatient department with complaint of swelling on left lower third of face since the

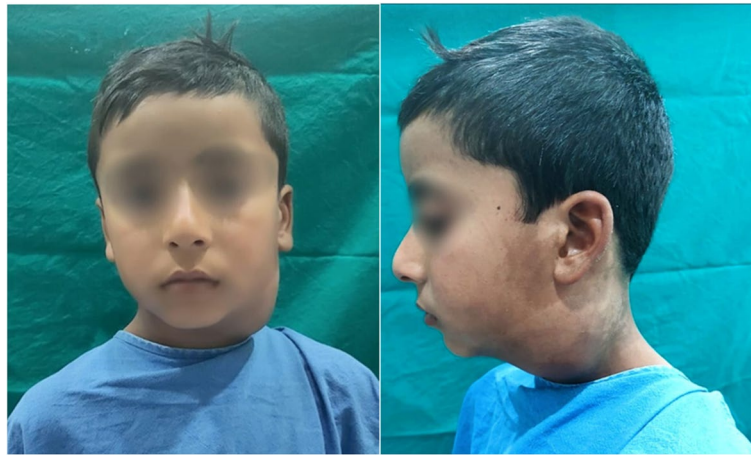5–6 days. Patient was perfectly healthy before, and there was no history of any other complaints prior to start of swelling. No relevant medical history was reported. Swelling was completely asymptomatic and painless. Swelling started spontaneously and progressed to its present size of approx. 5.0 cm in diameter (Fig. 1).

Physical examination revealed a soft, non-tender swelling with areas of fluctuant, extending from lower border of mandible to approximately three and half finger width below the lower border of mandible. Anterio-posteriorly, the swelling extended from lateral aspect of the chin to the postauricular region over mastoid. The skin over the swelling was completely normal devoid of any signs of inflammation. There was acute increase in size of swelling with no other symptoms as per patient's parents. Oropharyngeal, dental, orofacial examination, and laryngoscopy were clear and unremarkable. Mouth opening was normal and absolutely painless. Salivary flow from submandibular and sublingual gland was normal.

Patient's general condition was fair, and there was no fever or any other signs of ongoing infection. No

\*Correspondence: [dr.gupta.1088@gmail.com](mailto:dr.gupta.1088@gmail.com)

<sup>2</sup> Maxillofacial Surgeon, Swami Vivekanand Hospital, Dharmawala, India  
Full list of author information is available at the end of the article



**Fig. 1** Frontal and lateral view of submandibular swelling

lymphadenopathy was noted clinically in other sites of head and neck region.

**Investigations**

Investigation reports including chest X-ray, ECG, hematological and serological parameters, biochemical tests, and urine analysis were well within normal limits. Ultrasound and CT scan were planned, and aspiration of swelling was done with wide bore needle. Pus sample collected from aspiration was sent for routine microbiology, culture, and sensitivity. PCR for mycobacterium tuberculosis complex (MTC) was also done.

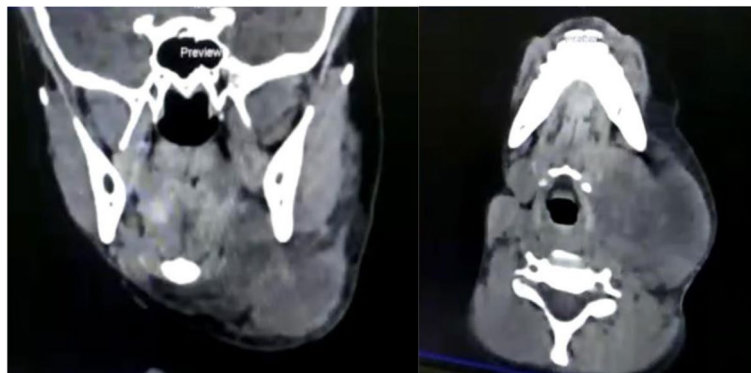
PCR for MTC came negative, so suspicion of cold abscess was ruled out. Microbiology of pus revealed heavy growth of *Staphylococcus aureus* sensitive to penicillin and cephalosporin group of drugs.

Ultrasonography was suggestive of heterogenous, hypoechoic lesion within submandibular space. There were no signs of submandibular gland involvement or

sialolith formation. CT revealed enlarged conglomerate of level 2 lymph nodes with the largest one measuring  $5.5 \times 4.5 \times 6.5$  cm with pus accumulation (Fig. 2).

**Treatment**

With suspicion of lymphoma or metastatic lymphadenopathy, patient was planned for biopsy and incision and drainage (I&D) of abscess. Antibiotic therapy was started as per guidelines, and I&D of submandibular abscess was done as per routine protocol, under general anesthesia. Pus and tissue were collected for further investigation. Pus cytology and histopathological examination of tissue fragments are indicated towards pyogenic abscess. Patient was discharged 3 days later, and his recovery was uneventful. Patient is on regular follow-up for the last 4 months and is perfectly healthy, without any complaints.



**Fig. 2** Coronal and axial CT of submandibular swelling

## Discussion

Abscesses of orofacial and neck region are common sights in otolaryngology and dental department, OPDs. They are invariably associated with the signs and symptoms of inflammation and infection. Pain and decreased function are the common complaints of patients. Normally, tracking the source of infection is an easy task, and it is mostly apparent on examination. Here, we came across a young child with spontaneous, acute, and massive swelling, which was completely asymptomatic and no evident source of infection. Although it was treated with antibiotics and I&D, its unique nature of presentation is still a dilemma.

To our knowledge, there is not much literature on such atypical abscess except for two case series presented by E. O. Adekeye et al. [1] and D. Blinder et al. [2] in 1978 and 1985, respectively. In both case series, the authors concluded with probable causes of infections, and the definitive source of infection remained undiagnosed. E. O. Adekeye et al. [3] found several debilitating conditions and mentioned them as probable cause of diminished resistance and infections. Our patient's history and clinical examination revealed no such issue. Our case had another unique characteristic that such a massive swelling was absolutely asymptomatic.

## Conclusion

Head and neck abscesses are usual site with peculiar symptoms. These abscesses are the secondary manifestation of primary pathology, generally located in vicinity. Our training guides us to look for source of infection and treat accordingly. Delineating the origin of infection is a calming factor to restless mind of clinician. But sometimes, very common pathologies are present in a unique fashion to challenge our conventional concepts.

With this brief communication, we expect to receive valuable inputs on this peculiar orofacial abscess presentation.

## Acknowledgements

No other acknowledgements required.

## Authors' contributions

SA was the operating ENT surgeon, and NG involved in clinical and investigative workup of patient. NG was the major contributor in writing the manuscript. The authors read and approved the final manuscript.

## Funding

Not applicable. There were no funding sources related to this manuscript.

## Availability of data and materials

Not applicable. The manuscript does not contain any data. The rest of all information is included in this manuscript.

## Declarations

### Ethics approval and consent to participate

All procedures performed in studies involving human participants were in accordance with the ethical standards of the institution and with the 1964 Helsinki Declaration and its later amendments or comparable ethical standards. Consent to participate was taken from the patient's parent.

### Consent for publication

The written consent for publication was obtained from the patient's parent in his native language.

### Competing interests

The authors declare that they have no competing interests.

### Author details

<sup>1</sup>ENT Surgeon, Swami Vivekanand Hospital, Dharmawala, India. <sup>2</sup>Maxillofacial Surgeon, Swami Vivekanand Hospital, Dharmawala, India.

Received: 14 March 2022 Accepted: 9 June 2022

Published online: 23 July 2022

## References

1. Adekeye EO, Brown AE, Adekeye JO (1978) Cervicofacial abscesses of unknown origin. A survey of eighty-one cases. *Oral Surg Oral Med Oral Pathol.* 45(6):831–840
2. Blinder D (1986) YRamon, S Hendler, M Peleg Idiopathic submandibular abscesses in children. *Int. J. Oral Maxillofac. Surg.* 15(3):292–295
3. Adekeye EO, Adekeye JO (1982) The pathogenesis and microbiology of idiopathic cervicofacial abscesses. *J Oral Maxillofac Surg.* 40(2):100–106

## Publisher's Note

Springer Nature remains neutral with regard to jurisdictional claims in published maps and institutional affiliations.

Submit your manuscript to a SpringerOpen<sup>®</sup> journal and benefit from:

- Convenient online submission
- Rigorous peer review
- Open access: articles freely available online
- High visibility within the field
- Retaining the copyright to your article

Submit your next manuscript at ► [springeropen.com](https://www.springeropen.com)