

ORIGINAL ARTICLE

Open Access



# Relationship of sphenoid sinus to adjacent structures in South India: a retrospective cross sectional study

Amardeep Singh<sup>1\*</sup> , K. Manjunath<sup>1</sup> and Harbans Singh<sup>2</sup>

## Abstract

**Background:** Sphenoid sinus is one of the most inaccessible paranasal sinuses. Advent of minimally invasive trans-nasal trans-sphenoidal approach over the past few years has provided an additional armament in the hands of skull-base surgeons to access pathologies adjoining base of skull. Close relationship of vital neurovascular structures with sphenoid sinus and variability of their protrusions into the sinus make these structures more vulnerable to iatrogenic trauma during surgical procedures. Preoperative assessment of such variations is imperative to avoid unintentional damage. The present study is a retrospective study conducted on CT scan records of 140 patients with an aim to evaluate prevalence of vital structures invaginating into sphenoid sinus and their clinical implications. The internal carotid artery (ICA), optic nerve (ON), maxillary nerve (MN), and Vidian nerve (VN) were assessed for protrusion into the sphenoid sinus and their dehiscence. Attachment of septum to protruding structures was also assessed. Data was statistically analyzed in the form of frequency and percentage to evaluate the prevalence of neurovascular invaginations into sphenoid sinus and their clinical implications.

**Results:** ICA invagination was observed in 16% of males and 12% of females with males showing higher frequency on left side. Protrusion of ON was seen in 13% of males and 10% of females with higher prevalence in bilateral category. Twenty-four percent of study population had MN prominences which included 13% of males and 11% of females with higher reflection of bilateral presentation. Highest prevalence of 44% was observed in VN protrusions with equal distribution (22%) among each sex. Majority of these were bilaterally located. Dehiscence of ICA was observed in 9%, ON in 29%, MN in 10%, and VN in 30% of study population. Dehiscence brings these structures closure to sinus mucosa with increased risk of involvement in sinus disease. Septal attachment to ICA and ON was present in 7% and 15% cases respectively.

**Conclusion:** Preoperative assessment of anatomical configuration of sphenoid sinus and associated neurovascular structures is mandatory to minimize per-operative complications. This study provides statistical data on anatomical variations in neurovascular structures protruding into the sphenoid sinus, their dehiscence, and septal attachments in South Indian population.

**Keywords:** Sphenoid sinus, CT scans, Neurovascular protrusions, Anatomical variations, Trans-sphenoidal surgeries

## Background

Sphenoid sinus forms an important natural corridor in skull base surgeries to not only access the sellar region but also to approach the pathologies located in the middle and posterior cranial fossae [1]. Sphenoid sinus is the first sinus to develop in the third or fourth months of intra-uterine life one on each side of the midline. Up to

\*Correspondence: [thesingh7@gmail.com](mailto:thesingh7@gmail.com)

<sup>1</sup> Department of ENT, Basaveshwara Medical College and Hospital, Chitradurga, Karnataka, India

Full list of author information is available at the end of the article

3 years after birth, it is seen as a pit in the sphenoid recess. Pneumatization of sinus begins at the age of four years and definitive cavity is formed at puberty [2]. Degree of pneumatization of sphenoid and its extensions into various components of bone like greater wings, lesser wings, pterygoid processes, and basi-occiput vary in different ethnic groups [3]. Developmental expansion of the sinus is retarded in areas where structures like nerves and vessels are present, whereas it is relatively easier for aerations to expand in the areas between these structures. As pneumatization of sinus proceeds, there is an enhancement in the expansion of the sinus around the contiguous neurovascular structures. This results in the formation of irregularities or protrusions of adjoining structures inside the sinus to a variable extent [4]. In case of hyper-pneumatization, bony coverings of protruding vessels and nerves may become very thin or even disappear, making these structures dehiscent and more vulnerable to iatrogenic trauma during surgery [5, 6]. Sphenoid sinuses are usually asymmetrical cavities separated from each other by inter-sinus septum which is mostly oriented in vertical plane but not necessarily central in position. Multiple septa have also been reported in literature [7, 8]. Some of the septa may be attached to thin bony covering of vital neurovascular structures protruding into the cavity of sinus and in dehiscent cases directly to the nerves and vessels. The purpose of the present study is to assess prevalence of anatomical variations in interrelationship of the sphenoid sinus and neurovascular structures closely associated with it and their clinical significance.

## Methods

A retrospective study was conducted on the basis of medical records of 140 patients who had undergone CT scanning of paranasal sinuses (PNS) for any morbidity involving this region. The study covered the period extending from January to November 2019 in Basaweshwara Medical College and Hospital, Chitradurga, Karnataka. Siemens Somatom MDCT, 128 slices, dual-energy CT scanner was used for scanning. For this

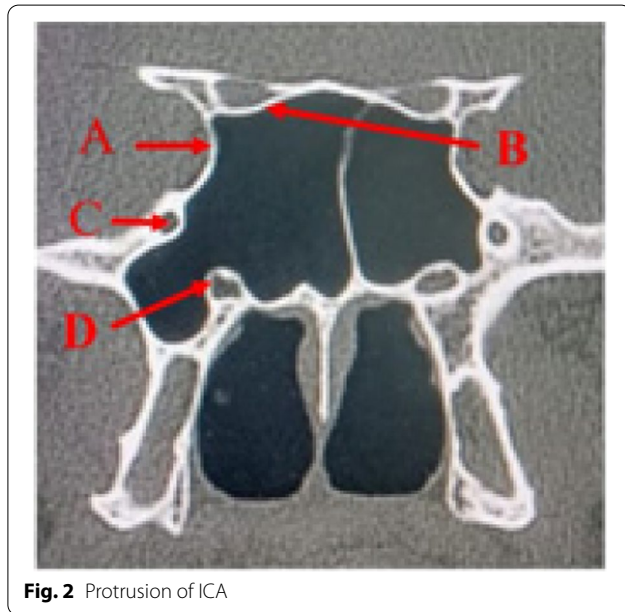
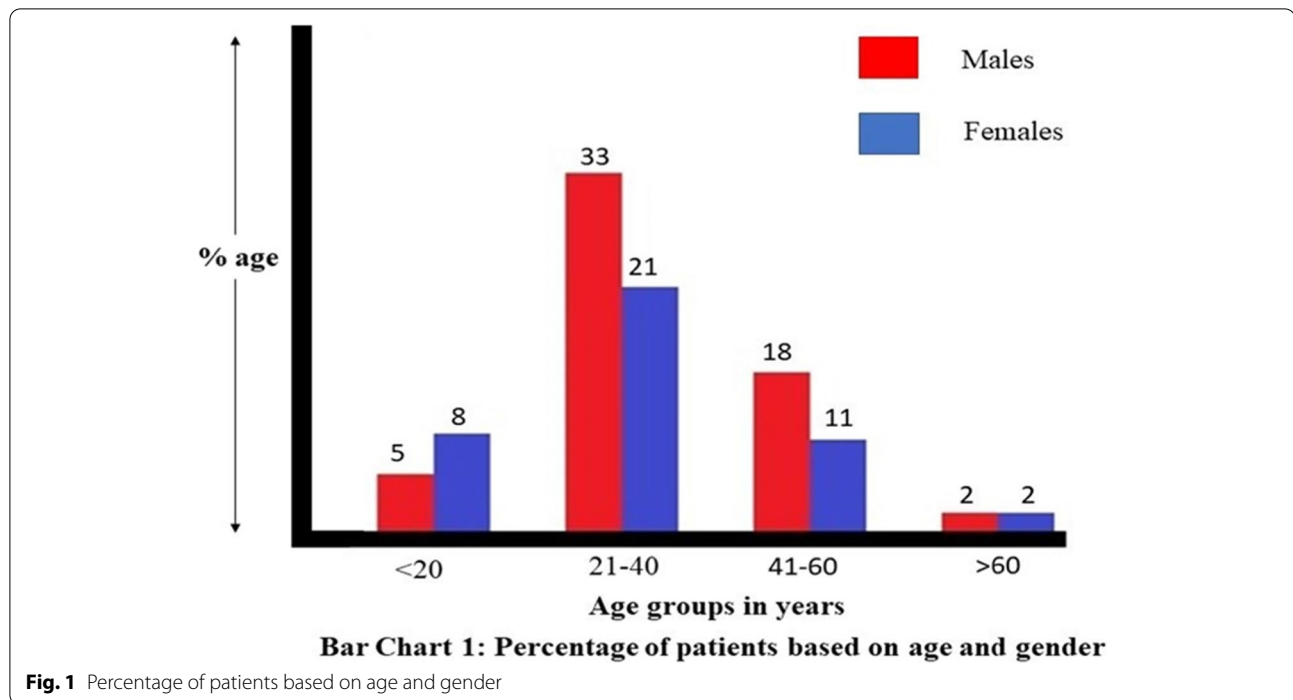
topographic study, coronal sections of the sphenoid sinus were observed to investigate variations in neurovascular structures invaginating into the sphenoid sinus. Variants included in the present study were internal carotid artery (ICA), optic nerve (ON), maxillary nerve (MN), and Vidian nerve (VN). Normally term dehiscence is used to denote absence of the bony wall between the projecting structure and sinus, but sometimes, there is an absence of clarity in CT scan when the wall is very thin. Therefore, we used the criteria adapted by Hewadi et al. [6] for defining dehiscence, i.e., when there is difficulty in demarcating very thin wall and total dehiscence, the result is accepted as dehiscence. The variations in attachments of the inter-sinus septum to the walls of protruding structures were also recorded. Data so obtained was statistically analyzed in the form of frequency and percentage to evaluate the prevalence of neurovascular invaginations into sphenoid sinus and their clinical implications. For calculation of percentage, the total number of patients is taken into consideration.

## Results

A total of 140 patients ranging between 18 and 80 years were evaluated in the present study. Out of these, 58% were males and 42% females. Majority of these were in the age group of 21–40 years (54%) followed by 41–60 years (29%). Minimum cases (04%) were in the group above 80 years (Table 1 Fig. 1). Protrusion of ICA (Fig. 2A) was observed in 28% cases which included 16% males and 12% females. Males showed higher frequency of protrusion on left side (7%) followed by bilateral protrusion (6%). In females, side-based differences in ICA invaginations were insignificant. Frequency of ON protrusion (Fig. 2B) was seen in 13% males and 10% females with higher prevalence in bilateral category in both sexes (8% and 5% respectively). Protrusions of MN (Fig. 2C) was observed in 13% males and 11% females. Majority of these were bilaterally located (9% males and 5% females). Forty-four percent of study population had protruded VN (Fig. 2D) with equal distribution of 22% in each gender. In this group, also, bilateral occurrence was the commonest

**Table 1** Demographic characteristics

Age (years)	Frequency (n = 140)			Percentage (%)		
	Male	Female	Total	Male	Female	Total
<20	07	12	19	05	08	13
21–40	44	30	74	33	21	54
41–60	26	15	43	18	11	29
>60	03	03	06	02	02	04
	<b>80</b>	<b>60</b>	<b>140</b>	<b>58</b>	<b>42</b>	<b>100</b>



presentation which included 14% males and 11% females (Table 2). Dehiscence of ICA (Fig. 3A) was present in 9% cases which included 3% males and 6% females with right-sided preference in females. Twenty-nine percent of patients had ON dehiscence (Fig. 4A) with higher percentage in males (18%) than females (11%). Bilateral dehiscence of ON (11% males and 6% females) surpassed unilateral occurrence in both sexes. Distribution

of MN dehiscence (Fig. 5A) was present in 5% cases both in males and females without significant preference for gender and side. Dehiscence of VN (Fig. 5B) also showed equal distribution in both sexes (15% each). Majority of these (17%) had bilateral presentation which included 9% male and 8% female patients (Table 3). Attachment of inter-sinus septum to ICA protrusion (Fig. 6A) was present in 3% males and 4% females. None of the dehiscent ICA cases had septal attachment. ON projection with septal attachment (Fig. 4B) was seen in 15% patients (9% males and 6% females). Two percent individuals in each gender had dehiscent ON. None of the subjects with MN and VN protrusions had septal attachments (Table 4).

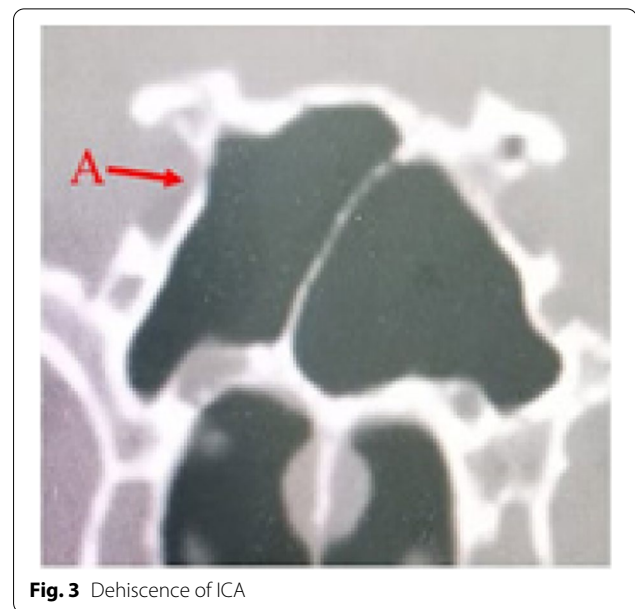
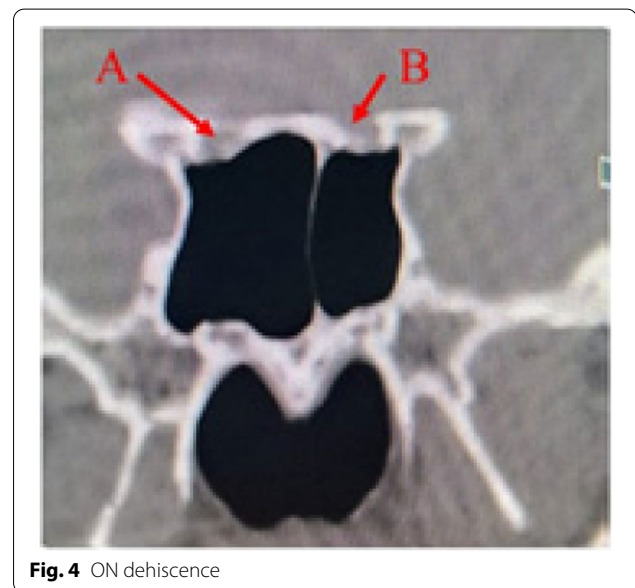## Discussion

Advent of trans-nasal trans-sphenoidal approach to structures around sphenoid bone has drastically declined the inherent complications associated with trans-septal, trans-antral, and extracranial approaches to the regions adjoining it [8]. Trans-nasal procedures originally restricted to paranasal sinuses have now been expanded to tackle skull-based pathologies and lesions involving various cranial fossae. Access to these areas demands thorough understanding of variations in sphenoid sinus as well as configuration of vital neurovascular structures located in close relation to it [7, 9]. Computerized tomographic imaging provides an important tool for accurate mapping of bony and soft tissue structures neighboring paranasal sinuses.

**Table 2** Protrusion of ICA, ON, MN and VN

Protruding structures (%)	Gender	Location side	Frequency (n)	Percentage (%)		
ICA (28%)	Male	Right	04	03		
		Left	10	07		
		Bilateral	08	06		
		<b>Total</b>	<b>22</b>	<b>16</b>		
	Female	Right	06	04		
		Left	04	03		
		Bilateral	07	05		
		<b>Total</b>	<b>17</b>	<b>12</b>		
		ON (23%)	Male	Right	03	02
				Left	04	03
Bilateral	11			08		
<b>Total</b>	<b>18</b>			<b>13</b>		
Female	Right		03	02		
	Left		04	03		
	Bilateral		07	05		
	<b>Total</b>		<b>14</b>	<b>10</b>		
	MN (24%)		Male	Right	03	02
Left		03		02		
Bilateral		13		09		
<b>Total</b>		<b>19</b>		<b>13</b>		
Females		Right	03	02		
		Left	05	04		
		Bilateral	07	05		
		<b>Total</b>	<b>15</b>	<b>11</b>		
		VN (44%)	Male	Right	03	02
				Left	08	06
Bilateral	20			14		
<b>Total</b>	<b>31</b>			<b>22</b>		
Female	Right		07	05		
	Left		08	06		
	Bilateral		16	11		
	<b>Total</b>		<b>31</b>	<b>22</b>		

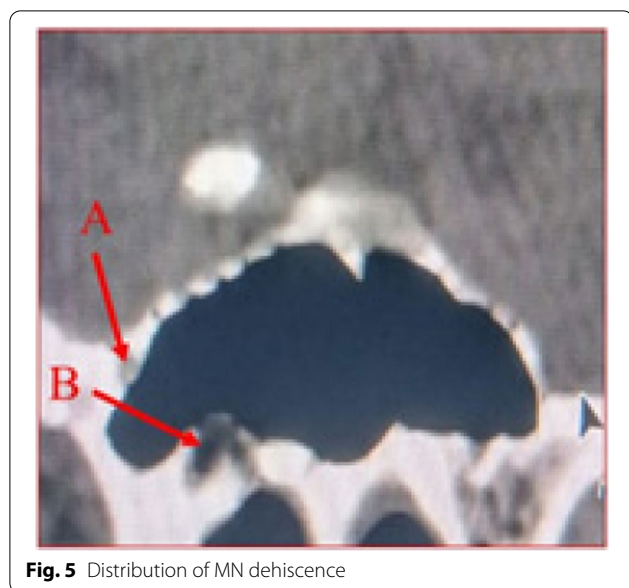
Enhanced pneumatization of sphenoid brings vital neurovascular structures closer to the cavity of sinus. This increases the vulnerability of these structures to iatrogenic surgical complications which at times become too difficult to manage. Prior evaluation of these structures and their relationship with sinus provides invaluable guidance to the endoscopic surgeon both in diagnostic and procedural workup [6, 10]. In present study, indentation of lateral wall of sphenoid sinus by ICA was present in 28% of cases. These figures closely match with the figures observed by Sirikci et al., 26.1% [11], Fasnula et al., 27.3% [12], Sethi et al., 29% [13], and Bademci et al., 31.1% [14]. However, much higher frequencies of ICA protrusions have been reported by Hewaidi et al.,

**Fig. 3** Dehiscence of ICA**Fig. 4** ON dehiscence

41% [6], Tan et al., 67.7% [7], and Fuji et al., 98% [15]. Apparent differences in prevalence of ICA bulges indifferent races are suggestive of ethnic predisposition [6].

Existence of ON bulge in sphenoid sinus was seen in 23% patients. However, higher occurrences of ON protrusions were observed by Bademci et al., 34.4% [14], Devoodiet al., 36.45% [16], Mamatha et al., 50% [17], and Tan et al., 69.8% [7]. High prevalence of ON bulge increases the probability of surgical trauma resulting in varying degrees of blindness. ON, by its inherent position in optic canal, is already in a compromised position with





**Fig. 5** Distribution of MN dehiscence

poor nourishment. This location also makes it highly susceptible to secondary compression due to spread of inflammation from sphenoid sinus which offers potential for causing visual impairments [17]. Impression of ON was bilaterally present in 13% cases in our study. Sethi et al. [13] noticed bilaterally located ON protrusions in all the specimens examined.

Maxillary nerve frequently produces bulge in the sphenoid sinus. Prevalence of MN protrusion in the present study was seen in 24% of subjects with bilateral occurrence of 14%. Exceedingly high occurrence of 96% was observed by Fuji et al. [15]. In our study, VN was the most frequently protruding structure in sphenoid sinus seen in 44% of patients with equal distribution (22%) among both sexes. Tan et al. [7] found VN bulge in 64.6% of patients. Substantial degrees of variations in prevalence rates of neurovascular protrusions reflect differences among different ethnic groups.

The present study revealed dehiscence of ICA in 9% cases which corroborates with the findings of Tan et al., 8% [7]. Relatively lower occurrence has been mentioned in the literature, Ren et al., 4% [18], Elwany, 4.8% [19], and Sareen, 5% [8]. If the surgeon has no prior knowledge about dehiscence, fatal hemorrhage may occur during surgery. Uncovered ICA also makes ICA more vulnerable to get involved in sinus infection with serious prognostic outcome.

In the present study, ON dehiscence was found in 29% of patients, whereas Fujii et al. [15] found that 4% cases had no bone separating ON sheath and sinus mucosa. A study in North-Central India reported ON dehiscence in 65% of patients [8]. Dehiscence of ON

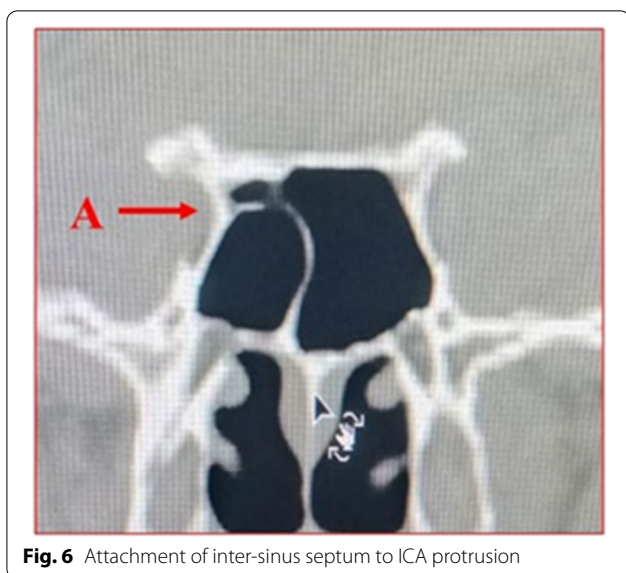
**Table 3** Dehiscence of ICA, ON, MN, and VN

Structure protruding (%)	Gender	Location side	Frequency (n)	Percentage (%)
ICA (9%)	Male	Right	01	01
		Left	00	00
		Bilateral	03	02
		<b>Total</b>	<b>04</b>	<b>03</b>
	Female	Right	07	05
		Left	01	01
		Bilateral	00	00
		<b>Total</b>	<b>08</b>	<b>06</b>
ON (29%)	Male	Right	10	07
		Left	00	00
		Bilateral	15	11
		<b>Total</b>	<b>25</b>	<b>18</b>
	Female	Right	04	03
		Left	03	02
		Bilateral	08	06
		<b>Total</b>	<b>15</b>	<b>11</b>
MN (10%)	Male	Right	01	01
		Left	03	02
		Bilateral	03	02
		<b>Total</b>	<b>07</b>	<b>05</b>
	Female	Right	01	01
		Left	03	02
		Bilateral	03	02
		<b>Total</b>	<b>07</b>	<b>05</b>
VN (30%)	Male	Right	01	01
		Left	07	05
		Bilateral	13	09
		<b>Total</b>	<b>21</b>	<b>15</b>
	Female	Right	03	02
		Left	07	05
		Bilateral	11	08
		<b>Total</b>	<b>21</b>	<b>15</b>

further enhances the risk of damage by surgical trauma or sinus disease culminating in visual deficits.

MN dehiscence in our group was present in 10% of cases with equal prevalence (5%) in both sexes. This is comparable to 13% of MN dehiscence observed in Libyan population [6]. Fujii et al. [15] encountered dehiscence of MN only in 2% patients. However, Sareen et al. [8] did not find any dehiscence of MN in all cases studied. Protrusion or dehiscence of this nerve makes it prone to neuritis from sphenoid sinusitis which presents as trigeminal neuralgia [6].

Out of all dehiscence cases studied in this cohort, VN dehiscence showed highest frequency of 30% with bilateral occurrence in 17% cases. Prevalence of 37%



**Fig. 6** Attachment of inter-sinus septum to ICA protrusion

dehiscence with 15.3% bilateral representation has been reported by Hewaidi et al. [6]. Uncovered VN is liable to get involved in pathologies of sphenoid sinus leading to referred pain in nasal cavity, a clinical condition called Vidian neuralgia [6].

Attachment of septum to ICA was present in 7% of our group nearly tallying with the occurrences of 4.5% in ethnic Africans [12]. Bademci [14], Kashyap [20], and Fernandez-Miranda [21] noticed the insertion of septa to ICA in 27.7%, 35%, and 85% patients respectively. None of the patients had septal attachment to dehiscent ICA in our study. We recorded ON protrusions with attached

septa in 15% of subjects which included 4% dehiscent cases. These figures are much higher when compared to 2.5% observed in North Central Indian population [20]. The present cohort did not reveal attachment of septum to MN and VN both. Septal attachments to bulging structures, particularly those with dehiscent walls, increase their susceptibility to iatrogenic damage. Utmost care is required while negotiating with septa during surgical procedures to minimize the chance of neurovascular trauma.

### Conclusions

In recent years, trans-nasal, trans-sphenoidal endoscopic surgery has emerged as an important surgical modality for approaching areas beyond the limits of paranasal sinuses. The procedure involves better understanding of anatomical structures located in the area concerned. Huge number of variations exist in sphenoid sinus and neurovascular structures protruding into it in different ethnic groups. These structures lead to complexity of symptoms and also potentially serious surgical complications. Detailed pre-operative imaging is imperative to assess different anatomical configurations of sphenoid sinus and structures around it. The present study provides the statistical data on the frequency of sphenoid sinus protrusions and their dehiscence and implications in surgical procedures in South Indian population. Surgical outcome in such cases depends on the adhering to the both anatomical and surgical principles.

**Table 4** Attachment of sphenoid sinus septum to protruding structures

Structure to which attached (%)	Gender	Frequency (n)	Percentage (%)
ICA (07%)	Male	04	03
	Female	06	04
	<b>Total</b>	<b>10</b>	<b>07</b>
ICA with dehiscence (00%)	Male	00	00
	Female	00	00
	<b>Total</b>	<b>00</b>	<b>00</b>
ON (15%)	Male	12	09
	Female	09	06
	<b>Total</b>	<b>21</b>	<b>15</b>
ON with dehiscence (04%)	Male	03	02
	Female	03	02
	<b>Total</b>	<b>06</b>	<b>04</b>
MN and VN with or without dehiscence (00%)	Male	00	00
	Female	00	00
	<b>Total</b>	<b>00</b>	<b>00</b>

**Abbreviations**

ICA: Internal carotid artery; ON: Optic nerve; MN: Maxillary nerve; VN: Vidian nerve.

**Acknowledgements**

Nil.

**Authors' contributions**

AS: Main contribution in collection of data from radiology department and writing the main manuscript. KM: Did the work of editing the manuscript. HS: Conceptualised the article. All authors have read and approved the manuscript.

**Funding**

No funding.

**Availability of data and materials**

All data generated or analyzed during this study are included in this published article.

**Declarations****Ethics approval and consent to participate**

Research project was approved by Institutional Ethics Review Committee, Basaveshwara Medical College and Hospital, Chitradurga, 577502, with reference number BMC&H/IEC/2019-2020/41. Consent to participate is not applicable as it is a retrospective study.

**Consent for publication**

Not applicable.

**Competing interests**

The authors declare that they have no competing interests.

**Author details**

<sup>1</sup>Department of ENT, Basaveshwara Medical College and Hospital, Chitradurga, Karnataka, India. <sup>2</sup>Department of Anatomy, Institute of Dental Science, Sehora, Jammu and Kashmir, India.

Received: 26 September 2021 Accepted: 3 December 2021

Published online: 24 January 2022

**References**

- Mohebbi A, Rajaei S, Safdarian M, Omidian P (2017) The sphenoid sinus, foramen rotundum and vidian canal: a radiological study of anatomical relationships. *Braz J Otorhinolaryngol* 83:381–387. <https://doi.org/10.1016/j.bjorl.2016.04.013>
- Budu V, Mogoanta CA, Fanuta B, Bulescu I (2013) The anatomical relations of the sphenoid sinus and their implications in sphenoid endoscopic surgery. *Rom J Morphol Embryol* 54(1):13–16
- Hiremath SB, Gautam AA, Sheeja K, Benjamin G (2018) Assessment of variations in sphenoid sinus pneumatization in Indian population: a multidetector computed tomography study. *Indian J Radiol Imaging* 28(3):273–279 <http://www.ijri.org/text.asp?2018/28/3/273/242184>
- Van Alyea OE (1941) Sphenoid sinus: anatomic study, with consideration of the clinical significance of the structural characteristics of the sphenoid sinus. *Arch Otolaryngol* 34(2):225–253. <https://doi.org/10.1001/archotol.1941.00660040251002>
- Rahmati A, Ghafari R, Anjomshoa M (2016) Normal variations of sphenoid sinus and the adjacent structures detected in cone beam computed tomography. *J Dent Shiraz Univ Med Sci* 17(1):32–37 PMID: PMC4771050.PMID: 26966706
- Hewaidi GH, Omami GM (2008) Anatomic variation of sphenoid sinus and related structures in Libyan population: CT scan study. *Libyan J Med* 080307:128–133. <https://doi.org/10.4176/080307> AOP
- Tan HKK, Ong YK (2007) Sphenoid sinus: an anatomical and endoscopic study in Asian cadavers. *Clin Anat* 20:745–750. <https://doi.org/10.1002/ca.20507>
- Sareen D, Agarwal AK, Kaul JM, Sethi A (2005) Study of sphenoid sinus anatomy in relation to endoscopic surgery. *Int J Morphol* 23(3):261–266
- Cavallo LM, Cappabianca P, Galzio R, Iaconetta G, de Divitiis E, Tschabitscher M (2005) Endoscopic transnasal approach to the cavernous sinus versus transcranial route: anatomical study. *Neurosurgery* 56:379–389. <https://doi.org/10.1227/01.neu.0000156548.30011.d4>
- Tiwari R, Goyal R (2015) Study of anatomical variations on CT in chronic sinusitis. *Indian J Otolaryngol Head Neck Surg* 67(1):18–20. <https://doi.org/10.1007/s12070-014-0734-2>
- Sirikci A, Bayazit YA, Bayram M, Mumbuc S, Gunger K, Kanlikama M (2000) Variations of sphenoid and related structures. *Eur Radiol* 10:844–848. <https://doi.org/10.1007/s003300051016>
- Fasunla AJ, Ameye SA, Adebola OS, Ogbole G, Adeleye AO, Adekanmi AJ (2012) Anatomical variations of the sphenoid sinus and nearby neurovascular structures seen on computed tomography of Black Africans. *East Central Afr J Surg* 17(1):57–64
- Sethi DS, Stanley RE, Pillay PK (1995) Endoscopic anatomy of the sphenoid sinus and sella turcica. *J Laryngol Otol* 109(10):951–955. <https://doi.org/10.1017/s0022215100131743>
- Bademci G, Unal B (2005) Surgical importance of neurovascular relationships of paranasal sinus region. *Turkish Neurosurg* 15(2):93–96
- Fujii K, Chambers SM, Rhoton AL Jr (1979) Neurovascular relationship of sphenoid sinus—a microsurgical study. *J Neurosurg* 50:31–39. <https://doi.org/10.3171/jns.1979.50.1.0031>
- Davoodi M, Saki N, Saki G, Rahim F (2009) Anatomical variations of neurovascular structures adjacent sphenoid sinus by using CT Scan. *Pak J Biol Sci* 12(6):522–525. <https://doi.org/10.3923/pjbs.2009.522.525>
- Mamatha H, Saraswathi G, Prasanna LC (2010) Variations of sphenoid sinus and their impact on related neurovascular structures. *Curr Neurobiol* 1(2):121–124
- Renn WH, Rhoton AL Jr (1975) Microsurgical anatomy of the sellar region. *J Neurosurg* 43(3):288–298. <https://doi.org/10.3171/jns.1975.43.3.0288>
- Elwany S, Yacout YM, Talaat M, EL-Nahass M, Gunied A, Talaat A (1983) Surgical anatomy of sphenoid sinus. *J Laryngol Otol* 97(3):227–241. <https://doi.org/10.1017/s0022215100094056>
- Kashyap SK, Purohit JP, Selvaraj S, Kumar V, Moshahary S, Bhan C, Dixit I (2017) Anatomical variations of sphenoidal inter-sinus septa in terms of number and attachments-A CT finding. *Evol Med Dent Sci* 6(12):955–959. <https://doi.org/10.14260/Jemds/2017/204>
- Fernandez-Miranda JC, Prevedello DM, Madhok R, Morera V, Barges-Coll J, Reineman K, Snyderman CH, Gardner P, Carrau R, Kassam AB (2009) Sphenoid septations and their relationship with internal carotid arteries: anatomical and radiological study. *Laryngoscope* 119(10):1893–1896. <https://doi.org/10.1002/lary.20623>

**Publisher's Note**

Springer Nature remains neutral with regard to jurisdictional claims in published maps and institutional affiliations.

**Submit your manuscript to a SpringerOpen® journal and benefit from:**

- Convenient online submission
- Rigorous peer review
- Open access: articles freely available online
- High visibility within the field
- Retaining the copyright to your article

Submit your next manuscript at ► [springeropen.com](https://www.springeropen.com)