

ORIGINAL ARTICLE

Open Access



Experience in endoscopic stapedotomy technique and its audiological outcome: a case series

Nazik E. Abdullah^{1*}, Tarig A. Nafie², Ahmed F. Mohammed³, Alwaleed A. Abdelmomin³, Hashim I. Yagi¹ and Azza M. Ahmed³

Abstract

Background: Stapedotomy is being performed endoscopically for otosclerosis in Sudan since 2011 with increasing number of patients. This prospective hospital-based study from Nov 2016 to Nov 2020 states the clinic-demographic features of otosclerosis; it describes this surgical technique and hearing outcome following endoscopic stapedotomy.

Results: Total number included in the study was 91 patients. Females were 48, and males were 43 with a female to male ratio of 1.1:1. Age ranged from 19 years to 52 with a mean age of 30.6 ± 7 SD years. The main symptom was decreased hearing in all patients (100%); in 82 patients (90%), it was bilateral, followed by tinnitus in 80 patients (88%) while two patients (2.2%) had vertigo. Family history was stated by 2 patients (2.2%) only. Audiological assessment by pure tone audiogram (PTA) for each ear (total of 182) revealed that conductive hearing loss (CHL) is the commonest type of hearing loss in 148 ears (81.3%), mixed type in 30 ears (16.5%), while 4 ears (2.2%) were normal.

Endoscopic stapedotomy was performed for 74 patients; this technique was safe; few complications were managed successfully: one gusher and one revision, with no facial nerve injury. Majority of complications happened during the first year. Mean air bone gap (ABG) gain was 23.3 ± 7.2 dB, air conduction (AC) gain was 18.3 ± 8 dB, and Carhart notch disappeared in 79.5%.

Conclusions: Endoscopic stapedotomy is a safe and effective procedure with a steep learning curve and a satisfactory hearing outcome. The air bone gap (ABG) gain was comparable to international studies.

Keywords: Stapedotomy, Endoscopic, Otosclerosis, Audiological, Outcome

Background

Otosclerosis is a disease of the otic capsule, characterized by bone remodeling that affects the stapediovestibular joint, only when stapes movement becomes compromised with consequent conductive hearing loss, clinical otosclerosis is designated [1, 2]. Histological otosclerosis is more prevalent and may remain asymptomatic [3]. When the otosclerotic focus reaches the

cochlear endosteum, sensory hearing loss ensues, and a mixed type of otosclerosis is defined [4].

Clinically, the main symptom is progressive conductive hearing loss, it occurs bilaterally in 70–80% of the cases, nearly 68% of the patients report tinnitus, and 10% experience vertigo [5, 6]. The clinical form of otosclerosis is more common in women than in men; interestingly, in the histological form of the disease, the ratio between women and men was found to be 1:1 [7]. The average age of onset is in the thirties [6]. Otosclerosis is one of the most common causes of adult-onset hearing loss in the Caucasian population, where it has a prevalence of

* Correspondence: nazikfad1223@yahoo.co.uk

¹Department of Otorhinolaryngology H&N Surgery, Faculty of Medicine, University of Khartoum, P O Box102, Qasr Street, Khartoum, Sudan
Full list of author information is available at the end of the article

0.3–0.4%; its prevalence is lower in Blacks, Asians, and Native Americans [8].

Regarding pathophysiology, viral infection and hormones have been implicated; however, the obvious ethnic predisposition suggests that genetic components play a major role in disease pathogenesis. Additional evidence to support the role of genetics includes familial inheritance studies that to date have identified eight different otosclerosis loci (OTSC1–8). Population-based case-control studies have also associated a number of genes with otosclerosis. Sporadic and familial forms are nearly equal in incidence [9].

Stapes surgery for restoration of sound transmission through the ossicular chain is considered the mainstay of treatment of conductive-type hearing loss in otosclerosis; other options include observation and hearing aid [10]. There is no treatment for the sensorineural component of the disease; however, cochlear implantation for individuals with profound hearing loss due to otosclerosis has been effective [11]. Stapedotomy is considered as a successful surgery in terms of hearing improvement. Complications, such as total sensorineural hearing, facial nerve palsy, and perilymph fistula, could occur at different rates [12].

The steps of the contemporary stapedotomy were described first by Fisch; they can be simplified as removal of the supra-structure of the stapes followed by opening part of the stapes footplate. A prosthesis is fitted into the opening made in the footplate, connecting the incus to the oval window and restoring ossicular conduction by bypassing the fixed footplate [13]. The footplate fenestration of the stapedotomy procedure is now a distant reminder of semicircular canal fenestration [14].

Classically, stapes surgery is performed using the microscope; however, use of endoscope in ear surgery including stapedotomy is gaining popularity [15].

Stapedotomy started to be performed endoscopically for otosclerosis in specialized ENT hospitals in Sudan since 2011 with increasing number of patients, while stapes surgery using the microscope is merely performed by visiting consultant surgeons infrequently.

This study aims at addressing the clinicodemographic features of otosclerosis in the studied group of patients; it describes the technique of endoscopic stapedotomy and reviews the audiological outcome of this technique.

Methods

A prospective hospital-based study during the period Nov 2016 to Nov 2020 was conducted in ENT Khartoum Teaching Hospital and Aldoha Specialized ENT Hospital. All patients who were diagnosed as otosclerosis based on clinical and audiological assessment were included in the study. Patients are informed verbally about the study and signed an informed consent to

participate in this study. Ethical clearance was obtained from the Research Committees of the mentioned Hospitals. Demographic data was reported. The same inclusion criteria were applied for the studied patients in both hospitals.

Audiological assessment

Hearing assessment included pure tone audiogram (PTA), tympanometry, and stapedial reflex for all patients, while speech discrimination test was selectively done for patients with mixed hearing loss. High resolution CT scan of the temporal bone is requested when the clinical and/or audiological data questions the diagnosis of otosclerosis, e.g., congenital hearing loss. Each patient's threshold for air conduction (AC), bone conduction (BC), and air bone gap (ABG) at frequencies 0.5, 1, 2, and 4 kHz were reported before and after surgery. The mean preoperative and post-operative AC, BC, and ABG were also calculated. For the test of significance, we used paired *t* test, and *P* value was considered significant if *P* < 0.05.

Surgical technique

The principles of stapedotomy were described earlier in the "Background" section [13]; they are the same whether using an endoscope or a microscope; the basic difference is that in an endoscopic technique a single hand is operating as the other hand holds the endoscope, whereas in the microscopic, two hands are operating.

Four surgeons performed endoscopic stapedotomy with the same technique for all studied patients; the same surgeons operated on patients in both hospitals. Endoscopic stapedotomy was performed using the endoscopes of 18-cm length, 4-mm diameter, and 0° and 30° lenses. The endoscope was held with the left hand in the case of right-handed surgeon.

Surgery was performed under local anesthesia, infiltration of 2–5 ml of lignocaine with adrenaline 1:200,000 by cannula (size 22) in the external canal skin, 2–3 mm lateral to the junction between hairy and non-hairy skin at 6 and 12 o'clock positions; intravenous analgesia (paracetamol infusion) is administered during the surgical procedure; in few patients, the operation was done under general anesthesia. The endomeatal incision was placed on the external canal wall 5–7 mm lateral to the tympanic annulus from 12 o'clock position to 6 o'clock position; a swab was applied beneath the round knife to protect the flap and make the field clear off blood. The tympanomeatal flap was elevated; posterior scutum bone was partially removed with a curette to expose the oval window and the stapes. Mobility of the stapes was checked by a hook, elevating the incus very gently; another test was used by applying few drops of normal

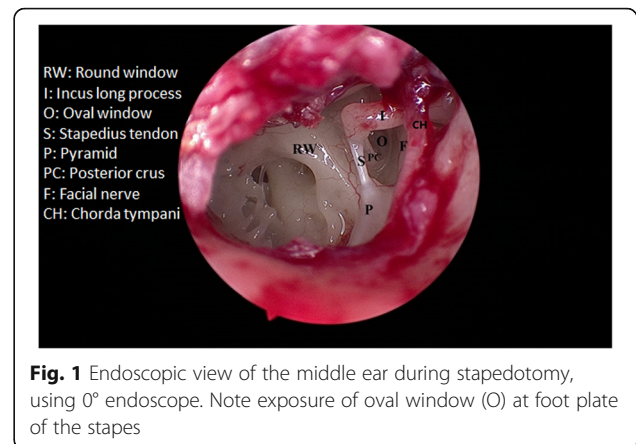
saline to the round window niche; if the foot plate of the stapes was fixed, no movement would be observed on the surface of saline and appears as static light reflection and vice versa, this test could give false impression of stapes fixation if the round window was hidden beyond a prominent niche. After separating the incudostapedial joint with a joint knife and cutting the stapedial tendon, the posterior crus of the stapes was divided with a scissor. The anterior crus of stapes was subsequently down-fractured with a micro hook and removed. The prosthesis was sized by measuring the distance from the footplate to the long process of the incus. A fenestra of 0.7 mm in diameter was made by a perforator (micro pick); middle and posterior part of footplate are typically preferable sites of fenestration. Teflon piston prosthesis 0.6 mm in diameter was used in all cases and positioned after adjustment of its length, encircled over long process of incus and interpositioned in footplate fenestration. Fenestration sealing was done either with lobule fat after prosthesis insertion or with vein graft before insertion of prosthesis, finally, reposition of tympanomeatal flap and placement of gelfoam piece on top of it, medial to the endomeatal incision. On table, subjective hearing improvement was checked. A check list was used to assess this technique by review of recorded surgical videos. The checklist included tympanomeatal flap elevation, integrity of tympanomeatal flap, scutum removal, section of stapedius tendon, separation of incudostapedial joint, fracture of crura, fenestration of foot plate, and insertion of prosthesis.

Dexamethasone 8 mg iv was given at the beginning of surgery, then 8 hourly for 24 h routinely, while cinnarizine was prescribed only for postoperative dizziness.

Results

Total number included in the study was 91 patients. Females were 48, and males were 43 with a female to male ratio of 1.1:1. Age ranged from 19 years to 52 with a mean age of 30.6 ± 7 SD years. The main symptom was decreased hearing in all patients (100%); in 82 patients (90%) it was bilateral, followed by tinnitus in 80 patients (88%) while two patients (2.2%) had vertigo. Family history was stated by 2 patients (2.2%) only. No patient was fitted before with hearing aid. All patients in this study did have normal tympanic membrane on otoscopic examination. Schwartz sign was not observed in any patient.

Audiological assessment by pure tone audiogram (PTA) for each ear (total of 182) revealed that conductive hearing loss (CHL) is the commonest type of hearing loss in 148 ears (81.3%), mixed type in 30 ears (16.5%), while 4 ears (2.2%) were normal. Tympanometry results are as follows: type A was the most frequent, it was

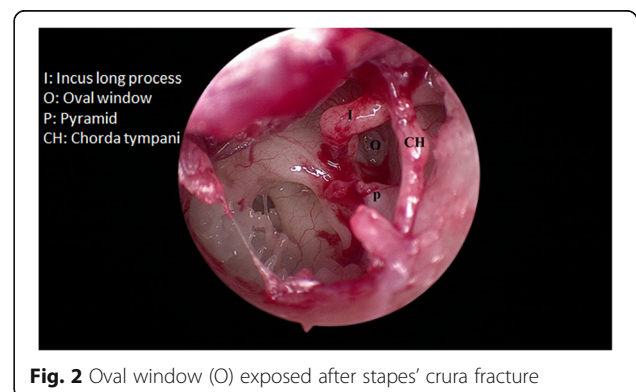


reported in 127 ears (69.8%), type As in 55 ears (30.2%), none of the ears were type B or type C.

Regarding patient's choices for treatment modality after careful examination, audiological assessment, and counseling regarding the diagnosis, prognosis, options of treatment, and possible complications, surgery was chosen by 80 patients (88%) after exclusion of the contraindications of surgery, while 6 patients (7.6%) preferred the option of using a hearing aid. Five patients (5.5%) were advised to use hearing aids as the suitable option for hearing solution; they had mixed hearing loss with moderate to severe sensory element.

Of the eighty patients who were planned for stapedotomy, two patients were excluded later on. In one patient, deformed ossicular chain was anticipated according to CT and confirmed by the presence of non-ossified ossicles, and the other one had abnormal laying facial nerve over the oval window; CT was not performed preoperatively for this case; consequently, stapedotomy was condemned after tympanotomy. Four of the scheduled patients for surgery did not attend.

Endoscopic stapedotomy was performed for 74 patients, as a primary procedure for 73 patients (98.6%) and as revision for 1 patient (1.4%). Duration of surgery was 46 ± 13 SD min. Exposure of middle ear during



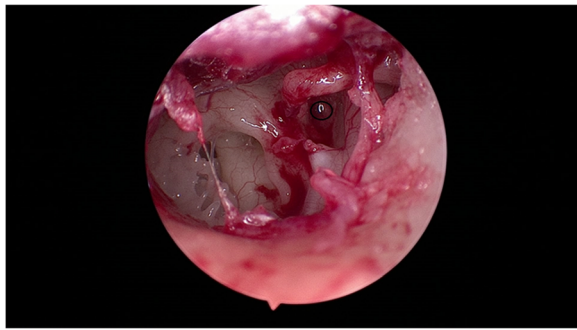


Fig. 3 Stapedotomy (fenestration) being performed at the center of the black circle

stapedotomy and prosthesis insertion is demonstrated in Figs. 1, 2, 3, and 4.

Summary of surgical steps and procedure-associated complications over the 5 years of the study and how they were managed are presented in Table 1.

Audiometric tests were performed at 45 to 60 days, 6 months, and 1 year, postoperatively, follow-up ranged from 6 to 30 months, with a mean of 18 ± 6 SD months. The overall mean preoperative hearing threshold (AC) was 43.1 ± 9.0 SD dB, while the overall mean postoperative hearing threshold was 24.8 ± 7.1 SD dB; hearing (AC) threshold gain was 18.3 ± 8.0 SD dB. Details of AC at different frequencies before and after stapedotomy are illustrated in Table 2.

Preoperative overall mean BC value was 21.5 ± 11.0 SD dB, and postoperative overall mean BC was 18.7 ± 7.2 SD dB; this difference was found to be statistically significant (p value <0.050). Carhart notch (dip in bone conduction at 4KHz) was seen in 44 ears out of 74 (59.4%) on preoperative audiological assessment, while after stapedotomy it disappeared in 35 ears (79.5% of Carhart positive ears).

The mean preoperative ABG in this study was 38.6 ± 9.8 SD dB, and the mean postoperative ABG was 15.3 ± 4.2 SD dB; this finding showed improvement of the ABG with ABG gain of 23.3 ± 7.2 SD dB. Details of ABG at different frequencies are presented in Table 2.

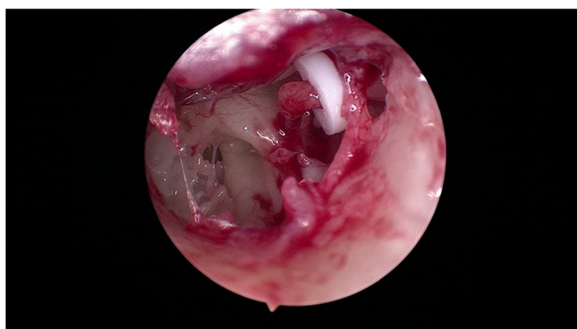


Fig. 4 Teflon prosthesis is inserted, loop around the long process of incus, and base of the shaft at stapedotomy site

Tinnitus was present in 65 patients out of 74 (87.8%); in postoperative assessment, 14 patients (21.5%) became free of tinnitus while 51 patients (78.5%) showed no improvement. Three patients (4%) had mild new postoperative tinnitus.

Three patients (4.05%) developed transient postoperative vertigo, which was successfully managed by cinnarizine in 2 patients. The third patient required revision surgery; details of this revision are included in Table 1.

Discussion

Analysis of the clinical and demographic data of the studied 91 patients of otosclerosis showed that it is consistent with the literature in the following: slight predominance of females, age at presentation (mean age 30.6 ± 7 SD years), and bilaterality of disease (90%). Dissimilar to many studies in high percentage of tinnitus (88%) and absence of family history in the majority, family history was reported in only two patients (2.8%) [5–7]. Although the sample size is small, we may hypothesize that the sporadic form of the disease is more prevalent than familial form, and a higher incidence of tinnitus is characteristic features of otosclerosis among our studied group of patients. A larger scale study is required to verify these two factors.

Endoscopic stapedotomy has a learning curve as the operative time and intraoperative complications became less with experience. Appreciated advantage of utilization of the endoscope is the changing scenes during instrumentation; the surgeon can change the view, magnification, and angles every fraction of a second while operating by moving the endoscope; the angled endoscopes provide clear views of middle ear structures and recesses.

Tear of tympanomeatal flap happened during the first year only, it is learned that avoidance of this complication is by adequate infiltration of the external auditory canal, keeping dissection close to the bone during elevation of the flap, use of a swab beneath the round knife, and elevation of the annulus from 6 o'clock at first where the bony rim is present up to 12 o'clock at the end against Notch of Rivinus. Adequate flap length is important to avoid short flap at the end of surgery, 5–7 mm lateral to the annulus gives sufficient length. Immediate repair of tympanomeatal flap was done by perichondrium; other options used when the defect was very small were fat lobule or vein graft.

Scutum removal should be tailored according to the anatomy of each patient; it should be removed to allow not only visualization of the oval window and stapes structures but to allow instrumentation as well. The surgeon must not be misled by the panoramic view provided by the endoscope, especially when using the angled one and under-remove that part of the scutum

Table 1 Surgical steps of endoscopic stapedotomy for 74 patients, complications, and associated interventions during the 5 years (2016–2020) of the study. *IS* incudostapedial joint, *1ry* primary, *ABG* air bone gap

Procedure/structure	Associated complication/finding	Incidence during the 5 years of the study	Management of complications and remarks
Tympanomeatal flap elevation: intact flap in 70 patients (94.6%)	Tear in 4 patients (5.4%)	1st year	Grafted by: perichondrium, fat, or vein graft
Scutum curette: performed for 65 patients (87.8%)	Inadequate in 3 patients (4.05%)	1st and 2nd years	Prolongation 11 min of surgery as re-curette was required
	Over removed in 1 patient (1.4%)	1st year	Shortened flap, supported by thin tragal cartilage
-Stapedius tendon -Separation of IS joint -Fracture of crura	None	-----	-----
Chorda tympani	Stretched in 1 patient (1.35%)	2nd year	Asymptomatic No reported taste disturbance
Fenestration of the oval window (stapedotomy)	Perilymph gush 1 patient (1.4)	3rd year	Leak stopped after placement of prosthesis
Prosthesis insertion: successful 1st trial insertion in 65 patients (87.8%)	Subluxation of incus in 1 patient (1.4%); several trials of insertion	1st year	Cessation of surgery, revised 6 months later with successful prosthesis insertion in second surgical session
Anesthesia: local in 71 patients (96%), general in 3 patients (4%)	Conversion from local to general in 1 patient (1.4%)	1st, 2nd, and 3rd years, 1/year	Two patients were scheduled for general anesthesia upon their request
Revision stapedotomy: one patient, 48 h after 1ry surgery	Displacement of prosthesis off incus and fenestra	3rd year	Severe cough and vertigo 10 h after 1ry surgery. Reposition of prosthesis ABG was closed after revision

required for instrumentation. However, over removal of the scutum will lead to shortened flap, and this is a potential for retraction pocket and cholesteatoma formation. Section of stapedius tendon, separation of incudostapedial joint, and fracture of the stapes were not associated with a complication.

Chorda tympani was stretched in one patient with no taste affection. Studies support that endoscopic stapedotomy preserves the chorda tympani more than microscopic stapedotomy [16]; absence of taste disturbance in the studied group of patients could be attributed to the relatively small sample size. The theoretical risk of thermal injury to middle ear structures and inner ear by the endoscope is managed by reducing the light power. Insertion of prosthesis is the most difficult part of endoscopic stapedotomy because it is done with a single hand and the

microscopic technique is superior in this step. Trials of insertion if were not done accurately will lead to the following: subluxation of the incus, this happened to one patient, or slip of the prosthesis into the vestibule with possible cochlear injury.

The advantages of local anesthesia are as follows: It allows communication with the patient during surgery, hence assessment of hearing improvement immediately; the other advantage is that the presence of significant vertigo following prosthesis insertion alerts the surgeon to the possibility of a longer prosthesis; this can be corrected immediately by adjusting the shaft's length. However, keeping the patient still is a real challenge when using local anesthesia; failure to ensure constancy makes general anesthesia an alternative. One patient has a gusher, this was not anticipated preoperatively as there was no history of vertigo; insertion of the prosthesis although was difficult due to profuse perilymph leak succeeded to reduce the leak dramatically. Gelfoam was placed at stapedotomy site after prosthesis insertion, where it was completely sealed and the gusher stopped; the patient was satisfied with hearing improvement and the postoperative PTA showed satisfactory air bone gap closure.

In the revision case, the prosthesis was off the fenestra, yet no sensory element was present in PTA which was purely CHL in the next day of surgery; this could be attributed to the use of vein graft which prevented significant perilymph leak and preserved the cochlea.

Table 2 Preoperative and postoperative air conduction (AC), air bone gap (ABG), and gains in dB, across different frequencies: 500, 1000, 2000, and 4000 Hz

Frequency in Hz	Preoperative		Postoperative		Gain in dB	
	AC	ABG	AC	ABG	AC	ABG
500	46.9	43.7	26.4	18.0	20.5	25.6
1000	46.1	39.5	24.5	14.2	21.6	29.3
2000	41.0	25.1	25.3	9.3	15.7	15.8
4000	41.1	33.0	28.2	13.2	12.9	19.8

Table 3 Mean air bone gap (ABG) gain after stapedotomy in different studies

Author	Country-year	Number of stapes surgeries studied and technique: microscopic or endoscopic	Average ABG gain in dB
Sarkar et al. [17]	India, 2013	32, endoscopic	31.4
Lin and Selesnick [18]	USA, 2016	79, microscopic	21.21
Alzharani et al. [19]	KSA, 2017	45, microscopic	17
Elzayat et al. [20]	Egypt, 2017	80, microscopic	23.48
Xie et al. [21]	China, 2019	28, microscopic	23.4
Current study	Sudan, 2021	74, endoscopic	23.3

Audiological assessment of endoscopic stapedotomy patients included ABG at different frequencies, the mean gain was 23.3 ± 7.2 SD dB, it reflects achievement of this surgical technique in hearing improvement, and the present ABG gain is comparable to other studies as summarized in the Table 3 [17–21].

Middle ear makes a contribution to bone conduction, and correction of a middle ear conductive lesion causes an apparent improvement in inner ear function [22]. In this study, closure of Carhart notch was achieved in the majority (79.5%). Although most of the operated ears were having CHL (preoperative mean BC was 21.5 dB) and very few of mixed hearing loss, BC gain after stapedotomy was statistically significant.

One patient (1.4%) developed profound sensorineural hearing loss (SNHL). Irreversible profound SNHL is the most disappointing complication of stapedotomy. Stapes surgeons should be aware that injury of the ultra-delicate inner ear structures with permanent sequelae can happen due to excessive mobilization of the stapes during foot plate fenestration, transmission of microdrill vibrations, displacement of prosthesis shaft into the vestibule, bleeding into the vestibule, and direct trauma to inner ear structures by instruments; this can lead to rupture of Reissner's membrane, which is composed of two layers separating the endolymphatic space from the perilymphatic space; a torn Reissner's membrane causes the cochlear action potential to drop drastically [23]. Modern stapes surgery is still evolving, and laser has become the tool of choice to create an opening in the footplate that is small enough to fit a piston prosthesis and reduce excessive mobilization of the stapes, hence reduce injury to the vestibule [14], avoidance of microdrill and clear surgical field are factors that should be considered to reduce the incidence of SNHL.

Factors that affect tinnitus improvement are preoperative AC, ABG, and postoperative AC [24]. In this study tinnitus improved in only 21.5% which is lower than reported by other studies [25]; this could be related to the higher percentage of preoperative tinnitus reported in our series; tinnitus being subjective needs careful

assessment before and after surgery; further detailed study is required to verify tinnitus.

Conclusions

Otosclerosis in the 91 studied patients affects females slightly more than males, mean age of presentation is 30.6 ± 7 SD years, all patients complained of hearing loss, it has a relatively high percentage of tinnitus (88%), and only 2.2% had vertigo. Family history was reported in 2.2%. CHL was reported in 81.3% ears and mixed type in 16.5% ears.

Endoscopic stapedotomy was performed for 74 patients; the procedure has a steep learning curve and was associated with few complications that were managed successfully, e.g., one gusher and one was revision. No taste disturbance was observed.

Hearing results were excellent as the mean ABG gain was 23.3 dB, AC gain was 18.3 dB, Carhart notch disappeared in 79.5%, and a statistically significant BC gain was reported.

Abbreviations

PTA: Pure tone audiogram; AC: Air conduction; BC: Bone conduction; ABG: Air bone gap; CHL: Conductive hearing loss; SNHL: Sensorineural hearing loss; SD: Standard deviation

Acknowledgements

Not applicable

Authors' contributions

NEA made substantial contribution in conception, design, analysis, interpretation of data, and drafting. TAN made substantial contribution in conception, design, analysis, interpretation of data, and revision of the manuscript draft. AFM made substantial contribution in conception, design, data acquisition, analysis, and interpretation of data. AAA made substantial contribution in conception, design, data acquisition, analysis, and interpretation of data. HIY made critical revision of the manuscript draft. AMA made substantial data interpretation and revision of the manuscript draft. The authors read and approved the final manuscript

Funding

The authors received no financial support for the research and/or authorship of this article.

Availability of data and materials

All data generated or analyzed during this study are included in this published article. Data sharing is not applicable to this article as no datasets were generated or analyzed during the current study.

Declarations

Ethics approval and consent to participate

Ethical clearance was obtained from the Research Committees of both ENT Khartoum Teaching Hospital and Aldoha Specialized ENT Hospital with no reference number being allocated for both. Patients are informed verbally about the study and signed an informed consent to participate in this study.

Consent for publication

Not applicable

Competing interests

The authors declare that they have no competing interests.

Author details

¹Department of Otorhinolaryngology H&N Surgery, Faculty of Medicine, University of Khartoum, P O Box102, Qasr Street, Khartoum, Sudan. ²ENT Khartoum Teaching Hospital, Qasr street, Khartoum, Sudan. ³Aldoha Specialised ENT Hospital, Mohamed Najeeb street, Khartoum, Sudan.

Received: 19 May 2021 Accepted: 2 July 2021

Published online: 03 August 2021

References

- Browning GG, Gatehouse S (1984) Sensorineural hearing loss in stapedial otosclerosis. *Ann Otol Rhinol Laryngol* 93(1):13–16. <https://doi.org/10.1177/000348948409300104>
- Ramsay HA, Linthicum FH Jr (1994) Mixed hearing loss in otosclerosis: indication for long-term follow-up. *Am J Otolaryngol* 15(4):536–539
- Declau F, van Spaendonck M, Timmermans J-P (2007) Prevalence of histologic otosclerosis: an unbiased temporal bone study in Caucasians. *Adv Otorhinolaryngol* 65:6–16. <https://doi.org/10.1159/000098663>
- Cureoglu S, Baylan MY, Paparella MM (2010) Cochlear otosclerosis. *Curr Opin Otolaryngol Head Neck Surg* 18(5):357–362. <https://doi.org/10.1097/MOO.0b013e32833d11d9>
- Skarzynski PH, Dziendziel B, Gos E et al (2019) Prevalence and severity of tinnitus in otosclerosis: preliminary findings from validated questionnaires. *J Int Adv Otol* 15(2):277–282. <https://doi.org/10.5152/iao.2019.5512>
- Menger DJ, Tange RA (2003) The aetiology of otosclerosis: a review of the literature. *Clin Otolaryngol Allied Sci* 28(2):112–120. <https://doi.org/10.1046/j.1365-2273.2003.00675.x>
- Souza JC, Bento RF, Pereira LV et al (2016) Evaluation of functional outcomes after stapes surgery in patients with clinical otosclerosis in a teaching institution. *Int Arch Otorhinolaryngol* 20:39–42
- Declau F, Van Spaendonck M, Timmermans JP et al (2001) Prevalence of otosclerosis in an unselected series of temporal bones. *Otol Neurotol* 22(5):596–602. <https://doi.org/10.1097/00129492-200109000-00006>
- Adv Otorhinolaryngol*. Basel, Karger (2011) Medical genetics in the clinical practice of ORL. In: Alford RL, Sutton VR (eds), vol 70, pp 1–9
- Batson L, Rizzolo D (2017) Otosclerosis: an update on diagnosis and treatment. *J Am Acad Physician Assist* 30(2):17–22. <https://doi.org/10.1097/01JAA.0000511784.21936.1b>
- Mosnier I, Bouccara D, Ambert-Dahan E, Ferrary E, Sterkers O (2007) Cochlear implantation and far-advanced otosclerosis. *Adv Otorhinolaryngol* 65:323–327. <https://doi.org/10.1159/000098854>
- Hancı D, Sözen T, Kayahan B et al (2014) Stapes surgery outcomes: the practice of 35 years. *Turk Arch Otolaryngol* 52(4):115–120. <https://doi.org/10.5152/tao.2014.516>
- Fisch U (1982) Stapedotomy versus stapedectomy. *Am J Otolaryngol* 4(2):112–117
- Nazarian R, McElveen JT Jr, Eshraghi AA (2018) History of otosclerosis and stapes surgery. *Otolaryngol Clin N Am* 51(2):275–290. <https://doi.org/10.1016/j.otc.2017.11.003>
- Tarabichi M (2010) Endoscopic transcanal middle ear surgery. *Indian J Otolaryngol Head Neck Surg* 62(1):6–24. <https://doi.org/10.1007/s12070-010-0007-7>
- Moneir W, Abd El-Fattah AM, Mahmoud E et al (2018) Endoscopic stapedotomy: merits and demerits. *J Otolaryngol* 13(3):97–100. <https://doi.org/10.1016/j.joto.2017.11.002>
- Sarkar S, Banerjee S, Chakravarty S, Singh R, Sikder B, Bera SP (2013) Endoscopic stapes surgery: our experience in thirty-two patients. *Clin Otolaryngol* 38(2):157–160. <https://doi.org/10.1111/coa.12051>
- Lin KF, Selesnick S (2016) Stapedotomy with adipose tissue seal: hearing outcomes, incidence of sensorineural hearing loss, and comparison to alternative techniques. *Otol Neurotol* 37(7):851–858. <https://doi.org/10.1097/MAO.0000000000001117>
- Alzhrani F, Baqays A, Almutawa H (2017) Stapes surgery using stapedotomy versus partial stapedectomy. *Otolaryngol (Sunnyvale)* 7(1):291
- Elzayat S, Younes A, Fouad A, Erfan F, Mahrous A (2017) Hearing outcome with the use of glass ionomer cement as an alternative to crimping in stapedotomy. *Otol Neurotol* 38(9):1240–1245. <https://doi.org/10.1097/MAO.0000000000001564>
- Xie J, Zhang LJ, Zeng N, Liu Y, Gong SS (2019) The clinical characteristics of otosclerosis and benefit from stapedotomy: our experience of 48 patients (58 ears). *Acta Otolaryngol* 139(10):843–848. <https://doi.org/10.1080/00016489.2019.1649459>
- Vijayendra H, Parikh B (2011) Bone conduction improvement after surgery for conductive hearing loss. *Indian J Otolaryngol Head Neck Surg* 63(3):201–204. <https://doi.org/10.1007/s12070-011-0130-0>
- Souza C, Glasscock M (2014) Otosclerosis and stapedectomy diagnosis, management, and complications. Thieme
- Sobrinho PG, Oliveira CA, Venosa AR (2004) Long-term follow-up of tinnitus in patients with otosclerosis after stapes surgery. *Int Tinnitus J* 10(2):197–201
- Cavalcante AMG, de Castro Silva IM, Neves BJ et al (2018) Degree of tinnitus improvement with stapes surgery – a review. *Braz J Otorhinolaryngol* 84(4):514–518. <https://doi.org/10.1016/j.bjorl.2017.12.005>

Publisher's Note

Springer Nature remains neutral with regard to jurisdictional claims in published maps and institutional affiliations.

Submit your manuscript to a SpringerOpen® journal and benefit from:

- Convenient online submission
- Rigorous peer review
- Open access: articles freely available online
- High visibility within the field
- Retaining the copyright to your article

Submit your next manuscript at ► [springeropen.com](https://www.springeropen.com)